

Carlo Mariotti
Editor

Ductal Carcinoma in Situ of the Breast

 Springer

Ductal Carcinoma in Situ of the Breast

Carlo Mariotti
Editor

Ductal Carcinoma in Situ of the Breast

 Springer

Editor
Carlo Mariotti
Department of Oncology and Robotic Surgery
Breast Surgery Unit
AOU Careggi
Firenze
Italy

ISBN 978-3-319-57450-9 ISBN 978-3-319-57451-6 (eBook)
<https://doi.org/10.1007/978-3-319-57451-6>

Library of Congress Control Number: 2017956913

© Springer International Publishing AG 2018

This work is subject to copyright. All rights are reserved by the Publisher, whether the whole or part of the material is concerned, specifically the rights of translation, reprinting, reuse of illustrations, recitation, broadcasting, reproduction on microfilms or in any other physical way, and transmission or information storage and retrieval, electronic adaptation, computer software, or by similar or dissimilar methodology now known or hereafter developed.

The use of general descriptive names, registered names, trademarks, service marks, etc. in this publication does not imply, even in the absence of a specific statement, that such names are exempt from the relevant protective laws and regulations and therefore free for general use.

The publisher, the authors and the editors are safe to assume that the advice and information in this book are believed to be true and accurate at the date of publication. Neither the publisher nor the authors or the editors give a warranty, express or implied, with respect to the material contained herein or for any errors or omissions that may have been made. The publisher remains neutral with regard to jurisdictional claims in published maps and institutional affiliations.

Printed on acid-free paper

This Springer imprint is published by Springer Nature
The registered company is Springer International Publishing AG
The registered company address is: Gewerbestrasse 11, 6330 Cham, Switzerland

Foreword

Ductal carcinoma in situ (DCIS) probably represents the neoplastic disease with the most significant increase in incidence in the last 30 years. The increased detection of DCIS has been made possible by screening mammography and the changed attitude of patients towards performing mammography in nonorganized screening programs as well. The detection of this type of cancer, which was anecdotal in the 1980s, now represents 20–25% of cases observed in a breast unit. DCIS is a heterogeneous disease, with an optimal prognosis, but a lot of unsolved questions regarding its evolution towards infiltrating carcinoma as well as surgical, radiotherapeutic, and oncological treatments still exist.

This volume, edited by Dr. Carlo Mariotti, a surgeon who has been dedicated to breast pathology for many years and who has spent most of this activity with women affected by breast carcinoma, is particularly interesting because it approaches this topic from a multidisciplinary point of view. As President of the Italian Society of Breast Surgeons (ANISC), I am very pleased to present this book to all our colleagues who are interested in breast pathology. All the chapters are written by professionals who are experts in the different subspecialties of this field. I am certain that this volume will meet the appreciation of colleagues dedicated to the treatment of breast cancer, while being also a useful tool for all medical doctors who would like to learn more about the diagnostic and therapeutic DCIS pathway.

Mario Taffurelli
Department of Medical and Surgical Sciences
University of Bologna
Bologna, Italy

Operative Unit for General Surgery
University Hospital Policlinic S.Orsola-Malpighi
Bologna, Italy

Contents

1	History of the DCIS of the Breast and the Evolution of Knowledge Based on Ductal Tree Anatomy	1
	Alfonso M. Pluchinotta	
2	Epidemiology and Risk Factors	23
	Paolo Luffarelli, Elena Manna, and Lucio Fortunato	
3	DCIS Imaging	39
	Gian Marco Giuseppetti, Francesca Boria, and Silvia Baldassarre	
4	Interventional Diagnostic in DCIS	57
	Carlo Mariotti, Eugenia Raffaeli, Enrico Lenti, Marco Gentili, Silvia Baldassarre, and Gian Marco Giuseppetti	
5	DCIS: Pathology and Biological Features	75
	Isabella Castellano, Jasna Metović, Riccardo Bussone, and Gretha Grilz	
6	Non-palpable Lesions Localization in DCIS	91
	Christian Rizzetto, Luca Seriau, and Paolo Burelli	
7	The Surgical Treatment of DCIS: from Local Excision to Conservative Breast Surgery and Conservative Mastectomies	107
	Carlo Mariotti and Eugenia Raffaeli	
8	Surgical Treatment of DCIS: Breast Reconstruction	143
	Carla Cedolini, Serena Bertozzi, Ambrogio Pietro Londero, and Pier Camillo Parodi	
9	Sentinel Node Biopsy in Ductal Carcinoma In Situ of the Breast	157
	Matteo Ghilli and Manuela Roncella	
10	Breast Irradiation in DCIS	171
	Francesca Cucciarelli	
11	Adjuvant Systemic Therapy in DCIS	185
	Mirco Pistelli and Rossana Berardi	

12 DCIS: The Problem of Recurrence	193
Federico Buggi, Annalisa Curcio, Matteo Mingozzi, Daniele Vecchio, Francesco Marongiu, Dario Lelli, and Secondo Folli	
13 Counseling a Woman with DCIS.	203
Alfonso M. Pluchinotta and Xenia Raspanti	
Index.	211

Contributors

Silvia Baldassarre Department of Diagnostic Radiology, AOU Ospedali Riuniti di Ancona, Politecnica delle Marche University, Ancona, Italy

Rossana Berardi Medical Oncology Unit, Azienda Ospedaliero-Universitaria Ospedali Riuniti, Ancona, Italy

Serena Bertozzi Breast Unit, University Hospital of Udine, Udine (UD), Italy

Francesca Boria Department of Diagnostic Radiology, AOU Ospedali Riuniti di Ancona, Politecnica delle Marche University, Ancona, Italy

Federico Buggi U.O.C. Senologia, Ospedale Morgagni-Pierantoni, Forlì, Italy

Paolo Burelli, M.D. Breast Unit, “Ca’ Foncello” Hospital, Treviso, Italy

Riccardo Bussone Ospedale Cottolengo, Surgical Section, Turin, Italy

Isabella Castellano Department of Medical Sciences, University of Turin, Turin, Italy

Carla Cedolini Breast Unit, University Hospital of Udine, Udine (UD), Italy

Clinic of Surgery, University Hospital of Udine, Udine (UD), Italy

Francesca Cucciarelli Radiotherapy, Ospedali Riuniti—Ancona, Ancona, Italy

Annalisa Curcio U.O.C. Senologia, Ospedale Morgagni-Pierantoni, Forlì, Italy

Giulia Dell’Oste Department of Radiology, Mammographic Screening, Padova, Italy

Secondo Folli S.C. Chirurgia Senologica, Istituto Nazionale Tumori, Milan, Italy

Lucio Fortunato, M.D. Breast Unit, A.O. San Giovanni-Addolorata, Roma, Italy

Marco Gentili Department of Surgery, Breast Surgery Unit, Ospedali Riuniti University Hospital, Ancona, Italy

Matteo Ghilli Breast Cancer Center, University Hospital of Pisa, Pisa, Italy

Gian Marco Giuseppetti Professor of Radiology, Chairman of Department S.C.O., Politecnica delle Marche University, Ancona, Italy

Greta Grilz Ospedale Cottolengo, Surgical Section, Turin, Italy

Ambrogio Pietro Londero Unit of Obstetrics and Gynecology, Hospital of Monfalcone, Monfalcone (GO), Italy

Dario Lelli U.O.C. Senologia, Ospedale Morgagni-Pierantoni, Forlì, Italy

Enrico Lenti Department of Surgery, Breast Surgery Unit, Ospedali Riuniti University Hospital, Ancona, Italy

Paolo Luffarelli, M.D. Breast Unit, A.O. San Giovanni-Addolorata, Roma, Italy

Elena Manna, M.D. Breast Unit, A.O. San Giovanni-Addolorata, Roma, Italy

Carlo Mariotti Department of Oncology and Robotic Surgery, Breast Surgery Unit, AOU Careggi, Firenze, Italy

Francesco Marongiu U.O.C. Senologia, Ospedale Morgagni-Pierantoni, Forlì, Italy

Matteo Mingozi U.O.C. Senologia, Ospedale Morgagni-Pierantoni, Forlì, Italy

Pier Camillo Parodi Clinic of Plastic and Reconstructive Surgery, University Hospital of Udine, Udine (UD), Italy

Department of Medical Area (DAME), University Hospital of Udine Udine (UD), Italy

Mirco Pistelli Medical Oncology Unit, Università Politecnica delle Marche—Azienda Ospedaliero-Universitaria Ospedali Riuniti Umberto I—GM Lancisi—G Salesi di Ancona, Ancona, Italy

Alfonso M. Pluchinotta Breast Surgery, Policlinic of Abano Terme, Padova, Italy

Eugenia Raffaelli Department of Oncology and Robotic Surgery, Breast Surgery Unit, AOU Careggi, Firenze, Italy

Christian Rizzetto Breast Unit, “Ca’ Foncello” Hospital, Treviso, Italy

Manuela Roncella Breast Cancer Center, University Hospital of Pisa, Pisa, Italy

Luca Seriau Breast Unit, “Ca’ Foncello” Hospital, Treviso, Italy

Daniele Vecchio U.O.C. Senologia, Ospedale Morgagni-Pierantoni, Forlì, Italy

History of the DCIS of the Breast and the Evolution of Knowledge Based on Ductal Tree Anatomy

1

Alfonso M. Pluchinotta

1.1 Foreword: The Need for a Conceptual Map

Clinical Practice Points

- DCIS is an elusive and misleading disease, mostly because its natural history is poorly understood.
- The entire process progresses over time under endogenous and exogenous influences, not like a photo, but like *a lifelong movie*.
- Actually we have a rough outline of *space* where the changes arise and know almost nothing about *times* which are likely to occur.
- Some *so-called* unexpected events are more likely *underestimated*.
- New theories of sick lobe and biological time place different patterns of disease into a unifying concept with genetic and developmental perspectives of understanding.

Is DCIS really an elusive disease? The great pathologist David Page, in one of his most popular papers [1], referring to DCIS claims that *understanding the misunderstood stepchild has lagged behind our understanding of other elements of breast cancer*.

There are many reasons to consider DCIS an elusive and misleading disease that leaves far behind our understanding. The first is unpredictability. A high level of unpredictability, with many seemingly unexpected events, is attributable to its different presentations and to the fact its natural history is poorly understood as it cannot be observed directly. Unexpected events give reason of considerable controversy regarding optimal management; however, it is time to say some *so-called* unexpected events are more likely *underestimated*. So we need to have a good road map for an overall view on spaces and times of process of carcinogenesis.

A.M. Pluchinotta
Breast Surgery, Policlinic of Abano Terme, Padova, Italy
e-mail: pluchinotta.alfonso@gmail.com

Are our coordinates updated? Since DCIS is a local disease, an up-to-date map is crucial, since much still remains unclear. Even if oncology has the task of winning the war, notably in DCIS, it is up to surgery to win the battle. Like in a battlefield, there is a need to go further, and this can be accomplished only having the right map.

Actually, landscape offered by microscopic anatomy is no longer enough. Concentrating on events in a few cubic millimetres of tissue is not sufficient. Detecting BC at an earlier phase in its development and at a smaller tumour size is no guarantee that the disease will be localised to a small, confined volume in every case. We have to have a map of the subgross anatomy, where lobes, segments and subsegments are truly showed as distributed and connected to each other. It is also necessary to give up some oleographic descriptions of well-defined quadrants and segments of accustomed volume, for the most part triangular and arranged in a radial manner as the slices of a cake or the hours on a clock face.

Can we still talk of steady growth of cancer? It is recognised that time of development of the disease is inconstant, and more strains of the diseases may develop in an asynchronous rather than synchronous manner. Furthermore, it is becoming increasingly obvious that endogenous and exogenous influences, as those due to stroma, hormonal milieu and nutritional habits, make a difference.

1.1.1 The Space

First and foremost, we must consider three neglected aspects, which deserve closer attention specifically with regard to DCIS: a 3D anatomy partitioned into lobes, a very varied anatomy and a better understanding on influence of stromal environment. It could be said outcome of invasive BC is more reliant on intrinsic biological factors, while in DCIS anatomical and extrinsic factors could play a major role.

Underestimation of 3D anatomy may be inferred from a set of indicators arising from the daily circumstances. In the *diagnostic assessment*, combining 3D mammography (tomosynthesis) led to a 40% increase in detection of invasive breast cancers and a 15% decrease in false-positive results [2]. *Classical microscopy* is, by its nature, rather limited because only a tiny portion of a breast tissue can be easily embedded in a single block of paraffin wax for histology. Giant histological sections do address this problem, with advantages recognised by breast pathologists, but their use is routine only in a few dedicated laboratories. It can be said that in certain situations, the *surgical results* are disappointing probably for a prevailing geometric perspective built on the two-dimensional pictures of mammography.

Underestimation of large-scale anatomy is due to the fact we mostly tend to focus on separate patches of ducts without properly considering their extension within the whole lobe. Indeed, a greater role should be granted to the natural structure of the lobe. Anatomist and pioneer senologist Sir Astley Cooper stated that it is absolutely necessary to give an account of whole lobe unit “before its morbid changes could be properly explained or understood” [3]. This neglected assertion should be reassessed today, given that morphological evidence exists that the

components of the cancer and precancerous changes occupy a lobe-like space in the breast. Only “a more widespread use of large sections in routine pathology will give more accurate knowledge on extent and growth patterns of breast in situ neoplasms” [4]. Chief among its limitations is the fact that the extension of a lobe may be extremely variable and only few sophisticated examinations, as ductal endoscopy or ductal echography, may provide more morphological evidence.

Underestimation of stromal environment. Together with the breast parenchyma, also stromal environment remains the theatre of the cellular and molecular changes of normal mammary development and breast disease during infancy, adulthood and old age. DCIS is defined as a proliferation of neoplastic epithelial cells within the closed environment of the duct, but the outside perimeter of the basement membrane interfaces with the connective tissue stroma, immune cells, lymphatics and vasculature (extracellular matrix or ECM).

There are both clinical and experimental evidences to suggest that a nonmeasurable proportion of DCIS is a precursor lesion to most, if not all, invasive BC. Lesion size, degree of nuclear atypia and the presence of comedo necrosis are main histopathological parameters that have been identified as affecting the risk of invasiveness, but also all components of ECM may participate in the carcinogenic process. Soluble nutritional and/or carcinogenic factors secreted by reactive or activated stromal cells and mesenchymal cells or immune cells may have a great influence in promoting or suppressing malignant progenitor cells that could arise within the mass of cells accumulating in the duct.

Underestimation of the area of genetically abnormal tissue. According to the sick lobe theory (see Sect. 1.3.2), an area several centimetres in size of genetically altered tissue may exist in the breast, and BC develops within this area rather than at one single point. This well-defined anatomic structure, a breast lobe, may contain more or more sensitive malignant (or committed) progenitor cells and is more sensitive to endogenous or exogenous oncogenic stimuli (see Sect. 1.3.2), providing a possible explanation for the progressive character and morphological heterogeneity of BC.

1.1.2 The Time

Time sensitivity. Knowledge of time sensitivity may broaden our limited horizons about natural history of BC. Until now time sensitivity is based on limited number of parameters, as volume changeover and nodal status, but ongoing researches could extend this model to include, for example, a proper explanation of biological markers.

Estimate of biological time is commonly related with the *circadian rhythm disruption* or with the *sojourn time*, but in the questionable manner. The former is based in the potential relation of transcriptional expression of a wide range of clock-controlled genes that regulate a variety of normal cell functions, such as cell division and proliferation. Its practical application is still limited to preventive measures and restricted to use of protective factors (i.e. melatonin). The *sojourn time*, namely,

is the time spent in the preclinical detectable phase for BC. Its estimate works as a clinical application and is usually estimated assuming a uniform incidence rate of preclinical disease from a randomised control group or historical data.

Actually biological time should be considered the time of complete malignant transformation of the malignant (or committed) progenitor cells, determined by the number of required additional genetic alterations, which are mostly acquired during the division of these cells (see Sect. 1.2.1).

Carcinogenesis may appear in a single locus, at more than one locus at the same time, or with a considerable time difference or at a large number of loci leading to a unifocal, multifocal or diffuse malignant process, respectively. Many evidences link theoretical assumptions of this process (*theory of biological timing*) to the *theory of sick lobe* (see Sect. 1.3.2). Both do not explain all aspects but stimulate to rethink the established views and to develop new and more efficient approaches in diagnosis and treatment. As Tibor Tot writes, “they put these patterns into a unifying concept with genetic, developmental, and morphological perspectives of understanding breast carcinoma as a process that develops over time under endogenous and exogenous influences, not like a photo, but like a life-long movie” [5].

1.2 Natural History: Where Are We?

Clinical Practice Points

- The natural history of DCIS cannot be observed directly, but new randomised trials investigating active surveillance versus active management may shed light on this issue.
- Some evidences suggest DCIS is a precursor of most (it is questionable if all) invasive BC.
- Few DCIS remain dormant or perhaps could undergo regression along with ductal epithelium involution.
- Estimates of the proportion of DCIS that progress to invasive cancer, as well as factors that may influence progression, are important issues for clinical management.

1.2.1 A Factual Synopsis of the Carcinogenesis Process

As is known, cellular elements of the duct under normal conditions are *epithelial layer*, *myoepithelial cells*, *basement membrane* and *stromal cells of the extracellular matrix (ECM)*. Usual appearances of cell in normal duct and atypical hyperplasia are shown in Fig. 1.1.

DCIS lesion contains multiple layers of cells that accumulate inwards into the lumen resulting in a stressful microenvironment, which may promote genetic instability. Cellular elements taking part in the carcinogenesis process are *progenitor cells* and *malignant progenitor cells* (also called *committed progenitor cells*).

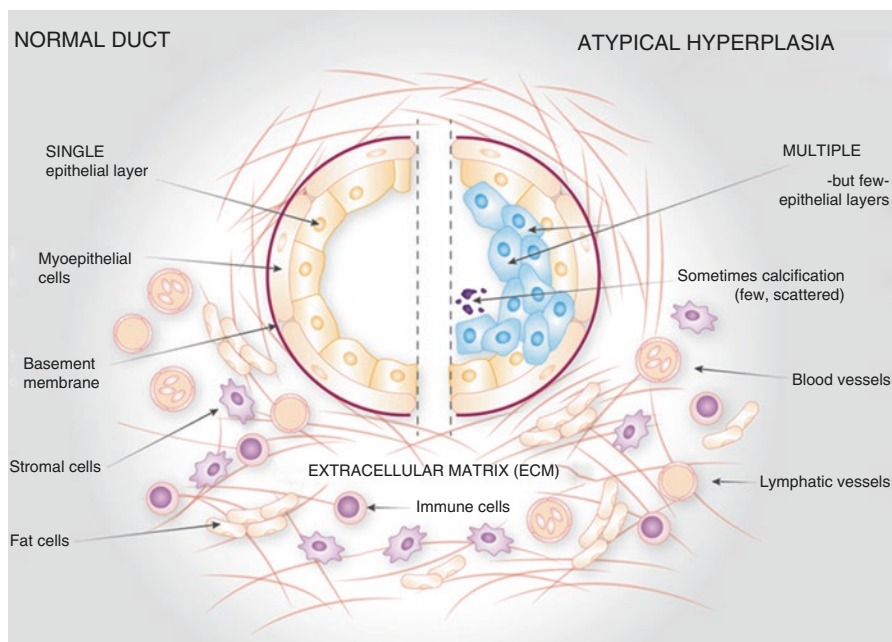


Fig. 1.1 Schematic sections of breast duct in normal condition and in atypical hyperplasia. The normal duct (on the *left*) is composed of a single epithelial layer within the duct, which is bound by the basement membrane and a rim of myoepithelial cells on the lumen side of the basement membrane. Outside the basement membrane, the breast stroma contains the extracellular matrix (ECM): blood and lymphatic vessels, stromal cells, immune cells and fat cells. In the atypical hyperplasia (on the *right*), an overgrowth of normal cells is observed which over time continue accumulating and develop abnormalities [6] mod

Progenitor cells, like stem cells, have a tendency to differentiate into a specific type of cell, but are already more specific than a stem cell and are pushed to differentiate into its “target” cell. The most important difference between stem cells and progenitor cells is that stem cells are multipotent and can replicate indefinitely, whereas progenitor cells are uni- or oligo-potent and can divide only a limited number of times. Controversy about the exact definition remains and the concept is still evolving. In the normal duct progenitor cells:

- Maintain the ductal-lobular architecture of the breast parenchyma.
- Sustain the myoepithelial cell layer and basement membrane surrounding the parenchyma.
- Balance the relationship of the parenchyma to the stroma.

Malignant (or committed) progenitor cells undergo complete malignant transformation. They replace the progenitor cells, take over and only in part retain their functions.

At the highest level of retained functions (*low-grade DCIS*), the malignant progenitors are able to maintain almost all of these functions and are able to renew the ductal and lobular structures.

At the lowest level of retained functions (*high-grade DCIS*), depending on the severity of the genetic alterations acquired, malignant progenitors may not be able to preserve the terminal units. Under their action:

- New duct-like structures appear in close proximity to each other (ductal neogenesis).
- Myoepithelium is formed in a defective way and focally disappears.
- Periductal stroma undergoes remodelling and becomes infiltrated by lymphocytes.

The stressful microenvironment of the intraductal lumen may promote genetic instability. All of the components of extracellular matrix (ECM) participate in the carcinogenic process by promoting or suppressing malignant progenitor cells that could arise within the mass of cells accumulating in the duct (Fig. 1.2).

Pluripotent malignant progenitor (stem) cells must adapt to survive for some time. However, in a later stage, process promotes the suppression of apoptosis in the face of genetic instability and could lead to the generation of genetically abnormal malignant progenitor cells before the onset of invasion. Invasion is associated with the loss of myoepithelial cells, periductal angiogenesis, fragmentation of the

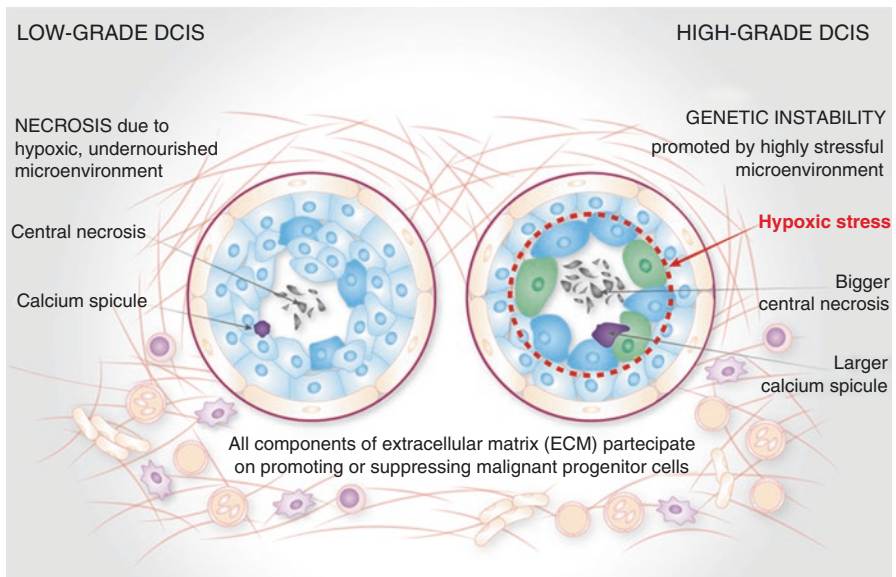


Fig. 1.2 Some schematic features of process of intraductal cell proliferation at the highest level of retained functions (*low-grade DCIS*, on the left) and at the lowest level of retained functions (*high-grade DCIS*, on the right) [6] mod

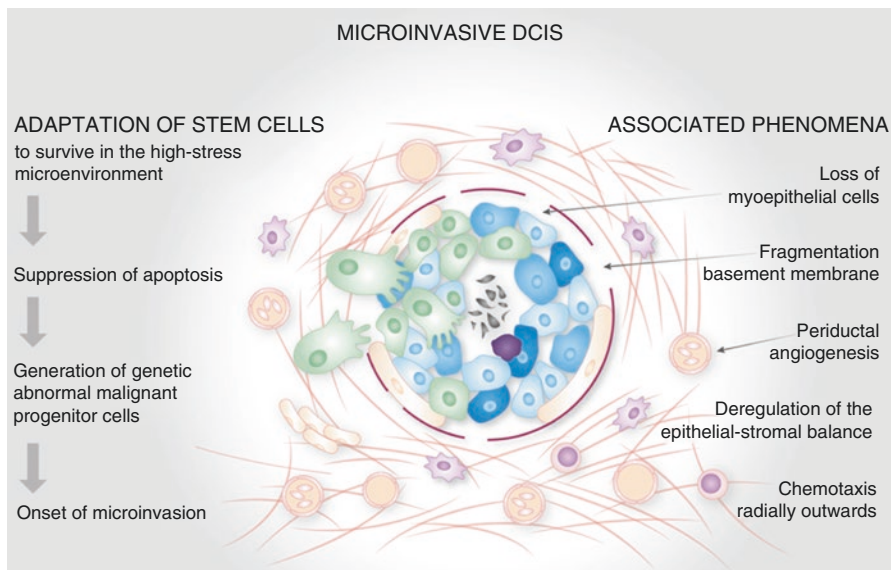


Fig. 1.3 Initial adaptation and subsequent evolution of stem cells with their associate phenomena. [6] mod

basement membrane and chemotaxis radially outwards (Fig. 1.3). Incidentally, understanding how genetically abnormal DCIS cells arise and survive within the high-stress microenvironment may provide targets for chemoprevention.

1.2.2 Outcome of DCIS Lesions

DCIS become invasive in an unknown proportion of cases, in different ways and at various times. Three hypothetical models for the possible outcomes of a DCIS lesion [2] are outlined in Fig. 1.4.

DCIS with prolonged intraductal phase. Tumour malignant cells spread along duct invasion with a persistent but slow phase, which may include a dormant phase with little cellular proliferation, which could last many years or decades. Possible specific factors are mutation or altered expression in critical gene, but also a simple basement membrane degradation. This last factor may be influenced by stromal signalling, hormonal milieu, age or other unknown environmental and dietary factors that may precipitate invasion of the basement membrane. Unlike what can be supposed, in this phase DCIS may be both low grade/ER positive and high grade/ER negative.

DCIS with short intraductal phase. DCIS arises within the ductal epithelial cells and may, in an unknown proportion of cases, rapidly become invasive after a short DCIS phase. The first possible factor is early critical mutation during the initiation phase of the tumour. Compared to BRCA2, BRCA1 tumours are more rarely

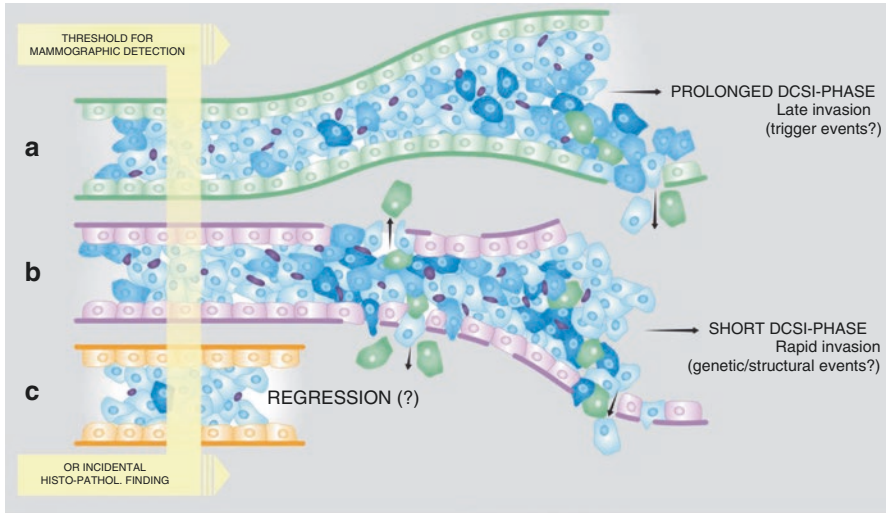


Fig. 1.4 Roughly schematic models for the different outcomes of a DCIS lesion. *A:* DCIS with prolonged intraductal phase. *B:* DCIS with short intraductal phase. *C:* Regressive or not evolving DCIS [2] mod

associated with extensive intraductal neoplasia and may be an example of this type of progression. Other possible factors might be stromal factors, defect of basement membrane and/or the hormonal triggers at time of tumour formation. Usually DCIS are high grade with necrosis and ER negative.

Regressive DCIS. It is also possible, only theoretically and without any direct evidence, that DCIS undergoes regression in some cases. Regressive **DCIS**, or otherwise not evolving DCIS, usually low grade, are occasionally found in re-examination of histological samples. It remains unknown if DCIS remains dormant or could it undergo regression along with ductal epithelium following post-lactational settlement and postmenopausal involution.

Post-lactational settlement has been well described, but there is no description of the reconstitution of the ductal system for the next child. Is the pattern the same developed from residual stem cells lining a path through the stroma? Or completely different generated from rudimentary ducts behind the nipple? This remains to be explored.

As regards postmenopausal involution, in a latest study carried out among women with multiple biopsies, a significant association of higher BC risk among those with involution stasis, as compared with those with involution progression, has been observed [7].

1.2.3 What We Know About Natural History

Since the current standard of care of DCIS is surgical removal of the lesion, the natural history of DCIS is poorly understood because it cannot be directly observed. It is still disputable whether DCIS is an obligate precursor of invasive

BC and, even if non-obligate, what proportion of in situ breast lesions progress to invasive cancer. Yet, an estimation of the proportion of DCIS that may not progress to invasive cancer and factors that can predict progression is therefore of clinical importance.

Available evidences, which strongly suggest DCIS is a precursor of most invasive BC, are:

- Some invasive cancers have an adjacent DCIS component, and molecular studies show marked similarity in the genetic profile of the two components supporting origin of invasive cancer from DCIS.
- Invasive cancers occurring in the excision site of a previous DCIS lesion show similarities to the primary DCIS suggesting that they have arisen from residual DCIS.
- Molecular studies show the presence of shared identical genetic abnormalities between genetic changes in DCIS lesions and in recurrent lesions. These strong similarities are proved also in synchronous invasive BC when present, giving a further demonstration of a clonal relationship.
- Epidemiological risk factors are also largely similar between DCIS and invasive BC.

Evidences also suggest not all DCIS will progress to invasive cancer in the medium term, but precise estimates of progression are not possible given the limitations of the data. It is unknown whether all BCs through a prolonged, potentially detectable intraductal phase or whether some of them rapidly invade surrounding stroma.

Actually there are several sources of evidence that shed light on the natural history of DCIS; however, none can provide a definitive answer on the proportion of DCIS that will progress to invasive cancer. The main studies are related to misdiagnosed DCIS, invasive recurrence and autopsy series.

DCIS initially misdiagnosed as benign and treated by biopsy alone. Studies give the most direct evidence regarding the progression of DCIS to invasive BC. These studies suggest that between 14 and 53% of DCIS may progress to invasive cancer over a period of 10 or more years [2].

Recurrence of DCIS as invasive cancer. Long-term series show that up to 40% of women treated with breast-conserving surgery will develop recurrent disease in the ipsilateral breast and about half of these recurrences will be as invasive cancer. The risk of recurrence has been shown to depend on patient characteristics such as history of breast cancer in a first degree, relative younger age at diagnosis and tumour factors such as histology, presence of necrosis, nuclear grade, size and architectural patterns.

Diagnosis of DCIS in autopsy studies. The reported incidence of DCIS has been used to suggest a larger reservoir of DCIS may exist in the population. Curiously, but conceivably, a highest reported autopsy studies on women who had not been diagnosed with breast cancer during their lifetime vary by study design, with a highest number of DCIS found in forensic rather than hospital autopsy.

Table 1.1 Summary of evidences on natural history of DCIS

Type of evidence	Conclusions	Limitations
DCIS initially misdiagnosed as benign lesion	Studies suggest 14–53% may progress to invasive cancer over 10–15 years	Higher-grade lesions less likely to have been misdiagnosed. Follow-up likely to be more complete for women subsequently diagnosed with cancer
Recurrence of DCIS as invasive cancer	Overall recurrence rate is founded between 1.45 and 22.5% of cases, about half of these showing an invasive BC	Recurrence is strongly dependent on excision margins and moreover may not reflect situation in absence of surgery
Autopsy studies	Large reservoir of undetected DCIS in the population, thus not all DCIS progress to invasive cancer	Modelling predicts such a reservoir would be expected due to differing growth rates of tumours
Mathematical models	Large reservoir of DCIS relative to invasive cancer predicted even if all DCIS progress	Broad assumptions and models lack complexity
Epidemiology	Risk factors similar between DCIS and invasive cancer	Does not give estimate of progression rates, only that DCIS is likely to be a precursor for invasive cancer
Animal models	Some useful models for studying genetic alterations associated with progression	Genetic background and hormonal milieu differ between models and applicability to humans questionable

Other evidences come from mathematical and animal models, as well as from epidemiology. Among these, mathematical models are promising, even if limited by broad assumptions and lack of complexity. However, modelling of various scenarios of progression, together with studies of genetic factors involved in progression, may shed further light on the natural history of DCIS. A summary of evidences on natural history of DCIS is presented in Table 1.1 [2].

All of these studies are materially affected by:

- Inadequate data on age-specific recurrence incidence, as it is possible that the proportion of DCIS that progresses to invasive BC may differ by age
- Unpredictability of progression for low-grade DCIS, when the boundaries between benign or proliferative lesions, with or without atypia, and DCIS are very weak (see also Sect. 1.4)

Since the natural history of DCIS remains unobservable, it is essential that new methods are developed to estimate the progression of DCIS to invasive cancer. Mathematical models may provide important insights into growth and progression of DCIS. Identification of crucial molecular changes associated with progression of DCIS in animal models or in recurrent DCIS following surgery gives important incomes to identify what DCIS lesions are likely to progress or remain clinically benign on the basis of the presence of such key genetic alterations.

As DCIS progression to invasive BNC may never occur or take decades in some cases, the concern regarding the potential for overdiagnosis and overtreatment has fostered recently novel randomised trials investigating active surveillance versus active management. Together with multigene expression assays on vacuum biopsy, it seems possible to stratify patients at increased risk for progression to invasive BC even in the absence of surgery.

1.3 Space: A Revisited Anatomy

Clinical Practice Points

- While knowledge of the microscopic anatomy of the mammary ducts is well established, less account is taken of its large-scale anatomy.
- Subgross anatomy should refer to new anatomical models, which partly confirm results of past Cooper's achievements.
- There is noticeable variation in the extent of different lobes, and it could be assumed that some lobes develop earlier and larger than other ones.
- To some degree the branches of lobes intertwine with each other, mainly in periphery but also in central part.
- The boundary between multifocal and multicentric cancers may be elusive, as demonstrated by potential skips observed with ductal endoscopy and ductal echography.

1.3.1 Understanding the Misunderstood Subgross Anatomy

Since the 1970s, starting from the studies of Wellings and others [8], it has been widely accepted that all breast cancer begins at the junction of the duct and lobule or the terminal ductal-lobular unit (TDLU). For this reason many believe BC is multifocal and/or multicentric in origin and could not begin in a ductal tree.

As regards multicentricity, the presence of more foci varies considerably depending on the criteria adopted, leading to not a little confusion and inappropriate adjudications. Nevertheless, at much the same time, researchers who have used techniques of whole breast sectioning have concluded that the in situ component is most often located in a single ductal tree or lobe.

In the 1990s, Tibor Tot, on whole-mount specimens, has hypothesised that DCIS and consequently BC in general are lobar diseases with simultaneous or asynchronous and often multiple in situ tumour foci localised within a single lobe.

As a result of these studies, the great importance of subgross anatomy behind multifocality became clear. New studies were launched and almost all had come to the same conclusions made by the first great anatomist Sir Astley Paston Cooper. In dealing with the *anatomy of ducts and glandules*, Cooper [3] puts together three

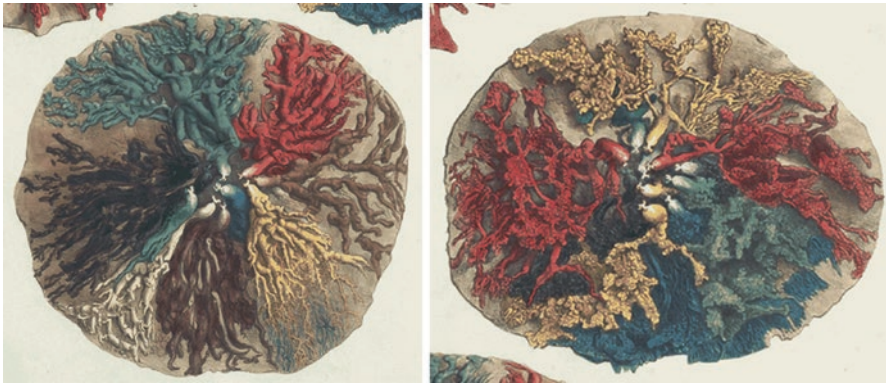

Fig. 1.5 Anatomy of ducts and glandule, in Plate VI of Cooper’s text [3]. In the plate there are three images displaying, as Cooper’s caption read, “Lactiferous tubes or ducts injected with (coloured) wax, showing their radiated direction, and, in some places, their inter-ramification”. In the first image, not shown here, the main and segmental ducts having a rather regular course in the radial direction are showed. In the second (*left*), injected subsegmental ducts are intermixed and there are some discrepancies of volume of the lobes. In the third (*right*), “Ducts (are) injected more minutely (...) at the lower part of the preparation the separate ducts are seen passing above and beneath each other, to render the breast a cushion; whilst at the upper part the ducts are single”

illustrations of the individual lobes (Fig. 1.5), injected separately with different coloured waxes. In the first anatomical preparation, main ducts show their radiated direction, maintained also in the next preparation. In the last preparation, in which also appears the glandular component, the whole structure appears much more convoluted and indefinite.

In these illustrations, and in others of Cooper’s work, the most noticeable features are:

- There is a significant biological variation among mammary gland lobes, and their individual extent is different.
- To some degree lobes’ branches intertwine, but not to the extent that their distributions overlap greatly.
- The ducts are variable in calibre, radiating from the centre, branching and rebranching, with the last branches terminating in glandular parenchyma.
- The mammary ducts do not communicate with each other, as is easily shown by throwing injections of different colours into the ducts or by injecting one duct only.
- The glandular tissue is present in all parts of the breast, not just the periphery, although in the nipple itself lobules are supposed to be sparse.

It is important to note, however, that many following published illustrations of lobe anatomy in human breast have applied mainly Cooper’s plate in which breast segmentation into lobes is more uniform and attractive, albeit with less evidential value. This may reflect an aesthetic bias in favour of uniformity, which may account

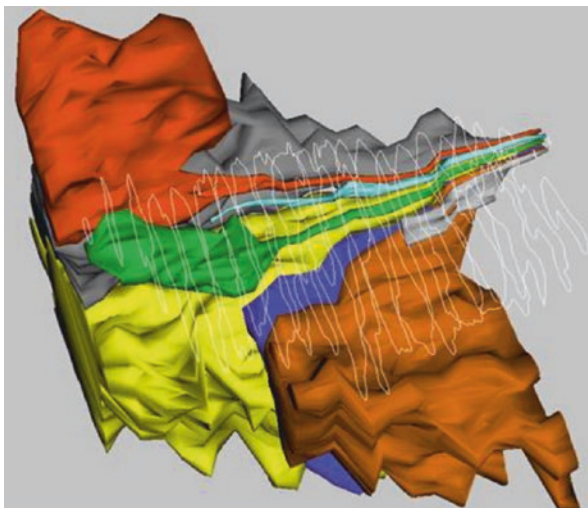


Fig. 1.6 Seven representative lobes of a single breast. Each duct system was traced through serial subgross sections. In each slice, the area occupied by branches of any one duct system may have complex borders, but can be drawn around. Tetrahedral surfaces, constructed with Boissonnat’s technique, are shown for six lobes; the seventh by wire-frame outlines, so as not to obscure the central part of the model behind this lobe. Obvious lobe-to-lobe differences include size, early branching close to the nipple and the breast surface (tan) versus late branching in the depths of the breast (*orange, green*) or none at all (*sky blue*). The last is a vestigial lobe in the form of a duct with no peripheral branching at all [9]

for the other “artistic” representations of mammary lobes, which emphasise a regularity of development and arrangement not supported by any primary source.

A great variation in mammary lobe morphology has been observed also in some recent models of anatomical reconstruction. In one representative model of Going [9] (Fig. 1.6), seven representative lobes of a single breast are visualised, which vary greatly in size and distribution. The same researcher describes a breast where three lobes occupied one half of the breast.

Another question is how many individual lobes (or ductal systems) there actually are and which is their distribution in a breast. Reports depending on whether the study focused on openings on the nipple that can be cannulated or the number of duct profiles seen on cross-sections of the nipple. The former method acknowledges 5–9 openings on the nipple and the latter identifies 15–20 duct-like structures. One explanation for this discrepant observation of 5–9 vs. 15–20 ducts may be due to the additional tubular structures that mimic the appearance of ducts behind the nipple. These structures, which do not contribute significantly to the ductal-lobular infrastructure of the breast, include ductal branching close to the nipple surface, rudimentary undeveloped ducts or even ducts with associated sebaceous glands.

Collectively however, these data suggest that there are 5–12 significant, independent, arborizing lactiferous ductal systems, each of which covers a finite portion of the breast geography and is accessible from the nipple. Galactograms, ductal

Table 1.2 Anatomical features and their related clinical implementations

Anatomical features	Related clinical implementations
Dimensions of the breast lobes vary noticeably within the same breast, as well as individually	Subdivision of breast in quadrants or triangular segments is barely practical for description even if to some degree illogical for treatments
The largest lobe may include up to 25% of the breast volume, while the smallest only 1% [9]	Apparently multicentric foci may belong to the same lobe
Lobes are larger in the upper outer quadrant and smaller in the medial quadrants [9]	Actually the upper outer quadrants are those most commonly involved by diseases
The dimensions of the lobes are age related: larger in younger women and more involute after menopause	This may explain why young age is strongly correlated with a high risk of local recurrence after BCT
Lobes in the medial quadrants of the breast develop later and undergo involution earlier than the lobes in the lateral quadrants [10]	In diagnostic assessment lesions in medial quadrants are more effectively detected when small sized

endoscopy and new studies of large-scale ductal echography confirmed the same results on the number of lobes as well as their variable distribution. Once again, visualisation of even only a lobe, as observed in galactograms where a single duct is cannulated, may account for a significant fraction of breast volume.

Shape and volume disparity are two morphological aspects that have been underestimated over time, while, as Cooper's pictures first highlighted, they are of practical importance both from a surgical and pathological viewpoints. Related clinical implications are summarised in Table 1.2.

1.3.2 The Sick Lobe Theory (SLT)

Researchers who have explored the clonality of mammary epithelium and early proliferative lesions without regard to the underlying anatomy have demonstrated some degree of loss of heterozygosity, with contiguous patches of normal appearing mammary epithelium. Finding that a tumour has single inactivated X chromosomes indicates that the initial events leading to the tumour occurred at some time in development, after X chromosome inactivation and before maturity of the breast.

Initiating genetic abnormalities of some epithelial cells, all containing the same inactive X chromosome, may have an independent evolution into a tumour after the initiating events. For example, looking at the radiation as initiating event, the potential of pre-differentiation initiation of BC is raised by the extensive epidemiological data showing increased breast cancer incidence among women who received radiation before mammary gland differentiation [11].

Very young individuals cured with low doses of radiation for benign conditions or treated with multiple fluoroscopies for the management of pulmonary tuberculosis have been demonstrated to have an increase in subsequent BC sometimes as much as threefold. These pre-differentiation stem cells may be uniquely sensitive to other agents in addition to radiation as suggested by the increased risk of BC in women over 40 who received oestrogens in utero. This leads to the hypothesis that

the initial lesion may occur to a stem cell destined to develop into a whole duct. This could already occur in utero or at least prior to puberty resulting in the whole duct being clonal and abnormal, a sick lobe.

Further evidence that clonality predates proliferation comes from other researchers, as Diallo and et al. [12] found a monoclonal origin of some informative cases of DCIS, ADH and papilloma analysed. These data support the earlier reports of Tsai who demonstrated that entire lobules and larger ducts are monoclonal with opposite alleles inactivated within the same breast. They concluded that the breast is organised into distinct regions or patches in which all the epithelial cells show the same X chromosome inactivation pattern.

More recently other researchers [13] have described monomorphic epithelial proliferations extending adjacent to cancers, further suggesting that the sick lobe may have large patches of transformed but not yet premalignant disease. One could easily make the leap that these clonal patches represent one lobe or ductal system, though direct proof is still missing due in part to the difficulty of tracking an arborizing three-dimensional lobe on a two-dimensional slide.

Indeed, the classical assumption that all the initial events of carcinogenesis occurred at the terminal ductal-lobular interface, and then spread towards the nipple, is too simplistic and does not give reason of patterns of the distribution. It appears clear that some cancers are *isolated* events, others are truly *multifocal* but limited to single lobar-ductal units and only a few cases are truly *multicentric*. On this latter point, actually simultaneous transformation in separate lobes is rare, and in larger series of breast endoscopy, even widely separate tumours within a single breast are connected to the same duct system [14].

Many surgical and pathological data support this theory, multifocal invasive BC as well extensive intraductal component in small invasive BC. Moreover, further molecular studies would seem to indicate that serious adverse genetic events are present throughout many ductal trees in what appears to be histologically normal tissue surrounding known cancers.

The fact that volume disparity, together with the apparent unpredictability of clinical patterns, may have implications for frequency, extension and evolution of carcinogenesis has fostered the sick lobe theory (SLT) proposed by Tibor Tot in 2005 [15] and taken up by successive papers [16]. This hypothesis states that in the majority of, especially extensive, cases of BC, the initiating events of carcinogenesis occurred as early as in the mother's womb. Then throughout life, as the lobe both grew and regressed from hormonal and other influences, progression would occur at varying rates in different regions of the ductal tree. For this reason, in a large, but undetermined, number of cases:

- Simultaneous or asynchronous malignant transformation occurs up and down ducts of the entire lobe and not as a result of pagetoid migration.
- As each lobe is relatively independent from any other, the multifocality within the lobar unit is common but multicentricity (simultaneous transformation in separate lobes) is rare.
- If we take account of the composite anatomy of the breast, even widely separate tumours within the same breast may be connected to the same duct system.

The lobar nature of the disease in the majority of BCs represents a hypothesis that could unify genetic, developmental and morphological perspectives of carcinogenesis. Growing scientific evidences supports this model:

- *Early morphological observations* indicate BC may grow in a triangular area with its tip in the nipple and base towards the pectoralis fascia.
- *Large-scale morphological observations* show, in the involvement of the main ducts, malignant cells usually occupy only one of the many ducts suggesting that only one of the many lobes is involved.
- *Developmental and epidemiological studies* support the influence of prenatal and perinatal factors in the individual's risk of developing BC during their adult life.
- *Genetic alterations* may exist in the seemingly normal breast tissue surrounding the cancer, also located as far from the malignant focus. This confirms long time may be needed before any microscopic signs of disease appear.
- *Diagnostic assessment.* Microcalcifications detected on mammogram may also be localised to a triangular area of breast tissue. Even MRI imaging may show segmental or lobar disease distribution in a considerable number of cases. Finally, the new boundaries of ductal echography are founded on the hypothesis of lobar localisation of the disease.

The SLT is in direct conflict with older theories that the initial events all occurred at the terminal ductal-lobular interface and spread in a pagetoid way towards the nipple. The new theory instead proposes that simultaneous or asynchronous malignant transformation occurs up and down ducts of the entire lobe and not as a result of migration. It also proposes that each lobe is relatively independent of the other so that multifocality within the lobar unit is common but multicentricity is rare. As can be easily understood, the question arises how do we turn this new theory into something useful to the operative surgeon trying to do the best job at breast conservation [14].

1.3.3 Centricity and Focality May Be Elusive Models

The routine diagnostic approach is usually established on the *unifocal-multifocal-diffuse-multicentric* patterns:

- *Unifocal*, only one invasive focus which may or may not contain an in situ component
- *Multifocal*, multiple, well-delineated invasive tumour foci separated from each other by uninvolved breast tissue, of the distance between the foci
- *Diffuse*, large area with no distinct tumour mass, not to consider early BC
- *Multicentric*, a term to reserve only to (rare) distant foci

Approach based on the SLT proposes the alternative terms *segmental-peripheral-lobar-multilobar*. The growth patterns of the SLT are easy to apply for the DCIS. In the more common BC, the invasive component may be or may be not

combined with the in situ component; however, descriptions remain unchanged. According to the SLT:

- Both low-grade and high-grade DCIS may exhibit segmental, peripheral and lobar patterns but the high grade tend to be more associated with a lobar pattern.
- Multicentric BCs should be considered rare, as many of them should rather be multifocal if we consider the potential large extension of the lobe.

A comparative outlook is shown in Table 1.3.

These patterns become all relevant in imaging and in clinical assessment (Fig. 1.7), having regard in particular to establish the proper surgery. However, some, but few, BCs cannot be included in the above classification and should

Table 1.3 Routine pathological approach compared to approach of sick lobe theory (SLT)

Routine pathological approach	Approach based on SLT
Unifocal DCIS involves a single TDLU or several neighbouring TDLUs together with the belonging subsegmental or segmental duct(s)	Segmental pattern
Multifocal DCIS involves several distant TDLUs with uninvolved breast tissue in between ^a	Peripheral pattern
Diffuse DCIS involves several distant TDLUs with segmental and/or main duct(s)	Lobar pattern ^b
Multicentric when foci are so distant to be thought as independent from each other	Multilobar disease

Notes

^aSometimes wrongly referred to as multicentric

^bMore often observed in high-grade DCIS

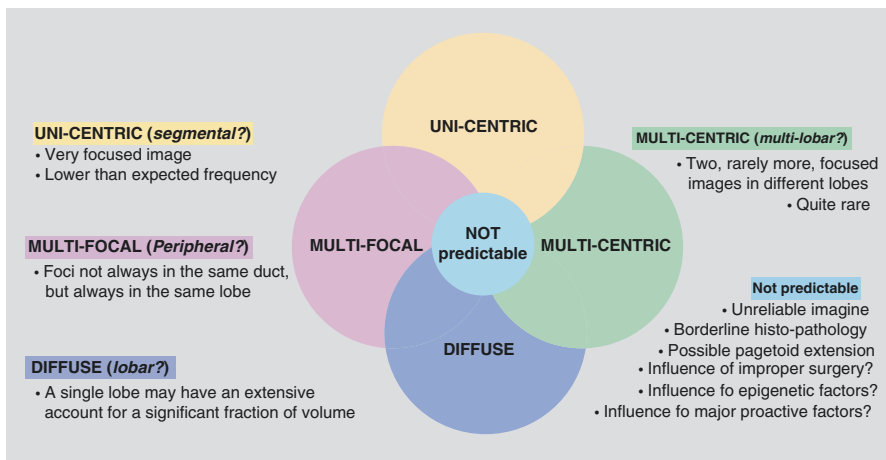


Fig. 1.7 Characteristics of uni-centric, multifocal and multicentric BC in imaging and in clinical assessment

be considered impossible to predict on account of a number of possible features (among which unreliable imaging, borderline histopathology, possible pagetoid extension) and influences (improper surgery, epigenetic or proactive factors and others).

1.4 Time: From Stop-Motion to Movie

Clinical Practice Points

- What we detect at the time of diagnosis is only a stop-motion of the process of carcinogenesis caught at that moment.
- A number of evidences give reason to believe that low-grade DCIS may remain stable or regress in an unknown number of cases.
- All proliferative lesions, even benign, should have a similar, limited but safe, surgical treatment.
- In multifocality as well as in multicentricity, asynchrony is more common than synchrony.

1.4.1 Time(s) Can Change

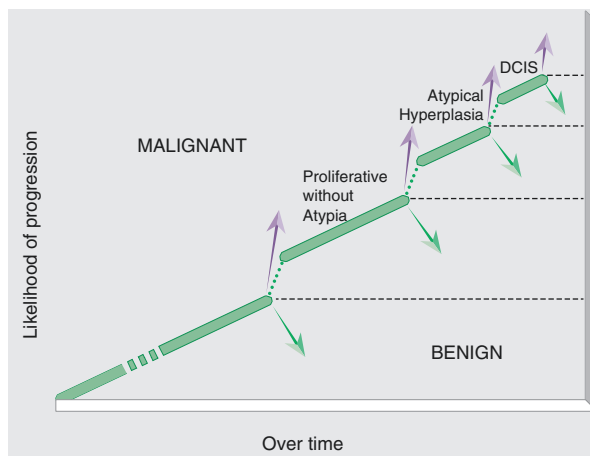
As mentioned above, DCIS is the precursor lesion for most invasive BC, but not all DCIS have sufficient time or the genetic ability to progress to invasive disease. In fact, the cellular modifications, subject to certain condition and limit due to hormonal milieu and nutritional factors, are susceptible to self-repair resulting in a stabilisation of the process.

We must consider however that what we detect is only a stop-motion of the process caught at the time of diagnosis. Like in a moviola video, the process usually moves forward, but it can even move back. In fact regression, perhaps only theoretical, could be possible. As to this latter aspect, Page [17] proposed a graph (Fig. 1.8) showing levels of likelihood of developing true malignancy over time as measured by anatomic lesions found at benign biopsy. The implication is that women having developed proliferative disease or atypical hyperplasia are more likely to proceed to the next step, ductal carcinoma in situ (DCIS). Page believes that as one progresses, certainly to and past the level of atypical hyperplasia, recession of lesions is less likely. According to Page and other scholars, there is good indication that even low-grade DCIS may remain stable or regress up to 50% of the time.

Page's considerations fit very well, in the manner and in the time, with current knowledge. In fact, as seen before, study of Diallo and others [12] found a monoclonal origin of all some informative cases of DCIS, ADH and papilloma analysed, where clonality predates proliferation.

It is also understandable that potential lesions can take a very long time, both in progressive and regressive ways. Moreover, with a high probability, they all

Fig. 1.8 Likelihood of progression over time of proliferative lesions, an indicative scheme [17]. The *dotted lines* of the connection between the different levels mean that the progression is certainly not a guaranteed process but must be viewed as one that is likely. The *arrows pointing up and down* indicates that lesions may progress or recede. The *dashed lines* indicate that they may maintain stability over a long period of time



should have a significant number of common trigger events. For this reason, it is of great practical importance that all proliferative lesions, even benign, should have a similar surgical treatment, that is to say, should have a limited but safe margin of excision.

1.4.2 Timing of Multifocality/Multicentricity

Of greater importance, for surgical planning as well as for the application of preventive measures, are also a few observations about timing of multifocality and multicentricity.

Multifocality, in cases where the SLT is strongly supposed, may be asynchronous or synchronous.

Asynchronous multifocality is due to different sensitivities within the same lobe to oncogenic stimuli of malignant progenitor cells, so that complete malignant transformation may develop earlier in some parts, preceding such transformation at other locations within the same sick lobe.

Synchronous multifocality is less frequent. It is unlikely that all malignant progenitor cells in different parts of the same sick lobe have similar sensitivity to oncogenic stimuli, similar number of replications needed for a sufficient number of genetic alterations and identical biological timing.

Multicentricity. Only rarely several lobes may carry a large number of sufficiently sensitive malignant progenitor cells and develop malignancy at the same time (*synchronous synchronous multicentricity*), while rather such condition is more common at variable times (*asynchronous multicentricity*).

However, the main problem is still understanding *where* in the lobe and *when* in the carcinogenetic timetable we are at the moment of diagnosis.

Conclusions

Clinical Practice Points

- Consideration made on DCIS should be biologically all-encompassing and spatially three dimensional.
- In the earliest stages like DCIS, most BCs may be a lobar disease, that is to say, structurally confined to a single sick lobe.
- DCIS should be seen as a *stage in a neoplastic continuum*, in which most of the genetic instabilities that characterise a subsequent invasion are already present.
- The conventional pathological sections tell us little or nothing about the actual distribution of disease between lobes. Large-scale sections should be fostered.
- The routine multimodality diagnostic assessment gives little evidence of the complex and variable distribution of DCIS and early invasive BC. Ducto-radial echography seems the most promising tool.

Update on natural history. Many evidences support the facts that genetic changes and epigenetic abnormalities involved in BC development are more likely to be perpetuated by cells undergoing continuous branching and ramification starting from the early embryonic life, rather than cells originating within the terminal ductal-lobular units, the majority of which are not developed before birth [18].

According to this sick lobe theory, most cases of DCIS, and consequently of early invasive BC, should be considered a lobar disease because of the simultaneously or asynchronously appearing and development of multiple tumour foci within a single lobe. The malignant transformation of the progenitor cells within the sick lobe is often multifocal (involving separate distant lobules of the lobe) and is the result of many factors: some kind of genetic instability already from its initialization in the maternal womb, more sensitivity to noxious influences than the other lobes within the same breast and decades of postnatal life with accumulation of additional genetic alterations and trigger events.

In presence of DCIS, genetic analysis aiming at topographical mapping revealed that the genetic changes are usually clustered in a segmental distribution in some of the breast samples [19]. Studies provided further evidence that a field of genetic instability can exist around a tumour and that this size was greater than one terminal ductal-lobular unit [20]. Genes that may play a role in invasion control a number of functions, including angiogenesis, adhesion, cell motility, composition of cellular matrix and more. Some of them are known, but genes that are uniquely associated with invasion have not been identified.

Genetic changes at the cellular level, as well as acceptance of sick lobe theory at the architectural level, may help provide a better understanding of DCIS from a different perspective. However, in order to facilitate the development of individualised

therapy, new methods should be recognised to estimate key genetic alterations, as well as structural and trigger events promoting the progression of DCIS to invasive BC. Conversely, since not all cases of DCIS will progress to invasive ductal carcinoma, identifying this subgroup of patients should lead to a reduction of overtreatment.

Diagnostic implications. Morphological data exists that the components of the cancer and precancerous changes may occupy a lobe-like space in the breast. A more accurate location of histopathological lesions can be properly assessed only through large-scale sections. Only the subgross morphology of BC may show unexpected complex patterns due to an extensive in situ component and/or to multiple invasive foci.

Adequate preoperative visualisation of all of the malignant structures within the affected breast and preoperative mapping of the lesions are essential for successful image-guided breast surgery. However, at the moment imaging of DCIS is somewhat elusive and therefore lacking key factors in assuring adequate local control of the disease.

Because the ducts and the lobules are usually less than a millimetre in size, they are barely visible with imaging techniques (mammography, MRI and echography) in their normal state and consequently are often overlooked. As regards DCIS, fibre-optic ductoscopy and MRI galactography, when feasible, appear to be promising in order to achieve a better lobar approach. They may demonstrate, but only in an approximate way, the extension of the filling defect within the ductal system. Even more interesting for its easier availability is the lobar approach with ultrasound imaging (ducto-radial echography). Indeed, comparison of lobar echo-anatomy with large-scale histological slides reveals a good correlation between all the structures involved in the pathological process.

Therapeutic implications. The distribution of the ducts is usually depicted radially with each duct occupying the same sized segment of the breast. Primary data supporting this model is not supported by any primary source, and Astley Cooper himself presented evidence against it. His dissections demonstrated that different ductal systems vary greatly in size and may lie over or under one another, intertwining like the roots of a tree. Indeed, there is only a fair relationship between breast quadrants and lobes, so studies of BC which look only at the distribution of disease between quadrants tell us little or nothing about the actual distribution of disease between lobes. The same applies to all proliferative lesions regarded as precursors [21, 22].

All data relating to DCIS suggest that sufficient tissue must be removed at surgery to avoid proclivity for local recurrence even after more than 30 years of follow-up [23]. This fact should raise questions about anatomical lobe disparities, which could account for some cases of local recurrence after apparent complete excision of the tumour. However, clinical results of treatments do not seem to fully justify too extended excisions, even if the risk of recurrence could last for a long time.

References

1. Page DL, Jensen RS. Ductal carcinoma in situ of the breast: understanding the misunderstood stepchild. *JAMA*. 1996;275(12):948–9.
2. Erbas B, Provenzano E, Armes J, Gertig D. The natural history of ductal carcinoma in situ of the breast: a review. *Breast Cancer Res Treat*. 2006;97(2):135–44.
3. Cooper AP. On the anatomy and diseases of the breast. London: Longman, Orme, Green, Brown and Longmans; 1840.
4. Foschini MP, Eusebi V. The distribution of the earliest forms of breast carcinoma. In: Tot T, editor. *Breast cancer—a lobar disease*. London: Springer; 2011.
5. Tot T. The theory of the sick lobe. In: Tot T, editor. *Breast cancer—a lobar disease*. London: Springer; 2011.
6. Espina V, Liotta LA. What is the malignant nature of human ductal carcinoma in situ? *Nat Rev Cancer*. 2011;11(1):68–75.
7. Radisky DC, Visscher DW, Frank RD, et al. Natural history of age-related lobular involution and impact on breast cancer risk. *Breast Cancer Res Treat*. 2016;155(3):423–30.
8. Wellings SR, Jensen HM, Marcum RG. An atlas of subgross pathology of the human breast with special reference to possible precancerous lesions. *J Natl Cancer Inst*. 1975;55:231–73.
9. Going JJ. Lobar anatomy of human breast and its importance for breast cancer. In: Tot T, editor. *Breast cancer—a lobar disease*. London: Springer; 2011.
10. Amy D, Durante E, Tot T. The lobar approach to breast ultrasound imaging and surgery. *J Med Ultrason*. 2015;42:331–9.
11. Tsai YC, Lu Y, Nichols PW, Zlotnikov G, Jones PA, Smith HS. Contiguous patches of normal human mammary epithelium derived from a single stem cell: implications for breast carcinogenesis. *Cancer Res*. 1996;56:402–4.
12. Diallo R, Schaefer KL, Poremba C, et al. Monoclonality in normal epithelium and in hyperplastic and neoplastic lesions of the breast. *J Pathol*. 2001;193:27–32.
13. Vicini FA, Kestin LL, Goldstein NS, et al. Impact of young age on outcome in patients with ductal carcinoma-in-situ treated with breast-conserving therapy. *J Clin Oncol*. 2000;18:296–306.
14. Dooley W, Bong J, Parker J. Redefining lumpectomy using a modification of the “sick lobe” hypothesis and ductal anatomy. *Int J Breast Cancer*. 2011;2011:726384. doi:[10.4061/2011/726384](https://doi.org/10.4061/2011/726384).
15. Tot T. DCIS, cytokeratins, and the theory of the sick lobe. *Virchows Arch*. 2005;447:1–8.
16. Tot T. Subgross morphology, the sick lobe hypothesis, and the success of breast conservation. *Int J Breast Cancer*. 2011;2011:634021. doi:[10.4061/2011/634021](https://doi.org/10.4061/2011/634021).
17. Page DL. Pathologic evolution of preinvasive breast cancer: the atypical hyperplasia. In: Roses DF, editor. *Breast cancer*. New York: Churchill Livingstone; 1999.
18. Xue F, Michels KB. Breast cancer may originate in utero: the importance of the intrauterine environment for breast cancer development. In: Tot T, editor. *Breast cancer—a lobar disease*. London: Springer; 2011.
19. Sherman ME, Mies C, Gierach GL. Opportunities for molecular epidemiological research on ductal carcinoma in-situ and breast carcinogenesis: interdisciplinary approaches. *Breast Dis*. 2014;34(3):105–16.
20. Smart CE, Simpson PT, Vargas AC, Lakhani SR. Genetic alterations in normal and malignant breast tissue. In: Tot T, editor. *Breast cancer—a lobar disease*. London: Springer; 2011.
21. Gresik CM, Khan SA. Management of high-risk lesions. In: Hansen NM, editor. *Management of patient at high risk for breast cancer*. New York: Springer; 2013. p. 69–80.
22. Pluchinotta AM, Macellari G, Lodovichetti G. Benign lesions of the breast: proliferative lesion with atypia. In: Pluchinotta AM, editor. *The outpatient breast clinic: aiming at best practice*. Cham: Springer; 2015. p. 1–29.
23. Sanders ME, Schuyler PA, Simpson JF, Page DL, Dupont WD. Continued observation of the natural history of low-grade ductal carcinoma in situ reaffirms proclivity for local recurrence even after more than 30 years of follow-up. *Mod Pathol*. 2015;28(5):662–9.

Paolo Luffarelli, Elena Manna, and Lucio Fortunato

2.1 Introduction

Breast cancer is the most commonly diagnosed malignancy among women in the developed countries (29% of all new cancer diagnosis) and the second cause of estimated cancer death in the USA in 2016 with 40,450 deaths out of 281,400 cases (14%) [1].

Roughly, 20–35% of breast cancer cases are expected to be diagnosed as ductal carcinoma in situ (DCIS), and this proportion is increasing [1] for every age group, although currently at a slower rate compared to the last decade (Fig. 2.1) [2].

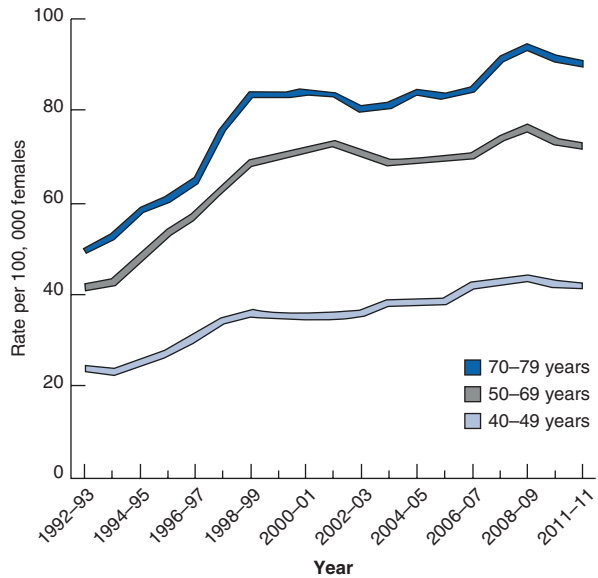
Data on more than five million women from 84 local screening units in Great Britain from the National Health Service Breast Screening Program (NHSBSP) reported that the average incidence of DCIS detected at screening is 0.8–1.6 per 1000 women screened [3]. A significant negative association of screen-detected DCIS cases with the rate of invasive interval cancers is also reported [3].

DCIS is a very curable disease, with a 10-year survival of 98%, according to reports from the Surveillance, Epidemiology, and End Results (SEER) database [4].

For this reason, DCIS is becoming one of the most important diseases in preventive medicine screening, although the full impact of this diagnosis on breast cancer survival needs to be better clarified in the future.

P. Luffarelli, M.D. • E. Manna, M.D. • L. Fortunato, M.D. (✉)
Breast Unit, A.O. San Giovanni-Addolorata, Via Amba Aradam 9, 00184 Roma, Italy
e-mail: lfortunato@hsangiiovanni.roma.it

Fig. 2.1 Trends in ductal carcinoma in situ incidence rates (per 100,000 females, 2-year moving averages, age adjusted to the 2000 US standard population and adjusted for reporting delay) by age (US, 1992–2011). *Source:* Surveillance, Epidemiology, and End Results (SEER) Program, 13 SEER registries, National Cancer Institute, 2014 (With permission from American Cancer Society, Inc., Surveillance Research, 2015)



2.2 Epidemiology

In the USA and in the Netherlands, the rate of DCIS has increased fivefold in the last 25 years, likely due to a widespread adoption of mammography and screening programs [5, 6].

In women less than 50 years of age, the incidence increased less dramatically, followed by a continuous decline, probably due to a drastic reduction in the use of hormone replacement therapy (HRT) in more recent years [7].

The incidence of DCIS is approximately 32 cases per 100,000 women [8].

DCIS is rarely diagnosed in women less than 40 years of age, its incidence steadily increases between the age of 40 and 70, and it plateaus after the age of 70, according to data from the North American Association of Central Cancer Registries (NAACCR) (Table 2.1) [2].

It is estimated that if incidence and survival rates for DCIS will remain constant, in 2020, more than one million women worldwide will have received a diagnosis and treatment for this disease [9].

Prior to the introduction of mammography, DCIS was detected only after excision of palpable lumps and histological examination of the tissue, while nowadays 90% of DCIS are diagnosed by mammography [5, 8, 10–14]. At the present time, only 10% of DCIS cases are detected due to symptoms, such as nipple discharge, Paget's disease of the nipple, or a palpable mass [5].

It is estimated that for DCIS detection rates up to 1.5 per 1000 women screened, there may be one fewer invasive interval cancer for every three cases of DCIS over the subsequent 3 years [3].

Table 2.1 Ductal carcinoma in situ incidence rates^a by race, ethnicity, and age group (US, 2007–2011)

Age	All races	Non-Hispanic White	Non-Hispanic Black	Asian and Pacific Islander	American Indian and Alaska Native ^b	Hispanic/Latina
All ages	25.8	26.6	26.5	23.9	14.4	17.9
20–39 years	3.4	3.7	3.5	3.4	1.9	2.1
40–49 years	37.9	40.7	32.8	42.1	20.5	25.9
50–59 years	57.9	59.8	56.9	57.0	33.4	41.7
60–69 years	81.8	82.9	91.3	70.1	49.6	58.2
70–79 years	84.3	85.8	94.6	66.8	46.3	57.2
≥80 years	47.4	47.6	55.8	33.2	19.4	32.2

Hispanic origin is not mutually exclusive from Asian/Pacific Islander or American Indian/Alaska Native

Source: North American Association of Central Cancer Registries (NAACCR), 2014

With permission from American Cancer Society, Inc., Surveillance Research, 2015

^aPer 100,000 females and age adjusted to the 2000 US standard population

^bData based on Indian Health Service Contract Health Service Delivery Areas. Rates exclude data from Kansas

This finding supports a great benefit of detecting DCIS through screening programs, even if screening recommendations do vary around the world, as mammography is offered triennially in the UK, biennially in most European countries [15], and every 1–2 years in the USA [16, 17].

Currently, DCIS accounts for 17–34% of mammographically detected breast neoplasms [18, 19]. Data from eight population-based trials of mammography screening demonstrate an association between screening programs and the increased incidence of DCIS [18].

In the USA, the incidence rate of DCIS also varies by state, as this is associated with the state-level prevalence of mammography screening (Fig. 2.2) [2].

Detection of DCIS is greatest at baseline screening. The Breast Cancer Surveillance Consortium reported DCIS incidence at the first screening of 1.5 per 1000 women, and this figure decreased to 0.83 per 1000 for subsequent screening mammograms [18].

Higher DCIS detection rates may be associated with diminished returns for invasive cancer by increasing the proportion of low-grade DCIS cases [20].

High-grade DCIS accounts for 47–73% of all cases in different reports [21, 22].

In a study of 3167 DCIS obtained from the Cancer Registry of Norway, the distribution of the tumor grade was 24% for grade 1, 23% for grade 2, and 53% for grade 3 [23]. However, it is well known that the accuracy of DCIS grading has major limitations, as interobserver variability does exist.

It is commonly believed that DCIS progresses to invasive cancer in the absence of treatment, but there is limited data on this issue, because almost all women are currently undergoing some sort of treatment [18, 24, 25]. Long-term follow-up studies of women whose DCIS was erroneously diagnosed as a benign lesion found that 20–53% of these patients were diagnosed with an invasive disease over the course of the next 10 years [26–30].

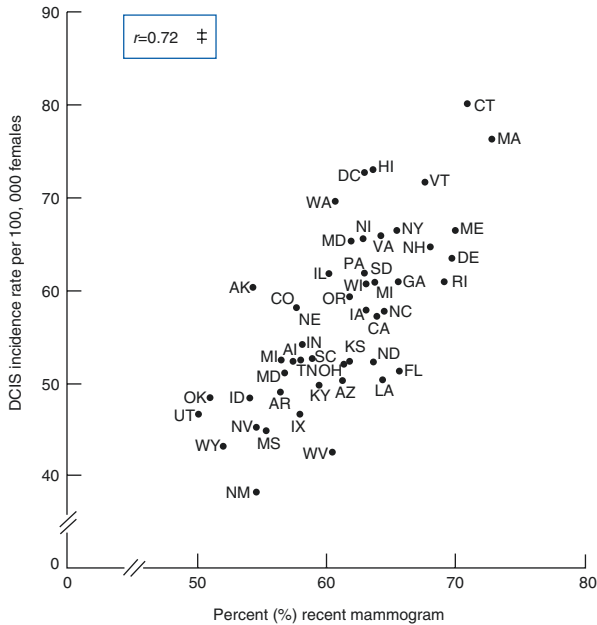


Fig. 2.2 Association between state-level prevalence of mammography screening (percent of women ≥ 40 years who reported having a mammogram within the past year) (2008) and incidence rates (rates are per 100,000 females and age adjusted to the 2000 US standard population) of ductal carcinoma in situ (2007–2011) among women ≥ 40 years. *DCIS* ductal carcinoma in situ. [‡]Pearson correlation coefficient. *Source:* Mammography screening prevalence—Behavior Risk Factor Surveillance System 2008, National Center for Chronic Disease Prevention and Health Promotion, Centers for Disease Control and Prevention, 2010. Incidence—NAACCR, 2014. Not all states met high-quality standards for all years according to NAACCR. DCIS incidence rate for Arkansas is based on incidence data for the years 2007–2009; for Nevada, the rate is based on incidence data for the years 2007–2010. Minnesota did not submit 2007–2011 incidence data to NAACCR and is not included (With permission from American Cancer Society, Inc., Surveillance Research, 2015)

Since high-grade DCIS is associated with a greater risk of 5-year recurrence after treatment [31] and an increased mortality if it progresses to invasive breast cancer [32], this is often considered as stronger evidence that it is a true precursor lesion.

Instead, early detection and treatment of low-grade DCIS remains of unclear demonstrated benefit [33], and it has been suggested that a percentage of women with screen-detected DCIS might not benefit indeed from treatment [34, 35]. It is also reported that the incidence of non-comedo form of DCIS has increased more rapidly compared to the most aggressive (comedo) subtype of DCIS [5].

It has been hypothesized that other than a predisposing type of DCIS which may progress to invasive disease, an indolent form does exist and will remain idle throughout the lifespan of a patient [36].

Therefore, overdiagnosis and overtreatment are current concerns for clinicians, as receiving diagnosis of DCIS, treatment, and follow-up may impact on long-term health and quality of life of women.

For this reason, several randomized trials are undergoing in Europe, in the UK, and in the USA to address the hypothesis that “observation only” may be safe for women diagnosed with “pure” low-grade DCIS [37, 38].

In recent years, diagnosed DCIS cases are usually of small size (less than 2 cm, 51%) and are frequently ER positive (72%) [2]. The distribution of ER status does not seem to vary with race and is different from the invasive counterpart, for which non-Hispanic Black women are known to have a prevalence of triple negative disease [2].

Low- and intermediate-grade DCIS are significantly more commonly ER positive than high-grade disease ($p < 0.001$) (ER+ low grade 99%, intermediate grade 94%, high grade 69%) [39].

A review of 15 screening programs from 12 countries found that 67–90% of DCIS received breast conservation surgery (BCS), and in 41–100% of the cases, this was followed by radiotherapy [40]. Similar findings have been reported by a study in Western Australia [41].

Invasive cancer is not infrequently found in the specimen obtained after resection of DCIS and is reported in 8–43% of such cases [6]. This major variability can be in part explained by the size and the number of biopsies obtained at the diagnostic level. Most studies, however, agree that the larger the lesions, the more frequent an upgrade is reported [6]. Different studies carry conflicting results, as grade is a predictor for diagnosing an invasive component at final pathology.

2.3 Risk Factors

In literature, multiple risk factors are reported for the development of DCIS. In general, they are shared with those—even better studied—of the invasive counterpart.

2.3.1 Family History

There is evidence, from epidemiological studies, to suggest an inherited predisposition to DCIS. One study reported that women affected by DCIS are 2.4 times (95% CI 0.8, 7.2) more likely to have an affected mother—or sister—with breast cancer compared to controls [42]. An older study of almost 40,000 women reported that a family history of DCIS carries a greater risk of the disease among relatives compared to a family history of invasive breast cancer. In women aged 30–49 years, the odds ratio (OR) for developing DCIS was calculated as 2.4 (95% CI 1.1, 4.9) compared to 1.7 (95% CI 0.9, 3.4) for invasive cancer. Similarly, in women aged 50 years, the risks were slightly reduced, but the OR was 2.2 for DCIS (95% CI 1.0, 4.2) and 1.5 for invasive disease (95% CI 1.0, 2.2) [43].

However, these findings were not confirmed in the Million Women Study, in which the association with family history was similar for DCIS and IDC [44].

2.3.2 Age

As reported previously, age is an important risk factor to develop a DCIS (see Table 2.1).

2.3.3 Genetic Risk Assessment

Petridis et al. [45] have tried to identify genetic polymorphisms that predispose to DCIS. They pooled data from 38 studies including 5067 cases of DCIS, 24,584 cases of invasive ductal carcinoma, and 37,467 controls, all genotyped using a selected array.

They found that 67% of 76 known breast cancer predisposition loci also showed an association with DCIS and concluded that there is a shared genetic susceptibility for invasive ductal carcinoma and DCIS [45].

Furthermore, two independent single nucleotide polymorphisms (SNPs) were specific to low-/intermediate-grade DCIS, while no association with high-grade DCIS was found, and this was independent of ER status [45].

An additional study from the National Cancer Institute's Breast and Prostate Cancer Cohort Consortium (BPC3) found that five SNPs were significantly associated with DCIS risk and that several of the known BC susceptibility loci are risk factors for both DCIS and invasive breast cancer [46].

van der Groep et al. [47] compared DCIS lesions of 34 proven BRCA1 and BRCA2 germline mutation carriers with their accompanying invasive lesions. Both were stained by immunohistochemistry for ER, progesterone receptor (PR), human epidermal growth factor receptor (HER)2/neu, cytokeratin (CK) 5/CK6 and CK14, epidermal growth factor receptor (EGFR), and Ki67. They concluded that although the number of cases studied was low, DCIS lesions, in BRCA1 and BRCA2 mutations carriers, and their accompanying invasive cancers are usually of a similar molecular subtype, thereby providing evidence that DCIS is a direct precursor lesion in these hereditary predisposed patients.

Authors also hypothesized that crucial carcinogenetic events leading to these phenotypes are antecedents to the invasive stage.

Although it is generally recognized that a multitude of factors are involved in the risk of developing in situ cancer or an invasive recurrence, it was shown that the microenvironment has a major role in the transition from preinvasive to invasive growth [48, 49] and that the myoepithelium is considered a regulatory mechanism in this process [6].

2.3.4 Ethnicity

DCIS is more common in Caucasian and Black women compared with Asian and Pacific Islander and is less common in Hispanics [2]. Lower incidence may be, however, accounted for a lower access and utilization of mammography.

No data about the incidence of DCIS in both the urban and rural populations was available before 1973, when a study reported that the incidence of DCIS, although increasing in both populations, was higher in the former [50].

Women with poor schooling (particularly those with no high school degree) are reported to have a higher incidence of DCIS, as well [51].

‡DCIS rates vary consistently with county-level poverty within each racial and ethnic group, according to a study of the American Cancer Society [2] (Fig. 2.3).

Finally, the risk of death from breast cancer and invasive recurrence after DCIS are higher in Black women than in White women (RR of 1.35 and 1.4, respectively). However, studies adjusted for a more detailed set of tumor factors found no differences between racial groups and risk of DCIS or invasive recurrence (RR 1.12) [5].

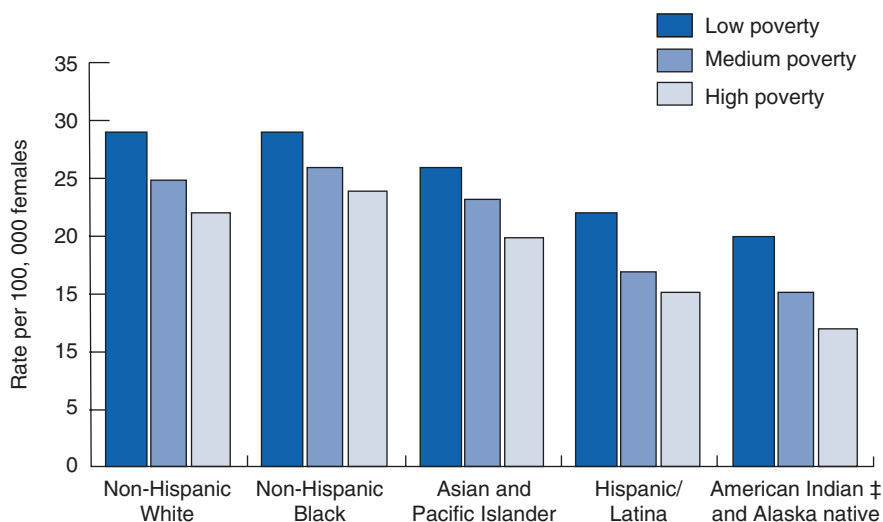


Fig. 2.3 Ductal carcinoma in situ incidence rates (per 100,000 females and age adjusted to the 2000 US standard population) by race, ethnicity, and county-level poverty (low poverty: county poverty rate <10%; medium poverty: county poverty rate 10.0–19.9%; high poverty: county poverty rate \geq 20.0%), US, 2007–2011. Hispanic origin is not mutually exclusive from Asian/Pacific Islander or American Indian/Alaska Native. ‡Data based on Indian Health Service Contract Health Service Delivery Areas. Rates exclude data from Kansas. *Source:* NAACCR, 2014 (With permission from American Cancer Society, Inc., Surveillance Research, 2015)

2.3.5 Reproductive Factors

Women with older age at menopause have an increased incidence of DCIS based on data from the Connecticut Tumor Registry [52]. This was conformed from a study of 2019 women with DCIS in a population-based research from Australia [53].

Several studies found that nulliparity or women who had a pregnancy after 30 years of age also experience a higher incidence of DCIS [43].

A study of 1.2 million women living in the UK showed no association of DCIS with early menarche [44].

2.3.6 Hormone Replacement Therapy

Association between HRT and DCIS is inconsistent across studies [44, 54, 55].

The Women's Health Initiative (WHI) study reported that estrogen plus progestin use might increase risk of DCIS in postmenopausal women, while estrogen alone seem to be associated with a decreased risk [56].

A large prospective study in the UK reported a 56% increased risk for DCIS in women taking HRT, and the risk increased proportionally with the duration of HRT assumption [57].

However, while women with a HRT use for more than 5 years had greater risk of DCIS compared with never users (pooled RR = 1.41) [58, 59], women with HRT use for less than 5 years had a significantly lower risk of DCIS compared to those who never received HRT (pooled relative risk [RR] = 0.78).

However, several other studies did not confirm an association between risk of DCIS and HRT [18, 60–64].

2.3.7 Dietary and Metabolic Factors

The association between body mass index (BMI) and DCIS is mixed and not widely studied.

While BMI [65–72], high alcohol consumption [73–75], tobacco use [76], and a diet rich of animal fat with a low consumption of fibers would appear to be associated with an increased risk of breast cancer [77], there is insufficient evidence that this holds true for DCIS.

In fact, multiple studies found no association between BMI, or alcohol consumption, and DCIS [43, 52, 60]. In contrast, a study on 287,115 women found an increased risk for DCIS in heavily obese (BMI \geq 35.0 kg/m²) postmenopausal women not taking HRT (OR 1.46) [78].

A population-based case-control study conducted in Los Angeles County analyzed the relationship between DCIS and physical activity on 567 women compared with 1026 control. The authors reported approximately 35% lower risk of DCIS among women with any exercise activity compared with inactive women, although no significant trend was observed [79].

Observational studies have suggested that beta-carotene, vegetables, fruits, and antioxidants may have protective effects against breast cancer. However, a recent randomized controlled trial which compared 624 women to a placebo group for a period of 9.4 years found no such protective effects of a diet supplemented with beta-carotene, vitamins C and E, fruits, and other antioxidants [80].

2.3.8 Drugs

Data from clinical trials on chemoprevention for women with high risk of breast cancer reported a decreased incidence of DCIS using tamoxifen or raloxifene [64].

2.3.9 Density of Breast Tissue

Mammographic detection of increased density of breast tissue is also a risk factor for breast cancer. A recent study reported that women with 75% or higher density had an increased risk of breast cancer compared with women with mammograms with less than 10% density [81].

For this reason, high-risk patients who have dense breast tissue detected by mammogram have been recommended to obtain a follow-up MRI of the breast so that lesions are not missed [82].

Breast density is also an associated risk factor for the development of contralateral breast cancer after treatment for DCIS. In one study, there was a threefold increased risk of invasive contralateral cancer as compared to women with an average breast density [83].

Data on six studies including more than 10,000 women found a strong association between DCIS and breast density in the group of more than 55 years of age. In general, higher mammographic density is associated with a twofold increase risk for DCIS, and this is particularly evident in women younger than age 55 [84].

2.3.10 Subsequent Breast Cancer

At last, risk of a subsequent breast cancer event following DCIS was significantly correlated with age at diagnosis, grade of tumor, primary treatment, and the use of adjuvant radiotherapy [41].

The Eastern Cooperative Oncology Group (ECOG) study reported in a large, prospective, nonrandomized protocol including 670 patients that the low-intermediate grade group had a 10.5% risk of local recurrence while the high-grade group had an 18% risk, at a median follow-up of 6.7 years. Interestingly, 35% of such recurrences were invasive [85].

However, many studies have reported that, strikingly, grade may not be significantly associated with risk of local recurrence after diagnosis of DCIS [5, 86, 87].

Conclusions

In conclusion, DCIS is a heterogeneous disease which is frequently diagnosed in women undergoing screening mammography programs.

Although the natural history of different subtypes of DCIS is yet to be fully clarified, current protocols are centered on early diagnosis and treatment to prevent progression and invasive disease.

Integration of epidemiologic data along with clinical, morphologic, and molecular information will likely play a key role to provide a better management of this complex disease.

The present review aims to clarify epidemiologic issues and risk factors associated with this disease and helps clinicians to plan a modern diagnostic and therapeutic approach.

References

1. Siegel RL, Miller KD, Jemal A. Cancer Statistics, 2016. *CA Cancer J Clin.* 2016;66:7–30.
2. Cancer Fact & Figures 2015. Corporate Center: American Cancer Society Inc. <http://www.cancer.org/acs/groups/content/@editorial/documents/document/acspc-044552.pdf>
3. Duffy SW, Dibden A, Michalopoulos D, Offman J, Parmar D, Jenkins J, Collins B, Robson T, Scorfield S, Green K, Hall C, Liao XH, Ryan M, Johnson F, Stevens G, Kearins O, Sellars S, Patnick J. Screen detection of ductal carcinoma in situ and subsequent incidence of invasive interval breast cancers: a retrospective population-based study. *Lancet Oncol.* 2016;17(1):109–14.
4. Tabar L, Fagerberg G, Chen HH, Duffy SW, Smart CR, Gad A, Smith RA. Efficacy of breast cancer screening by age: new results from the Swedish Two-County Trial. *Cancer.* 1995;75(10):2507–17.
5. Virnig BA, Tuttle TM, Shamlivan T, Kane RL. Ductal carcinoma in situ of the breast: a systematic review of incidence, treatment, and outcomes. *J Natl Cancer Inst.* 2010;102(3):170–8.
6. Groen EJ, Elshof LE, Visser LL, Rutgers EJ, Winter-Warnars HA, Lips EH, Wesseling J. Finding the balance between over- and under-treatment of ductal carcinoma in situ (DCIS). *Breast.* 2017;31:274–83.
7. Horner MJ, Ries LAG, Krapcho M, Neyman N, Aminou R, Howlader N, Altekruse SF, Feuer EJ, Huang L, Mariotto A, Miller BA, Lewis DR, Eisner MP, Stinchcomb DG, Edwards BK. SEER cancer statistics review, 1975–2006. Bethesda: National Cancer Institute; 2009.
8. Badruddoja M. Ductal carcinoma in situ of the breast: a surgical perspective. *Int J Surg Oncol.* 2012;2012:761364.
9. Sacchini V, Fortunato L, Cody Iii HS, Van Zee KJ, Cutuli B, Bonanni B. Breast ductal carcinoma in situ. *Int J Surg Oncol.* 2012;2012:753267.
10. Ernster VL, Barclay J, Kerlikowske K, Grady D, Henderson C. Incidence of and treatment for ductal carcinoma in situ of the breast. *JAMA.* 1996;275(12):913–8.
11. Levi F, Te VC, Randimbison L, La Vecchia C. Trends of in situ carcinoma of the breast in Vaud, Switzerland. *Eur J Cancer.* 1997;33(6):903–6.
12. Luke C, Priest K, Roder D. Changes in incidence of in situ and invasive breast cancer by histology type following mammography screening. *Asian Pac J Cancer Prev.* 2006;7(1):69–74.
13. van Steenbergen LN, Voogd AC, Roukema JA, Louwman WJ, Duijm LE, Coebergh JW, van de Poll-Franse LV. Screening caused rising incidence rates of ductal carcinoma in situ of the breast. *Breast Cancer Res Treat.* 2009;115(1):181–3.
14. Barchielli A, Federico M, De Lisi V, Bucchi L, Ferretti S, Paci E, Ponti A, Buiatti E. In situ breast cancer: incidence trend and organised screening programmes in Italy. *Eur J Cancer.* 2005;41(7):1045–50.

15. Liston J, Wilson R. Clinical guidelines for breast cancer screening assessment. NHSBSP; 2010.
16. Oeffinger KC, Fontham ET, Etzioni R, Herzig A, Michaelson JS, Shih YC, Walter LC, Church TR, Flowers CR, LaMonte SJ, Wolf AM, DeSantis C, Lortet-Tieulent J, Andrews K, Manassaram-Baptiste D, Saslow D, Smith RA, Brawley OW, Wender R, American Cancer Society. Breast cancer screening for women at average risk: 2015 guideline update from the American Cancer Society. *JAMA*. 2015;314:1599–614.
17. Siu AL, Preventive Services Task Force US. Screening for breast cancer: U.S. Preventive Services Task Force Recommendation Statement. *Ann Intern Med*. 2016;164(4):279–96.
18. Ernster VL, Ballard-Barbash R, Barlow WE, et al. Detection of ductal carcinoma in situ in women undergoing screening mammography. *J Natl Cancer Inst*. 2002;94:1546–54.
19. May DS, Lee NC, Richardson LC, Giustozzi AG, Bobo JK. Mammography and breast cancer detection by race and Hispanic ethnicity: results from a national program (United States). *Cancer Causes Control*. 2000;11(8):697–705.
20. Shieh Y, Eklund M, Esserman L. Detection of ductal carcinoma in situ and subsequent interval cancers. *BMJ*. 2016;352:i551.
21. Cuzick J, Sestak I, Pinder SE, Ellis IO, Forsyth S, Bundred NJ, Forbes JF, Bishop H, Fentiman IS, George WD. Effect of tamoxifen and radiotherapy in women with locally excised ductal carcinoma in situ: long-term results from the UK/ANZ DCIS trial. *Lancet Oncol*. 2011;12:21–9.
22. Fisher ER, Land SR, Saad RS, Fisher B, Wickerham DL, Wang M, Costantino JP, Wolmark N. Pathologic variables predictive of breast events in patients with ductal carcinoma in situ. *Am J Clin Pathol*. 2007;128:86–91.
23. Sørum R, Hofvind S, Skaane P, Haldorsen T. Trends in incidence of ductal carcinoma in situ: the effect of a population-based screening programme. *Breast*. 2010;19(6):499–505.
24. Kuerer HM, Albarracin CT, Yang WT, Cardiff RD, Brewster AM, Symmans WF, Hylton NM, Middleton LP, Krishnamurthy S, Perkins GH, Babiera G, Edgerton ME, Czerniecki BJ, Arun BK, Hortobagyi GN. Ductal carcinoma in situ: state of the science and roadmap to advance the field. *J Clin Oncol*. 2009;27(2):279–88.
25. Ozanne EM, Shieh Y, Barnes J, Bouzan C, Hwang ES, Esserman LJ. Characterizing the impact of 25 years of DCIS treatment. *Breast Cancer Res Treat*. 2011;129(1):165–73.
26. Eusebi V, Feudale E, Foschini MP, Micheli A, Conti A, Riva C, Di Palma S, Rilke F. Long-term follow-up of in situ carcinoma of the breast. *Semin Diagn Pathol*. 1994;11:223–35.
27. Erbas B, Provenzano E, Armes J, Gertig D. The natural history of ductal carcinoma in situ of the breast: a review. *Breast Cancer Res Treat*. 2006;97:135–44.
28. Sanders ME, Schuyler PA, Dupont WD, Page DL. The natural history of low-grade ductal carcinoma in situ of the breast in women treated by biopsy only revealed over 30 years of long-term follow-up. *Cancer*. 2005;103:2481–4.
29. Collins LC, Tamimi RM, Baer HJ, Connolly JL, Colditz GA, Schnitt SJ. Outcome of patients with ductal carcinoma in situ untreated after diagnostic biopsy: results from the Nurses' Health Study. *Cancer*. 2005;103:1778–84.
30. Allred DC. Ductal carcinoma in situ: terminology, classification, and natural history. *J Natl Cancer Inst Monogr*. 2010;2010:134–8.
31. Fisher B, Dignam J, Wolmark N, Mamounas E, Costantino J, Poller W, Fisher ER, Wickerham DL, Deutsch M, Margolese R, Dimitrov N, Kavanah M. Lumpectomy and radiation therapy for the treatment of intraductal breast cancer: findings from National Surgical Adjuvant Breast and Bowel Project B-17. *J Clin Oncol*. 1998;16:441–52.
32. Narod SA, Iqbal J, Giannakeas V, Sopik V, Sun P. Breast cancer mortality after a diagnosis of ductal carcinoma in situ. *JAMA Oncol*. 2015;1:888–96.
33. Esserman L, Yau C. Rethinking the standard for ductal carcinoma in situ treatment. *JAMA Oncol*. 2015;1:881–3.
34. Evans AJ, Pinder SE, Ellis IO, Wilson AR. Screen detected ductal carcinoma in situ (DCIS): overdiagnosis or an obligate precursor of invasive disease? *J Med Screen*. 2001;8(3):149–51.
35. Jones JL. Overdiagnosis and overtreatment of breast cancer: progression of ductal carcinoma in situ: the pathological perspective. *Breast Cancer Res*. 2006;8(2):204.

36. Lyng E, Ponti A, James T, Májek O, von Euler-Chelpin M, Anttila A, Fitzpatrick P, Frigerio A, Kawai M, Scharpantgen A, Broeders M, Hofvind S, Vidal C, Ederra M, Salas D, Bulliard JL, Tomatis M, Kerlikowske K, Taplin S, ICSN DCIS Working group. Variation in detection of ductal carcinoma in situ during screening mammography: a survey within the International Cancer Screening Network. *Eur J Cancer*. 2014;50(1):185–92.
37. Elshof LE, Tryfonidis K, Slaets L, van Leeuwen-Stok AE, Skinner VP, Dif N, et al. Feasibility of a prospective, randomised, open-label, international multicentre, phase III, non-inferiority trial to assess the safety of active surveillance for low risk ductal carcinoma in situ - the LORD study. *Eur J Cancer*. 2015;51:1497–510.
38. Francis A, Thomas J, Fallowfield L, Wallis M, Bartlett JMS, Brookes C, et al. Addressing overtreatment of screen detected DCIS. LORIS trial. *Eur J Cancer*. 2015;51(16):2296–303.
39. Thomas J, Hanby A, Pinder S, Ellis I, Macartney J, Clements K, Lawrence G, Bishop H, Sloane Project Steering Group. Implications of inconsistent measurement of ER status in non-invasive breast cancer: a study of 1,684 cases from the Sloane Project. *Breast J*. 2008;14(1):33–8.
40. Ponti A, Lyng E, James T, Májek O, von Euler-Chelpin M, Anttila A, Fitzpatrick P, Mano MP, Kawai M, Scharpantgen A, Fracheboud J, Hofvind S, Vidal C, Ascunce N, Salas D, Bulliard JL, Segnan N, Kerlikowske K, Taplin S, ICSN DCIS Working group. International variation in management of screen-detected ductal carcinoma in situ of the breast. *Eur J Cancer*. 2014;50(15):2695–704.
41. Butler-Henderson K, Lee AH, Lenzo NP, Price RI. Epidemiology of ductal carcinoma in situ in Western Australia: implications for surgical margins and management. *Breast Cancer*. 2015;22(6):641–7.
42. Claus EB, Stowe M, Carter D. Family history of breast and ovarian cancer and the risk of breast carcinoma in situ. *Breast Cancer Res Treat*. 2003;78(1):7–15.
43. Kerlikowske K, Barclay J, Grady D, Sickles EA, Ernster V. Comparison of risk factors for ductal carcinoma in situ and invasive breast cancer. *J Natl Cancer Inst*. 1997;89(1):76–82.
44. Reeves GK, Pirie K, Green J, Bull D, Beral V, Million Women Study C. Comparison of the effects of genetic and environmental risk factors on in situ and invasive ductal breast cancer. *Int J Cancer*. 2012;131(4):930–7.
45. Petridis C, Brook MN, Shah V, Kohut K, Gorman P, Caneppele M, Levi D, Papouli E, Orr N, Cox A, Cross SS, Dos-Santos-Silva I, Peto J, Swerdlow A, Schoemaker MJ, Bolla MK, Wang Q, Dennis J, Michailidou K, Benitez J, González-Neira A, Tessier DC, Vincent D, Li J, Figueroa J, Kristensen V, Borresen-Dale AL, Soucy P, Simard J, Milne RL, Giles GG, Margolin S, Lindblom A, Brüning T, Brauch H, Southey MC, Hopper JL, Dörk T, Bogdanova NV, Kabisch M, Hamann U, Schmutzler RK, Meindl A, Brenner H, Arndt V, Winqvist R, Pylkäs K, Fasching PA, Beckmann MW, Lubinski J, Jakubowska A, Mulligan AM, Andrulis IL, Tollenaar RA, Devilee P, Le Marchand L, Haiman CA, Mannermaa A, Kosma VM, Radice P, Peterlongo P, Marme F, Burwinkel B, van Deurzen CH, Hollestelle A, Miller N, Kerin MJ, Lambrechts D, Floris G, Wesseling J, Flyger H, Bojesen SE, Yao S, Ambrosone CB, Chenevix-Trench G, Truong T, Guénel P, Rudolph A, Chang-Claude J, Nevanlinna H, Blomqvist C, Czene K, Brand JS, Olson JE, Couch FJ, Dunning AM, Hall P, Easton DF, Pharoah PD, Pinder SE, Schmidt MK, Tomlinson I, Roylance R, García-Closas M, Sawyer EJ. Genetic predisposition to ductal carcinoma in situ of the breast. *Breast Cancer Res*. 2016;18(1):22.
46. Campa D, Barrdahl M, Gaudet MM, Black A, Chanock SJ, Diver WR, Gapstur SM, Haiman C, Hankinson S, Hazra A, Henderson B, Hoover RN, Hunter DJ, Joshi AD, Kraft P, Le Marchand L, Lindström S, Willett W, Travis RC, Amiano P, Siddiq A, Trichopoulos D, Sund M, Tjønneland A, Weiderpass E, Peeters PH, Panico S, Dossus L, Ziegler RG, Canzian F, Kaaks R. Genetic risk variants associated with in situ breast cancer. *Breast Cancer Res*. 2015;17:82.
47. van der Groep P, van Diest PJ, Menko FH, Bart J, de Vries EG, van der Wall E. Molecular profile of ductal carcinoma in situ of the breast in BRCA1 and BRCA2 germline mutation carriers. *J Clin Pathol*. 2009;62(10):926–30.
48. Sharma M, Beck AH, Webster JA, Espinosa I, Montgomery K, Varma S, et al. Analysis of stromal signatures in the tumor microenvironment of ductal carcinoma in situ. *Breast Cancer Res Treat*. 2009;123:397–404.

49. Ma X-J, Dahiya S, Richardson E, Erlander M, Sgroi DC. Gene expression profiling of the tumor microenvironment during breast cancer progression. *Breast Cancer Res.* 2009;11:R7.
50. Chen CY, Sun LM, Anderson BO. Paget disease of the breast: changing patterns of incidence, clinical presentation, and treatment in the U.S. *Cancer.* 2006;107(7):1448–58.
51. Weaver DL, Vacek PM, Skelly JM, Geller BM. Predicting biopsy outcome after mammography: what is the likelihood the patient has invasive or in situ breast cancer? *Ann Surg Oncol.* 2005;12(8):660–73.
52. Claus EB, Stowe M, Carter D. Breast carcinoma in situ: risk factors and screening patterns. *J Natl Cancer Inst.* 2001;93(23):1811–7.
53. Krickler A, Goumas C, Armstrong B. Ductal carcinoma in situ of the breast, a population-based study of epidemiology and pathology. *Br J Cancer.* 2004;90(7):1382–5.
54. Chlebowski RT, Hendrix SL, Langer RD, Stefanick ML, Gass M, Lane D, Rodabough RJ, Gilligan MA, Cyr MG, Thomson CA, Khandekar J, Petrovitch H, McTiernan A, Investigators WHI. Influence of estrogen plus progestin on breast cancer and mammography in healthy postmenopausal women: the Women’s Health Initiative Randomized Trial. *JAMA.* 2003;289(24):3243–53.
55. Collaborative Group on Hormonal Factors in Breast Cancer. Breast cancer and hormone replacement therapy: collaborative reanalysis of data from 51 epidemiological studies of 52,705 women with breast cancer and 108,411 women without breast cancer. *Lancet.* 1997;350:1047–59.
56. Luo J, Cochrane BB, Wactawski-Wende J, Hunt JR, Ockene JK, Margolis KL. Effects of menopausal hormone therapy on ductal carcinoma in situ of the breast. *Breast Cancer Res Treat.* 2013;137:915–25.
57. Reeves GK, Beral V, Green J, Gathani T, Bull D. Hormonal therapy for menopause and breast-cancer risk by histological type: a cohort study and meta-analysis. *Lancet Oncol.* 2006;7(11):910–8.
58. Menell JH, Morris EA, Dershaw DD, Abramson AF, Brogi E, Liberman L. Determination of the presence and extent of pure ductal carcinoma in situ by mammography and magnetic resonance imaging. *Breast J.* 2005;11:382–90.
59. Allen LR, Lago-Toro CE, Hughes JH, Careaga E, Brown AT, Chernick M, Barrio AV, Frazier TG. Is there a role for MRI in the pre-operative assessment of patients with DCIS? *Ann Surg Oncol.* 2010;17:2395–400.
60. Gapstur SM, Morrow M, Sellers TA. Hormone replacement therapy and risk of breast cancer with a favorable histology: results of the Iowa Women’s Health Study. *JAMA.* 1999;281(22):2091–141.
61. Claus EB, Stowe M, Carter D. Oral contraceptives and the risk of ductal breast carcinoma in situ. *Breast Cancer Res Treat.* 2003;81(2):129–36.
62. Cuzick J, Forbes JF, Sestak I, Cawthorn S, Hamed H, Holli K, Howell A, International Breast Cancer Intervention Study I Investigators. Long-term results of tamoxifen prophylaxis for breast cancer—96-month follow-up of the randomized IBIS-I trial. *J Natl Cancer Inst.* 2007;99:272–82.
63. Powles TJ, Ashley S, Tidy A, Smith IE, Dowsett M. Twenty-year follow-up of the Royal Marsden randomized, double-blinded tamoxifen breast cancer prevention trial. *J Natl Cancer Inst.* 2007;99:283–90.
64. Vogel VG, Costantino JP, Wickerham DL, Cronin WM, Cecchini RS, Atkins JN, Bevers TB, Fehrenbacher L, Pajon ER Jr, Wade JL 3rd, Robidoux A, Margolese RG, James J, Lippman SM, Runowicz CD, Ganz PA, Reis SE, McCaskill-Stevens W, Ford LG, Jordan VC, Wolmark N, National Surgical Adjuvant Breast and Bowel Project (NSABP). Effects of tamoxifen vs raloxifene on the risk of developing invasive breast cancer and other disease outcomes: the NSABP Study of Tamoxifen and Raloxifene (STAR) P-2 trial. *JAMA.* 2006;295:2727–41.
65. Emaus MJ, van Gils CH, Bakker MF, Bisschop CN, Monnikhof EM, et al. Weight change in middle adulthood and breast cancer risk in the EPIC-PANACEA study. *Int J Cancer.* 2014;135(12):2887–99.

66. Key TJ, Appleby PN, Reeves GK, Roddam A, Dorgan JF, et al. Body mass index, serum sex hormones, and breast cancer risk in postmenopausal women. *J Natl Cancer Inst.* 2003;95(16):1218–26.
67. Suzuki R, Iwasaki M, Inoue M, Sasazuki S, Sawada N, Yamaji T, Shimazu T, Tsugane S, Japan Public Health Center-based Prospective Study Group. Body weight at age 20 years, subsequent weight change and breast cancer risk defined by estrogen and progesterone receptor status—the Japan public health center-based prospective study. *Int J Cancer.* 2011;129(5):1214–24.
68. Feigelson HS, Patel AV, Teras LR, Gansler T, Thun MJ, Calle EE. Adult weight gain and histopathologic characteristics of breast cancer among postmenopausal women. *Cancer.* 2006;107(1):12–21.
69. Vrieling A, Buck K, Kaaks R, Chang-Claude J. Adult weight gain in relation to breast cancer risk by estrogen and progesterone receptor status: a meta-analysis. *Breast Cancer Res Treat.* 2010;123(3):641–9.
70. Han D, Nie J, Bonner MR, McCann SE, Muti P, Trevisan M, Ramirez-Marrero FA, Vito D, Freudenheim JL. Lifetime adult weight gain, central adiposity, and the risk of pre- and postmenopausal breast cancer in the Western New York exposures and breast cancer study. *Int J Cancer.* 2006;119(12):2931–7.
71. Kawai M, Minami Y, Kuriyama S, Kakizaki M, Kakugawa Y, Nishino Y, Ishida T, Fukao A, Tsuji I, Ohuchi N. Adiposity, adult weight change and breast cancer risk in postmenopausal Japanese women: the Miyagi Cohort Study. *Br J Cancer.* 2010;103(9):1443–7.
72. Eliassen AH, Colditz GA, Rosner B, Willett WC, Hankinson SE. Adult weight change and risk of postmenopausal breast cancer. *JAMA.* 2006;296(2):193–201.
73. Singletary KW, Gapstur SM. Alcohol and breast cancer: review of epidemiologic and experimental evidence and potential mechanisms. *JAMA.* 2001;286(17):2143–51.
74. Hamajima N, Hirose K, Tajima K, Rohan T, Calle EE, Heath CW Jr, Coates RJ, Liff JM, Talamini R, Chantarakul N, Koetsawang S, Rachawat D, Morabia A, Schuman L, Stewart W, Szklo M, Bain C, Schofield F, Siskind V, Band P, Coldman AJ, Gallagher RP, Hislop TG, Yang P, Kolonel LM, Nomura AM, Hu J, Johnson KC, Mao Y, De Sanjosé S, Lee N, Marchbanks P, Ory HW, Peterson HB, Wilson HG, Wingo PA, Ebeling K, Kunde D, Nishan P, Hopper JL, Colditz G, Gajalanski V, Martin N, Pardthaisong T, Silpisornkosol S, Theetranont C, Boosiri B, Chutivongse S, Jimakorn P, Virutamasen P, Wongsrichanalai C, Ewertz M, Adami HO, Bergkvist L, Magnusson C, Persson I, Chang-Claude J, Paul C, Skegg DC, Spears GF, Boyle P, Evstifeeva T, Daling JR, Hutchinson WB, Malone K, Noonan EA, Stanford JL, Thomas DB, Weiss NS, White E, Andrieu N, Brémond A, Clavel F, Gairard B, Lansac J, Piana L, Renaud R, Izquierdo A, Viladiu P, Cuevas HR, Ontiveros P, Palet A, Salazar SB, Aristizabel N, Cuadros A, Tryggvadottir L, Tulinius H, Bachelot A, Lê MG, Peto J, Franceschi S, Lubin F, Modan B, Ron E, Wax Y, Friedman GD, Hiatt RA, Levi F, Bishop T, Kosmelj K, Primic-Zakelj M, Ravnihar B, Stare J, Beeson WL, Fraser G, Bullbrook RD, Cuzick J, Duffy SW, Fentiman IS, Hayward JL, Wang DY, McMichael AJ, McPherson K, Hanson RL, Leske MC, Mahoney MC, Nasca PC, Varma AO, Weinstein AL, Moller TR, Olsson H, Ranstam J, Goldbohm RA, van den Brandt PA, Apelo RA, Baens J, de la Cruz JR, Javier B, Lacaya LB, Ngelangel CA, La Vecchia C, Negri E, Marubini E, Ferraroni M, Gerber M, Richardson S, Segala C, Gatei D, Kenya P, Kungu A, Mati JG, Brinton LA, Hoover R, Schairer C, Spirtas R, Lee HP, Rookus MA, van Leeuwen FE, Schoenberg JA, McCredie M, Gammon MD, Clarke EA, Jones L, Neil A, Vessey M, Yeates D, Appleby P, Banks E, Beral V, Bull D, Crossley B, Goodill A, Green J, Hermon C, Key T, Langston N, Lewis C, Reeves G, Collins R, Doll R, Peto R, Mabuchi K, Preston D, Hannaford P, Kay C, Rosero-Bixby L, Gao YT, Jin F, Yuan JM, Wei HY, Yun T, Zhiheng C, Berry G, Cooper Booth J, Jelihovsky T, MacLennan R, Shearman R, Wang QS, Baines CJ, Miller AB, Wall C, Lund E, Stalsberg H, Shu XO, Zheng W, Katsouyanni K, Trichopoulou A, Trichopoulos D, Dabancens A, Martinez L, Molina R, Salas O, Alexander FE, Anderson K, Folsom AR, Hulka BS, Bernstein L, Enger S, Haile RW, Paganini-Hill A, Pike MC, Ross RK, Ursin G, MC Y, Longnecker MP, Newcomb P, Bergkvist L, Kalache A, Farley TM, Holck S, Meirik O, Collaborative Group on Hormonal Factors in Breast Cancer. Alcohol, tobacco and breast cancer—collaborative reanalysis of individual data from 53 epidemiological

- studies, including 58,515 women with breast cancer and 95,067 women without the disease. *Br J Cancer*. 2002;87(11):1234–45.
75. Chen WY, Rosner B, Hankinson SE, Colditz GA, Willett WC. Moderate alcohol consumption during adult life, drinking patterns, and breast cancer risk. *JAMA*. 2011;306(17):1884–90.
 76. Rosenberg L, Boggs DA, Bethea TN, Wise LA, Adams-Campbell LL, Palmer JR. A prospective study of smoking and breast cancer risk among African-American women. *Cancer Causes Control*. 2013;24(12):2207–15.
 77. Berrino F, Micheli A. Ormoni, fattori costituzionali, dieta e carcinoma mammario. *Attual Senol*. 2005;44:12–21.
 78. Kerlikowske K, Walker R, Miglioretti DL, Desai A, Ballard-Barbash R, Buist DS. Obesity, mammography use and accuracy, and advanced breast cancer risk. *J Natl Cancer Inst*. 2008;100(23):1724–33.
 79. Patel AV, Press MF, Meeske K, Calle EE, Bernstein L. Lifetime recreational exercise activity and risk of breast carcinoma in situ. *Cancer*. 2003;98(10):2161–9.
 80. Lin J, Cook NR, Albert C, Zaharris E, Gaziano JM, Van Denburgh M, Buring JE, Manson JE. Vitamins C and E and beta carotene supplementation and cancer risk: a randomized controlled trial. *J Natl Cancer Inst*. 2009;101(1):14–23.
 81. Boyd NF, Guo H, Martin LJ, Sun L, Stone J, Fishell E, Jong RA, Hislop G, Chiarelli A, Minkin S, Yaffe MJ. Mammographic density and the risk and detection of breast cancer. *N Engl J Med*. 2007;356(3):227–36.
 82. Gill JK, Maskarinec G, Pagano I, Kolonel LN. The association of mammographic density with ductal carcinoma in situ of the breast: the Multiethnic Cohort. *Breast Cancer Res*. 2006;8(3):R30.
 83. Hwang ES, Miglioretti DL, Ballard-Barbash R, Weaver DL, Kerlikowske K. Association between breast density and subsequent breast cancer following treatment for ductal carcinoma in situ. *Cancer Epidemiol Biomark Prev*. 2007;16:2587–93.
 84. Bertrand KA, Tamimi RM, Scott CG, Jensen MR, Pankratz V, Visscher D, Norman A, Couch F, Shepherd J, Fan B, Chen YY, Ma L, Beck AH, Cummings SR, Kerlikowske K, Vachon CM. Mammographic density and risk of breast cancer by age and tumor characteristics. *Breast Cancer Res*. 2013;15:R104.
 85. Hughes LL, Wang M, Page DL, Gray R, Solin LJ, Davidson NE, Lowen MA, Ingle JN, Recht A, Wood WC. Local excision alone without irradiation for ductal carcinoma in situ of the breast: a trial of the Eastern cooperative oncology group. *J Clin Oncol*. 2009;27:5319–24.
 86. Ernster VL, Barclay J, Kerlikowske K, Wilkie H, Ballard-Barbash R. Mortality among women with ductal carcinoma in situ of the breast in the population-based surveillance, epidemiology and end results program. *Arch Intern Med*. 2000;160:953–8.
 87. Bijker N. Breast-conserving treatment with or without radiotherapy in ductal carcinoma-in-situ: ten-year results of European organization for research and treatment of cancer randomized phase III trial 10853-a study by the EORTC breast cancer cooperative group and EORTC radiotherapy group. *J Clin Oncol*. 2006;24:3381–7.

Gian Marco Giuseppetti, Francesca Boria,
and Silvia Baldassarre

3.1 Introduction

The incidence of ductal carcinoma in situ (DCIS) has dramatically increased over the past few decades with the advent of widespread mammography screening and now accounts for over 20% of newly diagnosed cases of breast cancer in the United States [1].

DCIS is a heterogeneous disease process, ranging from low-grade lesions that are not life threatening to high-grade lesions that may harbor foci of invasive disease, with varied clinical manifestations and a broad spectrum of imaging findings.

In the majority (62–98%) of cases, DCIS is typically asymptomatic, nonpalpable, and incidentally discovered, due to the presence of calcifications at mammography [2, 3]. Clinical symptoms are reported in 10–24% of patients with DCIS and are more commonly seen in patients with noncalcified DCIS [4–6].

Early detection and delineation of DCIS involvement is important in selecting the appropriate therapy and determining prognosis.

DCIS may involve multiple foci within one or more breast lobules. Multicentricity is found in 8–33% of cases, with a probability that increases with tumor size [2, 7]. In 23–47% of cases, DCIS involves more than one quadrant [8, 9]. Frequently, DCIS occurs in conjunction with invasive cancer, either in the same lesion, in the same breast but in a different lesion, or on the contralateral side. This can significantly alter the course of treatment, from breast-conserving surgery to more extensive surgery or mastectomy.

G.M. Giuseppetti (✉)

Professor of Radiology, Chairman of Department S.C.O., Politecnica delle Marche University, Via Conca 71, 60126 Ancona, Italy
e-mail: g.m.giuseppetti@univpm.it

F. Boria • S. Baldassarre

Department of Diagnostic Radiology, AOU Ospedali Riuniti di Ancona, Politecnica delle Marche University, Via Conca 71, 60126 Ancona, Italy

It is known that the most important risk factors for disease recurrence are postexcision-positive margins and synchronous foci that were not removed [10, 11].

Preoperative underestimation of disease extent is not uncommon and can lead to inadequate excision and positive surgical margins. Reexcision is performed in up to 65% of cases of DCIS, typically in the setting of residual disease from positive or close margins, and the evaluation of mastectomy specimens shows 23% of DCIS to be multifocal [12].

Magnetic resonance (MR) imaging has proven to be more accurate than mammography in characterizing the extent of DCIS and in assessing for both ipsilateral foci of multicentric involvement and contralateral disease [13, 14]. Thus, MR imaging can be extremely useful in the preoperative diagnosis and evaluation of DCIS when used in conjunction with currently used imaging modalities.

Although DCIS is infrequently seen at ultrasonography (US) and its appearance is heterogeneous and nonspecific, US is a useful adjunct to mammography and MR imaging.

When calcifications are identified at mammography, US can be performed to evaluate for an invasive component and to allow possible US-guided biopsy [15, 16].

Noncalcified DCIS may also be detected as a mammographically occult palpable lesion, cause for nipple discharge, abnormality at screening US, or finding in the evaluation of disease extent.

Furthermore, US may help identify noncalcified DCIS in patients undergoing evaluation for an MR abnormality (MR imaging-directed (second-look) US), making possible US-guided core needle biopsy, which is better tolerated by the patient and more cost-effective than MR imaging-guided biopsy.

3.2 Mammographic Appearances of DCIS

The significant increase in the prevalence of DCIS since the early 1970s is mostly related to the increased use of mammographic screening, so mammography is the most important method for detecting DCIS [17, 18].

The vast majority (90%) of mammographically detected DCIS manifest as microcalcifications [2]. Calcifications may be amorphous, coarse heterogeneous, fine pleomorphic, or fine linear or fine linear-branching with a clustered, linear, or segmental distribution (Figs. 3.1, 3.2, 3.3, 3.4, 3.5, and 3.6). Around 75% of the time microcalcifications are the sole finding of DCIS, and about 15% of the time they are present along with a soft tissue abnormality (Fig. 3.7).

Less commonly, DCIS may also manifest as a mass at mammography in 10% of cases and as architectural distortion in 7–13% (Fig. 3.8) [3, 19].

A mass-like appearance of DCIS may be related to two different conditions: it may be a direct manifestation of an existing soft tissue mass or it may be a result of

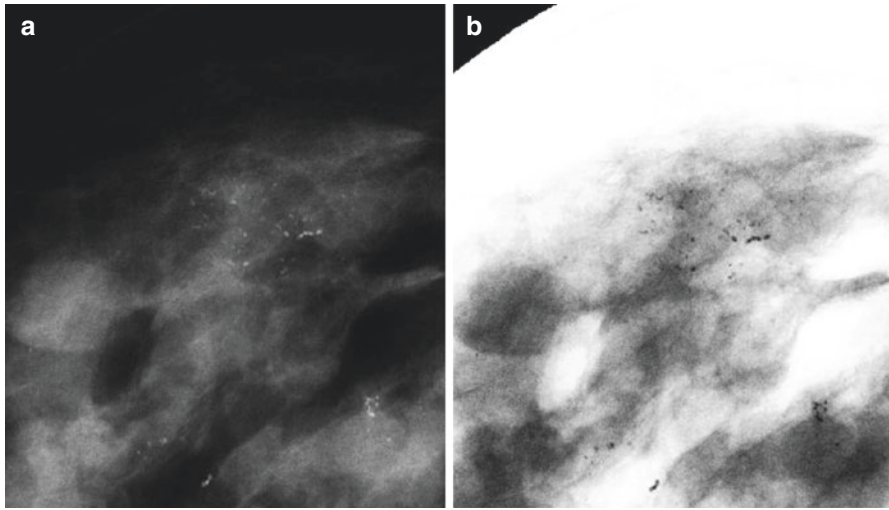


Fig. 3.1 Calcified grade 2 DCIS: craniocaudal spot magnification mammogram (a) and gray-scale reversed image (b) show a cluster of fine pleomorphic calcifications

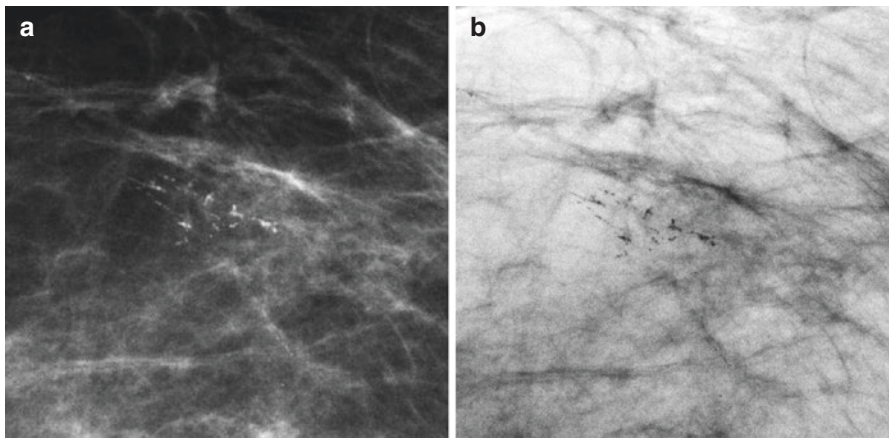


Fig. 3.2 Calcified grade 2 DCIS: craniocaudal spot magnification mammogram (a) and gray-scale reversed image (b) show a cluster of fine linear and pleomorphic calcifications

periductal fibrosis or elastosis producing an irregular or spiculated margin around a nonmass-like lesion.

Architectural distortion was noted in 7% of patients with sclerosing adenosis, which may have been the cause of this manifestation [20, 21]. Other pathologic conditions that may lead to architectural distortion include radial scarring and sclerosis in the interstitium around the DCIS and carcinomatous invasion of the Cooper's ligament [4].

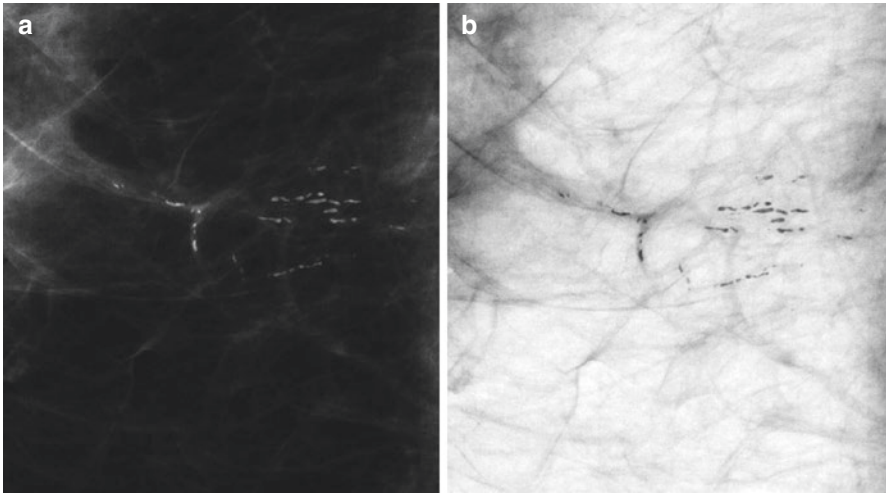


Fig. 3.3 Calcified grade 2 DCIS: craniocaudal spot magnification mammogram (a) and gray-scale reversed image (b) show fine linear calcifications with segmental distribution

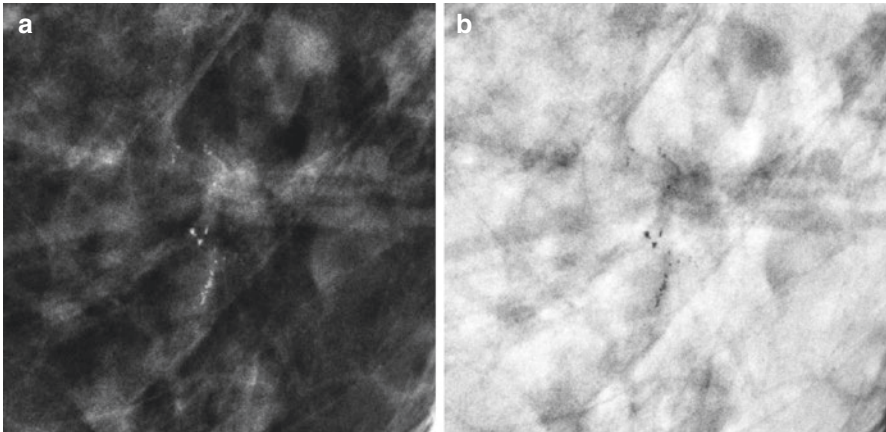


Fig. 3.4 Calcified grade 3 DCIS: craniocaudal spot magnification mammogram (a) and gray-scale reversed image (b) show a cluster of fine pleomorphic calcifications

Correlation studies between mammographic and histopathologic findings or grades of DCIS have shown that fine pleomorphic or fine linear and fine linear-branching calcifications seen in a grouped or segmental distribution are usually associated with higher-grade DCIS according to the World Health Organization (WHO) classification system (Figs. 3.4 and 3.5), whereas amorphous calcifications are associated with low-grade DCIS (Fig. 3.6) [18, 19, 22].

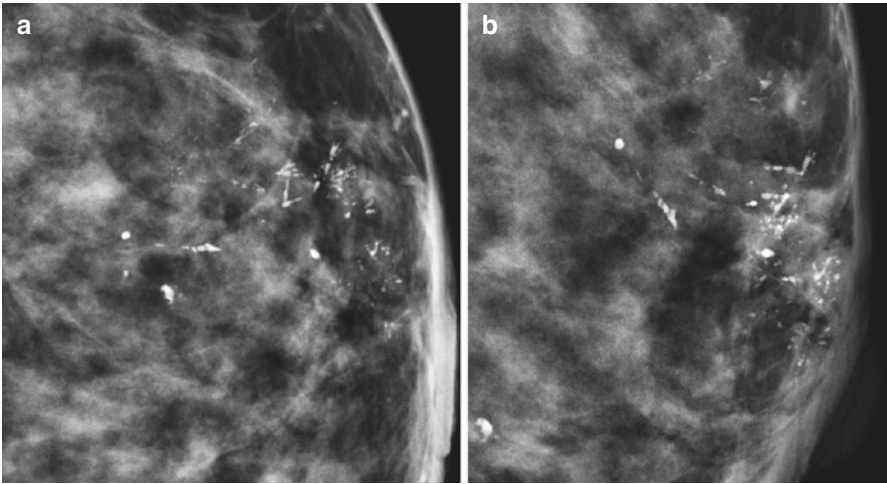


Fig. 3.5 Calcified grade 3 comedo-type DCIS: craniocaudal (a) and mediolateral oblique (b) spot magnification mammograms show a cluster of fine linear and fine linear-branching calcifications

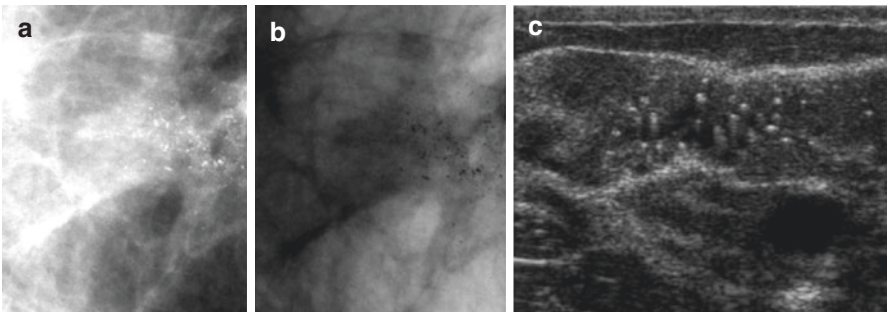


Fig. 3.6 Calcified grade 1 DCIS: craniocaudal spot magnification mammogram (a) and gray-scale reversed image (b) show a cluster of fine pleomorphic and amorphous calcifications. US image (c) shows echogenic foci consistent with calcifications

There is also a significant correlation between findings of fine pleomorphic or fine linear-branching calcifications and the presence of necrosis [23].

In addition, it was observed that low-grade DCIS lesions are more likely than lesions of higher grades to manifest as noncalcified abnormalities at imaging such as masses or asymmetries [19].

Despite these patterns, there is considerable overlap in the mammographic appearances of the different histologic subtypes of DCIS, and it has been shown that fine pleomorphic calcifications are the most common appearance for both

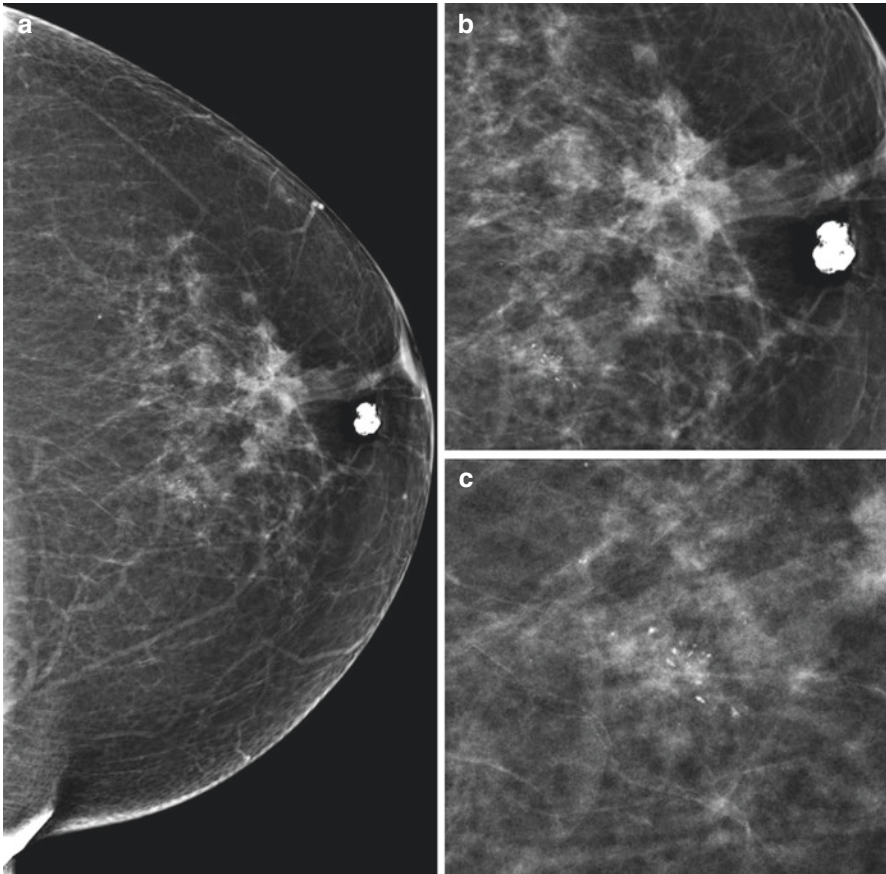


Fig. 3.7 Multifocal DCIS with necrosis and calcifications (grade 2): craniocaudal mammogram (a) and spot magnification mammograms (b, c) of the left breast show an area of architectural distortion and a contiguous focus of fine pleomorphic calcifications

high-grade and non-high-grade lesions [18, 22]. Thus, the histologic grade cannot be determined prospectively with any accuracy on the basis of the mammographic appearance of microcalcifications.

Although mammography, as the primary screening examination, is the main tool for detecting DCIS, it has some limitations. Because not all DCIS calcifies, the reported sensitivity of mammography ranges between 87 and 95% [18]. Disease extent is also frequently underestimated at mammography due to incomplete lesion calcification, which can result in additional operations such as surgical bed reexcision or completion mastectomy being performed to obtain negative margins.

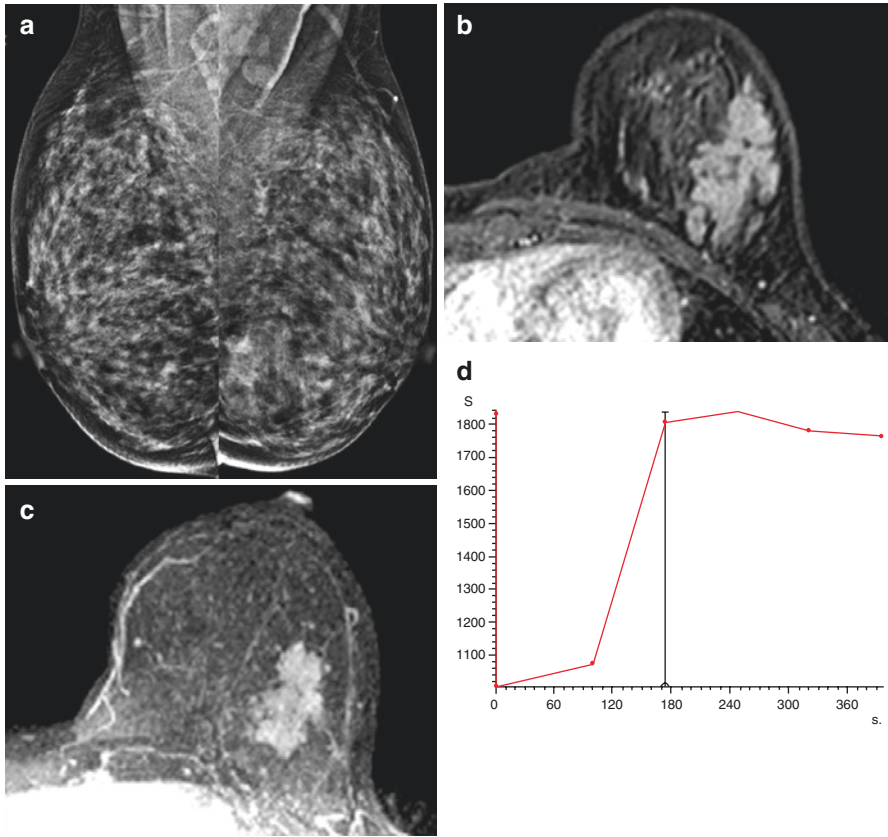


Fig. 3.8 Noncalcified grade 2 DCIS: mediolateral oblique mammogram (a) shows architectural distortion asymmetry in the lower part of the left breast, which corresponds on axial contrast-enhanced (b) and maximal intensity projection (c) MR images to a region of clumped nonmass-like enhancement. The kinetic curve of this lesion (d) demonstrates early enhancement with plateau (type 2 kinetics)

3.3 MR Imaging Appearances of DCIS

MR imaging is the most sensitive modality available for identifying DCIS and is more accurate than mammography in evaluating the extent of disease [24–26]. It does allow the visualization of mammographically occult DCIS lesions, likely because of its ability to demonstrate tumor vascularity, vessel density, and permeability.

The sensitivity of MR imaging for detection of DCIS has been shown to be higher for high-grade and intermediate-grade DCIS as compared with low-grade DCIS (98%, 91%, and 80%, respectively). Overall, MR imaging is more sensitive than mammography in the detection of all grades of DCIS (92% vs. 56%, respectively) [13].

Most studies have shown that MR imaging provides either an accurate assessment or overestimation of DCIS disease extent compared with the pathologic evaluation. Although DCIS may be underestimated at MR imaging, underestimation occurs less frequently than it does at mammography [27]. The sensitivity of MR imaging in the accurate assessment of the extent of DCIS reaches almost 89%, compared with 55% at mammography and 47% at US [26, 28]. Thus, the results of the MR imaging evaluation can alter the course of treatment of DCIS by allowing correct identification of the extent of disease.

MR imaging can allow improved presurgical planning of the known cancer as well as depict additional foci of multifocal or multicentric DCIS and contralateral disease. It can be used to better delineate the margins of the disease before surgery, which theoretically may decrease the frequency with which positive margins occur. Nevertheless, the COMICE (comparative effectiveness of MR imaging in breast cancer) trial has not shown any reduction in the reexcision rate with the use of pre-operative MR imaging; thus, its use in this setting remains controversial [29].

3.3.1 Morphologic Features of DCIS

DCIS may have variable morphologic features on MR images, with “nonmass enhancement” (NME) morphology being the most common manifestation (60–81% of cases) [24, 30–32]. Less commonly, DCIS may also manifest as a mass (14–41% of cases) on dynamic contrast material-enhanced MR images, in which case it is most likely to be irregular, or as a focus (1–12%) (Table 3.1).

Different morphologic features have been seen in DCIS lesions of different nuclear grades. However, no statistically significant difference has been seen between the morphologic features and nuclear grades of DCIS. Thus, there is no morphologic feature predictive of the nuclear grade of pure DCIS [30, 32].

DCIS is usually not visible on non-contrast material-enhanced T1-weighted images or on nonfat-saturated or fat-saturated T2-weighted images because it is masked by the normal breast parenchyma. DCIS may sometimes appear bright on T2-weighted images because of either ductal secretions or necrosis.

NME DCIS can manifest with various internal enhancement patterns, the most common of which is a clumped pattern (41–64% of cases) (Figs. 3.8 and 3.9), followed by a heterogeneous pattern (16–29%) [24, 30–32]. Less frequently, DCIS can manifest as reticular/dendritic enhancement (0–9% of cases), as well as clustered ring enhancement (Table 3.2).

Table 3.1 Morphologic features of DCIS by nuclear grade [24]

Nuclear grade	Focus (%)	Mass (%)	NME (%)
High	0–62.5	54.5–56	25–72.2
Intermediate	18.8–66.6	31.3–33.3	0–50
Low	0	11.1–50	0–50

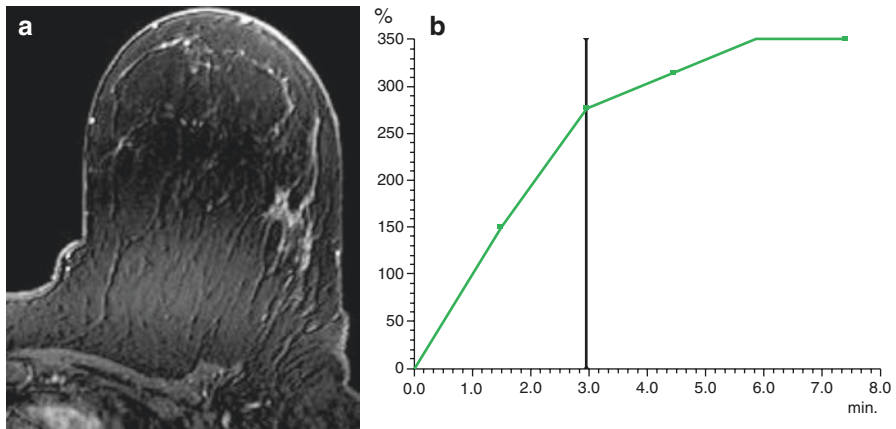


Fig. 3.9 Noncalcified DCIS: axial contrast-enhanced MR image (a) shows a segmental area of clumped NME in the outer part of the left breast. The lesion demonstrated persistent (type 1) kinetics (b)

Table 3.2 NME DCIS internal enhancement patterns [24]

Internal enhancement pattern	BI-RADS definition	Portion of time seen in NME DCIS (%)
Clumped	Cobblestone-like enhancement, with occasional confluent areas	41–64
Heterogeneous	Nonuniform enhancement in a random pattern	16–29
Homogeneous	Confluent uniform enhancement	0–16
Reticular, dendritic ^a	Enhancement with fingerlike projections extending toward the nipple	0–9
Stippled, punctate	Punctate, similar-appearing, enhancing foci, sandlike or dotlike	0–8
Clustered ring enhancement	Cluster of small ring enhancement	... ^b

^aThis terminology is no longer used in the most recent BI-RADS lexicon

^bNew BI-RADS term; no data available at current time

Clustered ring enhancement, a term in the new MR imaging BI-RADS (Breast Imaging Reporting and Data System) lexicon, represents periductal enhancement and is the result of contrast material pooling in the periductal stroma or ductal wall of DCIS. This pattern was seen in 63% of malignant lesions, compared with only 4% of benign lesions [33].

There are several different NME distribution patterns. Segmental or linear/ductal enhancement patterns are a hallmark of DCIS on MR images. Segmental distribution is the most common pattern, seen in 14–77% of cases [24, 30–32]. Regional asymmetric enhancement is another frequent appearance of DCIS (Table 3.3).

Table 3.3 NME DCIS distribution patterns [24]

NME distribution	BI-RADS definition	Portion of time seen in NME DCIS (%)
Segmental	Triangular region of enhancement, apex pointing to the nipple, suggesting a duct or its branches	14–77
Linear	Enhancement in a line that may not conform to a duct	6–24
Ductal ^a	Enhancement in a line that may have branching, conforming to a duct	0–22
Focal	Enhancement in a confined area, less than 25% of a quadrant	16–33
Regional	Enhancement in a large volume of tissue not conforming to a ductal distribution geographic	6–28
Diffuse	Enhancement distributed uniformly throughout the breast	1–9

^aThis terminology is no longer used in the most recent BI-RADS lexicon

Table 3.4 Mass DCIS internal enhancement patterns [24]

Internal enhancement pattern	BI-RADS definition	Portion of time seen in mass DCIS (%)
Heterogeneous	Nonspecific mixed enhancement	9–67
Homogeneous	Confluent uniform enhancement	9–25
Rim enhancement	Enhancement more pronounced at the periphery of the mass	0–8

DCIS manifests as a mass on MR images in 14–41% of cases [13, 24, 30, 31]. A mass is defined as a three-dimensional space-occupying lesion. Masses are further characterized by their shape, margin, and internal enhancement pattern.

DCIS manifests most frequently as an irregular mass, seen in 14–83% of cases [24, 30, 32]. Oval, round, and lobular masses are less commonly noted, with 1–25%, 0–25%, and 0–25% frequency, respectively, as described in the literature. Various types of mass margins have been described, including irregular (14–92% of cases) and spiculated (0–92%). Smooth mass margins are uncommon, observed in 4–8% of cases. DCIS that manifests as a mass can have various internal enhancement patterns, including heterogeneous, homogenous, and rim enhancement. A heterogeneous enhancement pattern is the most common (9–67% of cases), followed by homogenous (9–25%) and rim (0–8%) enhancement (Table 3.4).

A focus is defined as a region of enhancement that is small (<5 mm) and may not allow confident further characterization. DCIS is least likely to manifest as a focus, although this finding may represent selection bias, because the vast majority of cases in which foci of enhancement are observed do not proceed to biopsy. According to the literature, pure DCIS manifests as a focus up to 12–20% of cases, while a focal enhancing area was observed in only 3.0% of cases of pure invasive carcinoma. Most of these foci were high-grade or intermediate-grade lesions rather than low-grade lesions [24, 31].

3.3.2 Kinetic Characteristics of DCIS

Various kinetic patterns have been seen in DCIS lesions detected on MR images [24]. BI-RADS lexicon defines the initial phase as the curve that develops within 2 min or when the shape of the kinetic curve begins to change, and the delayed phase is defined as the curve that develops after 2 min or after the kinetic curve changes. The initial phase is described as fast, medium, or slow, and the delayed phase is described as persistent, plateau, or washout. The curves may also be classified into type 1 (persistent), type 2 (plateau), and type 3 (washout). Quantitative kinetic parameters can also be derived from the curves, including initial enhancement percentage (E1), peak enhancement percentage (Epeak), and time-to-peak enhancement (Tpeak); these quantitative parameters may aid in lesion characterization.

In DCIS, the most common initial phase is fast uptake, which is seen in 49–68% of cases [24, 30, 34]. The delayed phase is more variable, with a plateau curve being the most common pattern (Fig. 3.8), seen in 20–52% of cases, followed by washout (28–44%) and persistent enhancement (20–30%) (Fig. 3.9).

In DCIS cases in which there is a high density of ducts, an abundance of blood vessels, and a high degree of inflammatory cell infiltration, there is a rapid washout pattern; this pattern is most often seen in cases of high-grade DCIS. Low-grade DCIS more often shows a benign blood flow pattern [18, 35]. Nevertheless, no individual kinetic parameter neither qualitative nor quantitative has been demonstrated to predict DCIS grade [18, 30].

It has been shown, however, that the qualitative enhancement patterns do differ significantly according to lesion type. Mass DCIS lesions more often exhibit rapid uptake of contrast medium in the initial phase and rapid washout compared with nonmass lesions [36]. This observation is in keeping with the literature that shows that both benign and malignant mass lesions have a higher proportion of curves with rapid initial uptake and washout delayed phase compared with nonmass and focal lesions. Calcified DCIS with fine pleomorphic, fine linear, and fine linear-branching calcifications more often demonstrate a plateau enhancement pattern, while DCIS with amorphous calcifications usually exhibit persistent enhancement [18, 30].

3.4 US Appearance of DCIS

The ultrasonographic (US) features of DCIS can be subtle and nonspecific. DCIS can have a variable appearance at US: a mass, an intraductal abnormality, or an area of altered echotexture. But it most commonly appears as a hypoechoic mass with noncircumscribed margins, parallel orientation, ductal extension, and normal acoustic transmission [37].

Calcified DCIS most commonly manifests as echogenic foci located within a mass or duct, associated with internal microlobulations, or distributed in a branch pattern [15, 38, 39].

Noncalcified DCIS, which is more often identified in symptomatic patients, may manifest as a hypoechoic mass with microlobulated margins and no posterior acoustic features, or it may have a “pseudomicrocystic” appearance [5, 6, 40, 41].

The appearance of DCIS at “second-look” US can be subtle and may warrant a lower threshold for detection, given a higher pretest probability of malignancy [42]. US features are nonspecific, and careful correlation with respect to lesion location, size, shape, and depth is needed [43–45]. The presence of internal vascularity can help increase the positive predictive value of US in this setting.

3.4.1 Calcified DCIS

US can help identify 23–45% of calcifications seen at mammography [16, 37–39]. Mammographic features that are most predictive of US identification include large cluster size (>10 mm), a large number of calcifications within the cluster, BI-RADS category 5 assessment, and segmental distribution of calcifications.

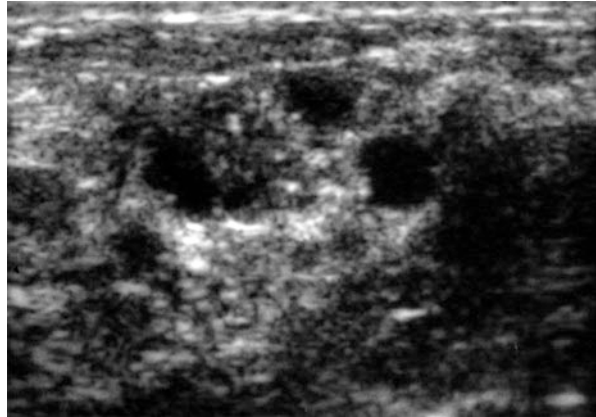
Calcifications may be visualized at US as echogenic foci located within a mass or duct, associated with internal microlobulations, or distributed in a branch pattern [15, 37–39]. Less frequently, calcifications may appear as echogenic regions without significant mass or duct changes (Fig. 3.6). There is considerable overlap between the US appearance of calcified DCIS and that of benign entities such as sclerosing adenosis, atypical ductal hyperplasia, intraductal papilloma, fibroadenoma, and ductal epithelial hyperplasia.

When calcified DCIS manifests as a mass, it is typically hypoechoic and irregularly shaped, with indistinct or microlobulated margins [15, 37]. Microlobulations may correspond to tumor-distended ducts or cancerized lobules. Echotexture may be heterogeneous secondary to the presence of calcifications. There may be associated internal vascularity. Ductal extension, seen as a projection extending radially from the mass into a duct, may be present and represents ductal spread of cancer cells. No posterior acoustic features are typically identified, except in cases of high-grade comedo-type DCIS (Fig. 3.10), in which shadowing may be present. Orientation may be parallel or antiparallel.

Although US is not as sensitive as mammography for the detection of calcifications, it can be used to increase the specificity of mammography [16, 37, 38]. Calcifications seen at US are more than three times more likely to be malignant than calcifications not seen at US. The presence of an associated mass increases the conspicuity of calcifications and confers a greater likelihood of invasive cancer compared with calcifications seen at mammography alone. Calcifications are more common in high-grade than non-high-grade DCIS and can be seen with calcification of necrotic debris in comedo-type necrosis [46]. It has been found that microcalcifications with associated ductal changes, such as an increase in the number of ducts and duct distention, are the most common US finding of high-grade DCIS.

Increased breast density may obscure an underlying invasive component at mammography, and US may show that disease is more extensive than the calcifications evident at mammography. In addition, in the setting of extensive high-nuclear-grade

Fig. 3.10 Calcified comedo-type DCIS: US image demonstrates a mass that is predominantly cystic with solid components and echogenic foci consistent with calcifications



DCIS, in which histologic sampling is more likely to miss microscopic foci of invasive disease, US can be used to assess the axillary lymph nodes for evidence of invasion [15].

When calcifications are identified at mammography, US can also be performed to guide potential biopsy [16]. US-guided biopsy is better tolerated and less costly than stereotactic biopsy and does not involve ionizing radiation [47, 48]. Identification of a US correlate for US-guided biopsy can also be useful when stereotactic biopsy is not technically feasible due to a thin breast or posterior target location. Real-time scanning also allows visualization of large adjacent vessels, which can be avoided to reduce hematoma formation.

3.4.2 Noncalcified DCIS

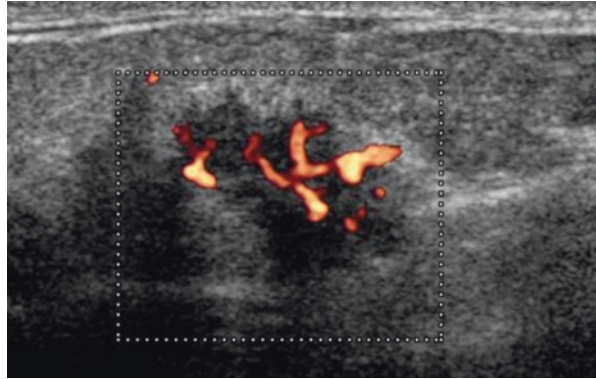
Noncalcified DCIS may be identified in the evaluation of a mammographic mass or asymmetry, in symptomatic patients, at high-risk screening US, or in the evaluation of disease extent.

Although DCIS is much less likely to be identified at screening US than is invasive carcinoma, US has proved to be an important adjunct to mammography in the evaluation of asymptomatic high-risk women, particularly of those with dense breasts [49, 50].

DCIS detected at US alone is often localized and low grade, whereas calcified DCIS is more commonly high grade [41].

US findings of noncalcified DCIS are heterogeneous [5, 6, 37, 40, 41]. Masses are often hypoechoic and irregular in shape (Fig. 3.11), but they can also be oval or round. Margins are often microlobulated or indistinct, although circumscribed margins may also be seen. Orientation may be parallel or antiparallel. There is usually no posterior acoustic enhancement or shadowing. Ductal extension may be present. A complex echotexture, giving a “pseudomicrocystic” appearance, may also be present and is hypothesized to be caused by distention of the lobular portion of the

Fig. 3.11 Noncalcified DCIS: power Doppler US image shows an irregular hypoechoic mass with microlobulated and angular margins and internal vascularity



terminal ductal lobular unit by DCIS. Occasionally, a vague area of altered echotexture may be seen. Because DCIS may also arise in preexisting pathologic entities such as papillomas or radial scars, the underlying US abnormality may be an intraductal mass or area of distortion.

When noncalcified DCIS manifests as a cluster of cysts or a complex cystic mass, there may be associated internal vascularity, often oriented perpendicular rather than parallel to the wall of the mass. This is in contrast to clusters of cysts, which are typically avascular at color Doppler US [51]. Only light pressure should be applied to avoid restricting blood flow during color or power Doppler evaluation. A new mass mimicking clustered microcysts, especially in a postmenopausal patient, should also raise concern for possible DCIS [40]. Any solid component should prompt biopsy for further evaluation [51, 52].

Noncalcified DCIS may also be detected in the evaluation of nipple discharge. An abnormal number of ducts from neoductgenesis or an abnormal appearance of ducts may be present. Enlargement of ducts in DCIS can be attributed to tumor cells or necrosis within the duct lumen, periductal lymphocytic reaction, or periductal desmoplasia [5, 15]. The degree of duct enlargement is typically proportional to nuclear grade.

The US appearance of noncalcified DCIS overlaps with that of benign entities including fibrocystic change, microcysts, apocrine metaplasia, papillary duct hyperplasia, adenosis, and secretory change [15].

Elastography, which indicates tissue stiffness by measuring tissue strain or displacement with mechanical excitation, can be used in the US evaluation of noncalcified DCIS. In general, cancers tend to be stiff, whereas benign lesions tend to be soft. Several studies have reported a lower mean elasticity for DCIS (Fig. 3.12) than for invasive carcinoma [53–55]. However, given the overlap in elasticity values for benign and malignant lesions, elastography should be used only in conjunction with B-mode US. The addition of elastography to B-mode feature analysis can increase the specificity of US by prompting biopsy for oval circumscribed malignant masses with suspicious features at elastography while downgrading a mass with a low degree of suspicion for malignancy (category 4a) to category 3 in the presence of benign elastographic features.

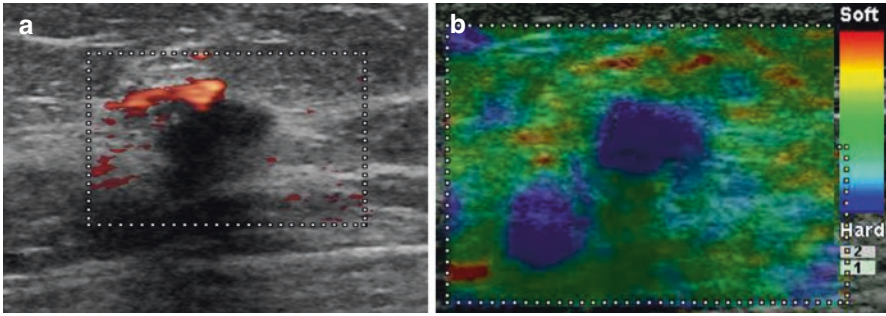


Fig. 3.12 Noncalcified DCIS: power Doppler US image (a) demonstrates a hypoechoic mass with microlobulated and angular margins and antiparallel orientation and that is poorly vascularized. The lesion appears diffusely stiff on shear-wave elastographic image (b)

3.4.3 DCIS Diagnosed at MR Imaging: Directed (Second-Look) US

The US correlate for abnormal MR imaging enhancement representing DCIS may be subtle [37].

US performed in the setting of an MR abnormality allows possible US-guided core needle biopsy, which is better tolerated by the patient and more cost-effective than MR imaging-guided biopsy.

Since the pretest probability of malignancy for a US finding in the setting of suspicious MR imaging enhancement is significantly higher, especially in patients with a known malignancy, a lower threshold should be used at second-look US than at conventional diagnostic or screening US [42].

Several studies have reported that malignant lesions seen at MR imaging are more likely to be identified at US than are their benign counterparts [42–45].

Although second-look US can be used to identify MR imaging-detected malignant lesions, it is better at detecting a correlate for enhancing masses than nonmass enhancement, the most common enhancement type in DCIS [42–45]. The rate of correlation between US and MR imaging for nonmass enhancement is low, with a reported range of 12–40%. Invasive cancers (either ductal or lobular) had a higher US correlation rate than DCIS. Therefore, if no US correlate is identified for a suspicious area of nonmass enhancement, MR imaging-guided biopsy should be performed.

The appearance of DCIS at second-look US is dependent on the type of enhancement identified at MR imaging [42–45]. Masses seen at MR imaging may correspond to a mass or intraductal abnormality or appear as “stacked” ducts at US. US correlates for nonmass enhancement include ductal abnormalities, vague areas of decreased echogenicity or altered echotexture, or areas of architectural distortion.

Correlation in terms of lesion location, depth, size, and shape is necessary to ensure that the US finding corresponds to the area of enhancement seen at MR imaging.

References

1. Virnig BA, Tuttle TM, Shamlivan T, Kane RL. Ductal carcinoma in situ of the breast: a systematic review of incidence, treatment, and outcomes. *J Natl Cancer Inst.* 2010;102(3):170–8.
2. Dershaw DD, Abramson A, Kinne DW. Ductal carcinoma in situ: mammographic findings and clinical implications. *Radiology.* 1989;170(2):411–5.
3. Stomper PC, Connolly JL, Meyer JE, Harris JR. Clinically occult ductal carcinoma in situ detected with mammography: analysis of 100 cases with radiologic-pathologic correlation. *Radiology.* 1989;172(1):235–41.
4. Ikeda DM, Andersson I. Ductal carcinoma in situ: atypical mammographic appearances. *Radiology.* 1989;172(3):661–6.
5. Cho KR, Seo BK, Kim CH, et al. Non-calcified ductal carcinoma in situ: ultrasound and mammographic findings correlated with histological findings. *Yonsei Med J.* 2008;49(1):103–10.
6. Kim JH, Ko ES, Kim Y, Han H, Sohn JH, Choe H. Noncalcified ductal carcinoma in situ: imaging and histologic findings in 36 tumors. *J Ultrasound Med.* 2009;28(7):903–10.
7. Lagios MD, Westdahl PR, Rose MR. The concept and implications of multicentricity in breast carcinoma. *Pathol Annu.* 1981;16(pt 2):83–102.
8. Faverly DR, Burgers L, Bult P, Holland R. Three dimensional imaging of mammary ductal carcinoma in situ: clinical implications. *Semin Diagn Pathol.* 1994;11(3):193–8.
9. Holland R, Hendriks JH, Vebeek AL, Mravunac M, Schuurmans Stekhoven JH. Extent, distribution, and mammographic/histological correlations of breast ductal carcinoma in situ. *Lancet.* 1990;335(8688):519–22.
10. Holland R, Connolly JL, Gelman R, et al. The presence of an extensive intraductal component following a limited excision correlates with prominent residual disease in the remainder of the breast. *J Clin Oncol.* 1990;8(1):113–8.
11. Sinn HP, Anton HW, Magener A, von Fournier D, Bastert G, Otto HF. Extensive and predominant in situ component in breast carcinoma: their influence on treatment results after breast-conserving therapy. *Eur J Cancer.* 1998;34(5):646–53.
12. Harris EE, Schultz DJ, Jones HA, Solin LJ. Factors associated with residual disease on re-excision in patients with ductal carcinoma in situ of the breast. *Cancer J.* 2003;9(1):42–8.
13. Kuhl CK, Schrading S, Bieling HB, et al. MRI for diagnosis of pure ductal carcinoma in situ: a prospective observational study. *Lancet.* 2007;370(9586):485–92.
14. Berg WA, Gutierrez L, Ness-Aiver MS, et al. Diagnostic accuracy of mammography, clinical examination, US, and MR imaging in preoperative assessment of breast cancer. *Radiology.* 2004;233(3):830–49.
15. Stavros AT. US of ductal carcinoma in situ. In: Silverstein MJ, editor. *Ductal carcinoma in situ of the breast.* 2nd ed. Philadelphia: Lippincott, Williams & Wilkins; 2002. p. 128–69.
16. Soo MS, Baker JA, Rosen EL. Sonographic detection and sonographically guided biopsy of breast microcalcifications. *AJR Am J Roentgenol.* 2003;180(4):941–8.
17. Allegra CJ, Aberle DR, Ganschow P, et al. Diagnosis and management of ductal carcinoma in situ (DCIS). *NIH Consens State Sci Statements.* 2009;26(2):1–27.
18. Yamada T, Mori N, Watanabe M, et al. Radiologic-pathologic correlation of ductal carcinoma in situ. *Radiographics.* 2010;30(5):1183–98.
19. Barreau B, de Mascarel I, Feuga C, et al. Mammography of ductal carcinoma in situ of the breast: review of 909 cases with radiographic-pathologic correlations. *Eur J Radiol.* 2005;54(1):55–61.
20. Sekine K, Tsunoda-Shimizu H, Kikuchi M, Saida Y, Kawasaki T, Suzuki K. DCIS showing architectural distortion on the screening mammogram: comparison of mammographic and pathological findings. *Breast Cancer.* 2007;14(3):281–4.
21. Günhan-Bilgen I, Memiş A, Ustün EE, Ozdemir N, Erhan Y. Sclerosing adenosis: mammographic and ultrasonographic findings with clinical and histopathological correlation. *Eur J Radiol.* 2002;44(3):232–8.

22. Hofvind S, Iversen BF, Eriksen L, Styr BM, Kjellevoid K, Kurz KD. Mammographic morphology and distribution of calcifications in ductal carcinoma in situ diagnosed in organized screening. *Acta Radiol.* 2011;52(5):481–7.
23. Stomper PC, Connolly JL. Ductal carcinoma in situ of the breast: correlation between mammographic calcification and tumor subtype. *AJR Am J Roentgenol.* 1992;159(3):483–5.
24. Greenwood HI, Heller SL, Kim S, Sigmund EE, Shaylor SD, Moy L. Ductal carcinoma in situ of the breasts: review of MR imaging features. *Radiographics.* 2013 Oct;33(6):1569–88.
25. Mossa-Basha M, Fundaro GM, Shah BA, Ali S, Pantelic MV. Ductal carcinoma in situ of the breast: MR imaging findings with histopathologic correlation. *Radiographics.* 2010;30(6):1673–87.
26. Menell JH, Morris EA, Dershaw DD, Abramson AF, Brogi E, Liberman L. Determination of the presence and extent of pure ductal carcinoma in situ by mammography and magnetic resonance imaging. *Breast J.* 2005;11(6):382–90.
27. Marcotte-Bloch C, Balu-Maestro C, Chamorey E, et al. MRI for the size assessment of pure ductal carcinoma in situ (DCIS): a prospective study of 33 patients. *Eur J Radiol.* 2011;77(3):462–7.
28. Shiraishi A, Kurosaki Y, Maehara T, Suzuki M, Kurosumi M. Extension of ductal carcinoma in situ: histopathological association with MR imaging and mammography. *Magn Reson Med Sci.* 2003;2(4):159–63.
29. Turnbull L, Brown S, Harvey I, et al. Comparative effectiveness of MRI in breast cancer (COMICE) trial: a randomised controlled trial. *Lancet.* 2010;375(9714):563–71.
30. Jansen SA, Newstead GM, Abe H, Shimauchi A, Schmidt RA, Karczmar GS. Pure ductal carcinoma in situ: kinetic and morphologic MR characteristics compared with mammographic appearance and nuclear grade. *Radiology.* 2007;245(3):684–91.
31. Rosen EL, Smith-Foley SA, DeMartini WB, Eby PR, Peacock S, Lehman CD. BI-RADS MRI enhancement characteristics of ductal carcinoma in situ. *Breast J.* 2007;13(6):545–50.
32. Chan S, Chen JH, Agrawal G, et al. Characterization of pure ductal carcinoma in situ on dynamic contrast-enhanced MR imaging: do non high grade and high grade show different imaging features? *J Oncol.* 2010;2010:431341.
33. Tozaki M, Igarashi T, Fukuda K. Breast MRI using the VIBE sequence: clustered ring enhancement in the differential diagnosis of lesions showing non-masslike enhancement. *AJR Am J Roentgenol.* 2006;187(2):313–21.
34. Vag T, Baltzer PA, Dietzel M, et al. Kinetic characteristics of ductal carcinoma in situ (DCIS) in dynamic breast MRI using computer-assisted analysis. *Acta Radiol.* 2010;51(9):955–61.
35. Van Goethem M, Schelfout K, Kersschot E, et al. Comparison of MRI features of different grades of DCIS and invasive carcinoma of the breast. *JBR-BTR.* 2005;88(5):225–32.
36. Kim JA, Son EJ, Youk JH, et al. MRI findings of pure ductal carcinoma in situ: kinetic characteristics compared according to lesion type and histopathologic factors. *AJR Am J Roentgenol.* 2011;196(6):1450–6.
37. Wang LC, Sullivan M, et al. US appearance of ductal carcinoma in situ. *Radiographics.* 2010;33(1):213–28.
38. Moon WK, Im JG, Koh YH, Noh DY, Park IA. US of mammographically detected clustered microcalcifications. *Radiology.* 2000;217(3):849–54.
39. Yu PC, Lee YW, Chou FF, et al. Clustered microcalcifications of intermediate concern detected on digital mammography: ultrasound assessment. *Breast.* 2011;20(6):495–500.
40. Mesurrolle B, El-Khoury M, Khetani K, Abdullah N, Joseph L, Kao E. Mammographically non-calcified ductal carcinoma in situ: sonographic features with pathological correlation in 35 patients. *Clin Radiol.* 2009;64(6):628–36.
41. Izumori A, Takebe K, Sato A. Ultrasound findings and histological features of ductal carcinoma in situ detected by ultrasound examination alone. *Breast Cancer.* 2010;17(2):136–41.
42. Abe H, Schmidt RA, Shah RN, et al. MR-directed (“second-look”) ultrasound examination for breast lesions detected initially on MRI: MR and sonographic findings. *AJR Am J Roentgenol.* 2010;194(2):370–7.

43. Meissnitzer M, Dershaw DD, Lee CH, Morris EA. Targeted ultrasound of the breast in women with abnormal MRI findings for whom biopsy has been recommended. *AJR Am J Roentgenol*. 2009;193(4):1025–9.
44. LaTrenta LR, Menell JH, Morris EA, Abramson AF, Dershaw DD, Liberman L. Breast lesions detected with MR imaging: utility and histopathologic importance of identification with US. *Radiology*. 2003;227(3):856–61.
45. Spick C, Baltzer PA. Diagnostic utility of second-look US for breast lesions identified at MR imaging: systematic review and meta-analysis. *Radiology*. 2014;273(2):401–9.
46. Park JS, Park YM, Kim EK, et al. Sonographic findings of high-grade and non-high-grade ductal carcinoma in situ of the breast. *J Ultrasound Med*. 2010;29(12):1687–97.
47. Liberman L, Feng TL, Dershaw DD, Morris EA, Abramson AF. US-guided core breast biopsy: use and cost-effectiveness. *Radiology*. 1998;208(3):717–23.
48. Rubin E, Mennemeyer ST, Desmond RA, et al. Reducing the cost of diagnosis of breast carcinoma: impact of ultrasound and imaging-guided biopsies on a clinical breast practice. *Cancer*. 2001;91(2):324–32.
49. Kolb TM, Lichy J, Newhouse JH. Occult cancer in women with dense breasts: detection with screening US—diagnostic yield and tumor characteristics. *Radiology*. 1998;207(1):191–9.
50. Crystal P, Strano SD, Shcharynski S, Koretz MJ. Using sonography to screen women with mammographically dense breasts. *AJR Am J Roentgenol*. 2003;181(1):177–82.
51. Berg WA, Sechtm AG, Marques H, Zhang Z. Cystic breast masses and the ACRIN 6666 experience. *Radiol Clin North Am*. 2010;48(5):931–87.
52. Berg WA. Sonographically depicted breast clustered microcysts: is follow-up appropriate? *AJR Am J Roentgenol*. 2005;185(4):952–9.
53. Itoh A, Ueno E, Tohno E, et al. Breast disease: clinical application of US elastography for diagnosis. *Radiology*. 2006;239(2):341–50.
54. Evans A, Whelehan P, Thomson K, et al. Differentiating benign from malignant solid breast masses: value of shear wave elastography according to lesion stiffness combined with greyscale ultrasound according to BI-RADS classification. *Br J Cancer*. 2012;107(2):224–9.
55. Berg WA, Cosgrove DO, Doré CJ, et al. Shear-wave elastography improves the specificity of breast US: the BE1 multinational study of 939 masses. *Radiology*. 2012;262(2):435–49.

Carlo Mariotti, Eugenia Raffaeli, Enrico Lenti,
Marco Gentili, Silvia Baldassarre,
and Gian Marco Giuseppetti

4.1 Introduction

Interventional radiology is a branch of radiology that includes all invasive procedures or minimally invasive diagnostic and therapeutic techniques performed using radiological guidance (ultrasound, fluoroscopy, computed tomography, and magnetic resonance imaging). Its goal is to achieve results equal to, or better than, the corresponding surgery, with less risk, fewer complications, and lower costs. It is an emerging discipline in many fields and often is indispensable in the diagnostic and therapeutic/surgical phases.

Breast imaging is reserved for lesions that pose a diagnostic dilemma or remain unsolved with conventional diagnostic imaging, or for programming a therapeutic intervention or surgery. The increased experience of radiologists in breast diagnostics, technological developments, and the ability to use dedicated equipment has led to the identification of a large number of breast lesions of small dimensions, whose type is not always easy to define. For example, malignant disease at an early stage or early after injury, or that of borderline pathology, must be differentiated from benign disease, either cytologically (percutaneous fine-needle cytology from 21 to 27 G, clinical pathology, fine-needle aspiration cytology [FNAC]) and/or histologically by percutaneous biopsy (PB) with needles sizes between 8 and 20 G or surgical biopsy. The different collection methods must be properly placed and used in the diagnostic process, so it is essential to become familiar with the information they provide, their limitations, and possible complications.

C. Mariotti (✉) • E. Raffaeli

Department of Oncology and Robotic Surgery, Breast Surgery Unit, AOU Careggi, Firenze, Italy
e-mail: mariotticarlo@alice.it; eugenia.raffaeli@gmail.com

E. Lenti • M. Gentili

Department of Surgery, Breast Surgery Unit, Ospedali Riuniti University Hospital, Ancona, Italy

S. Baldassarre • G.M. Giuseppetti

Department of Radiology, Ospedali Riuniti University Hospital, Ancona, Italy

In parallel to the increase in the detection of nonpalpable lesions, the frequent diagnosis of tumors in the pre-invasive phase has led to a search in the surgical field for less invasive interventions that more often require a precise location of the lesion and its extension. This is achieved through close cooperation between radiologists, nuclear medicine physicians, surgeons, and pathologists in the multidisciplinary management of a patient.

Minimally invasive interventional radiology procedures with curative or palliative purposes have recently been used in senology and other sectors when treating malignant tumors (percutaneous treatment with radiofrequency technology, using lasers and focused ultrasound, etc.) and have delivered interesting and promising results, although for only a limited number of properly selected cases.

4.2 Percutaneous Cytology

FNAC was developed more than a century ago and has long been used in the diagnostic workup of breast lesions because it is fast, is minimally invasive, and provides adequate sensitivity and low costs [1, 2]. Even when perfectly executed, however, cytological examination has up to a 5–10% rate of false negatives [3], due to the exact target localization, the pathologist's experience correctly classifying benign cases with very different morphologies, and the heterogeneity of the neoplastic architecture, as the collection can be sampled from areas of fibrosis, necrosis, fat, or normal tissue. However, eco-mammography/cytological embedded data have been shown to possess a very low percentage of diagnostic error that, in the case of test concordance, presents false negatives in approximately 1% [4–7]. Positive cytology is in principle a very specific relief, and the rate of false positives is considered irrelevant: <1% (FNAC specificity = 99%) [4, 7], mostly due to the poor quality or quantity of the extracted material. The limits of this technique stem from the inability, when cytological sampling is positive, to differentiate in situ forms from infiltrating forms, and the evaluation of the biological parameters of the neoplasm.

Cytology can be performed under mammographic stereotactic guidance (currently fall into disuse) or ultrasound (US) that is generally preferred when the lesion is sonographically visible, for it is low-cost, fast, and offers high-precision sampling that is well tolerated by patients [8, 9]. Using stereotactic imaging, a breast lesion can be located in a three-dimensional space (coordinates x , y , and z) by means of a double-exposure stereotactic mammography obtained by tilting the arm of the tube and measuring the position of the lesion on two mammograms on a prone patient (alternatively she can be sitting on dedicated equipment). The stereotactic guidance is used in case of lesions visible only on mammography, such as areas of distortion, small opacities, or focus of microcalcifications. When considering the high number of inconclusive samples with cytological examination, it is preferable and recommended, cost and time being similar, to use larger needles in modality core-biopsy or vacuum biopsy.

Complications are extremely rare if the method is successful and are mostly due to bleeding (hematoma and bruising), which occurs more frequently in areas where the **breast** is richer in superficial venous structure. Generally, these complications are resorbed in a few days. Pneumothorax, on the other hand, is a serious but extremely rare complication that affects one case per 10,000 biopsies [1, 2, 9].

Prerequisites for accurate cytological diagnosis are the close cooperation of operators (radiologist and pathologist) for proper targeting of the lesion and the experience and expertise of the pathologist in handling the extracted material and preparing cytologic samples representative of the lesion.

4.2.1 Collection Technique

The method of sampling for cytological examination is relatively simple, although it requires training and experience. The procedure can be performed using only a needle with a caliber from 21 to 27 G and variable length in relation to the depth of the lesion and by exploiting the lift by capillarity of the material. Alternatively, the needle can be connected to a common disposable syringe (20 mL), mounted on gun device type CAMECO, performing manual aspiration or by connecting the needle with suction devices with vacuum pump that allow a greater operating freedom. Typically 22–23 G needles are used that, due to their larger gauge, consent the collection of a greater quantity of material (even if some authors prefer to use lower-gauge needles (25–27 G)), which guarantee the collection of sufficient material and are suitable for the diagnosis in a more practical, less traumatic, and quicker way. As already stated, ultrasound guidance is always preferred compared with radiological stereotactic guidance, if the lesion is visible by ultrasound, because it is faster, simpler to execute, less expensive, absent of ionizing radiation, more flexible, with a smaller percentage of inadequate samples, and better tolerated by the patient.

As for the ultrasound examination, the patient is positioned supine, and the collection is performed taking the taut skin of the breast between thumb and forefinger to immobilize the area of interest and prevent the formation of tunnel due to loss of contact probe-cute at the time of the introduction of the needle. This, in addition to facilitating the introduction of the needle, decreases the blood supply, which in turns lowers the risk of inducing hemorrhage.

The sampling should be performed with the needle inside the lesion by performing rapid and multiple inward and outward movements associated with rotations, under constant instrumental guidance, to ensure a representative sample is collected. Finally, it is important to take good care of interrupting the suction before removing the needle.

The needle is introduced by the customer in “free hand” going in the direction of the lesion with perpendicular or oblique approach. With the perpendicular approach, the needle is inserted at the midpoint of the probe placed perpendicularly onto the lesion that is visualized in the center of the scan. In relation to the depth of the lesion, the path of the needle will have a defined angle, which can be corrected in real time. With this access, only the tip of the needle appears, in the form of a point

echogenicity, when it intersects the field of view at the level of the lesion. The perpendicular approach is undoubtedly fast, well-sited for superficial or deep lesions, and requires no special accessories but undoubtedly requires solid experience.

The oblique approach, for which special adapters can be used with different angles, is more favorable than the previous one, because the needle can be visualized along its path in the breast toward the target. The transducer is positioned so that the lesion appears next to the lateral margin. The needle, inserted in the vicinity of this margin, is directed with different obliquity in relation to the seat of the target to the field of view, where it is immediately identified and followed along the path to the lesion. The most important limitation of this approach is the impossibility to reach very superficial lesions. The oblique approach is more difficult than the perpendicular one, because the path is decidedly longer than the needle. However, when executed with special kits, it is easier and less operator-dependent, therefore, preferable at the beginning for operators with limited experience and most suitable for cytology of deep lesions near the chest wall [1, 2, 8, 9].

4.2.2 Cytological Diagnostic Conclusions

The results of cytology may be available after a few hours, with a report that must be clear and include a diagnostic conclusion as suggested by the “European Guidelines” (Table 4.1).

4.2.3 Indications

Despite its inherent limitations, the cytology when performed by a team of experts (radiologist, pathologist), it may still play a role, if properly placed in the diagnostic workup of breast diseases, in determining the benign or malignant lesions [10]. The choice of the lesions to be biopsied is crucial, giving careful consideration to possible alternative diagnostic tools. In particular, this technique should be preferred in lesions characterized by liquid component and/or necrosis phenomenon

Table 4.1 Reporting system of breast cytology

C1	Finding inadequate for a diagnostic judgment; the cause shall be indicated (little or no cellularity, artifacts unsuitable equipment, etc...)
C2	Negative finding for malignant cells; sometimes specific diagnoses can be formulated (e.g., fibroadenoma)
C3	Doubt findings; the lesion is benign, but probably the presence of some atypia indicates the need for further investigation (e.g., histological biopsy)
C4	Suspicious findings; the lesion is probably malignant, the cytologic features are suggestive but not diagnostic of malignancy (e.g., lesions “borderline” or low-grade ductal carcinomas)
C5	Finding malignant; the cytologic features are diagnostic of malignancy, where possible indicate the G Nuclear and reported the presence or absence of microcalcifications

(complicated cysts, papillomatous lesions) [11] or localized in the particularly difficult areas (axillary, close proximity to the chest wall, the presence of breast implants adjacent).

Performing a biopsy under mammography guidance, with a stereotactic device, is reserved for lesions not visible by ultrasound, and it is, at present, less frequently used and even abandoned as, in cases of distortion of the drawing breast radial scar and microcalcifications (typical lesions best or only evident with mammography) is imperative to proceed by core biopsy or vacuum-biopsy. For the limits of FNAC related to the high percentage of inadequate (C1 2–30%), the high percentage of false negatives (5–20%), the high number of equivocal results (C3), and the inability to positive cases to evaluate the biological parameters of the tumor and to differentiate the forms in situ from those invasive, it is appropriate in most cases recourse to percutaneous biopsy. The continuation of the diagnostic with the use of percutaneous biopsy also is required in all cases of discrepancies between results of cytology and conventional imaging and in cases of equivocal (C3) to cytology, whereas the positive predictive value for carcinoma in cases C3 is 20% (in fact, some malignant lesions are more often adjustable as C3: tubular carcinoma, well-differentiated ductal carcinoma, lobular carcinoma, and ductal carcinoma, as well as some benign lesions are more often related to C3: fibrocystic, fibroadenoma, and adenosis injury) [12].

4.3 Percutaneous Biopsy

Percutaneous biopsy (PB), performed by ultrasound or stereotactic guide needle size between 8 and 20 G, is currently the most appropriate method for the characterization of histological lesions and therefore is widely used in clinical practice to replace surgical biopsy. The small number of malignant lesions diagnosed in the final histopathological examination combined with considerable problems with surgical biopsies (high costs and stress for the patient; sometimes need to use general anesthesia, postoperative risks, such as infection, thrombosis, and embolism; scars; crowding operating rooms) have prompted the research of more cost-effective interventional techniques that are less invasive and able to get a satisfactory answer to the histological diagnosis and for planning treatment or therapeutic-surgical follow-up.

Recently, new systems have come into use that are increasingly sophisticated, easy and rapid to apply, and that allow, albeit with more complex procedure than cytology, to extract frustules of tissue sufficient for precise and complete histologic diagnosis of the lesion, which make possible adequate planning of therapeutic treatment with a consequent reduction in the number of surgical biopsies and ultimately costs. PB allows both histological and biological characterization of the lesion, thus defining aggression and appearance receptor (ER, PgR, Ki-67, C-erb B-2) [13–16].

There are several types of percutaneous biopsy depending on the type of needle that is used [2, 9, 17]:

- **Core Needle Biopsy** or biopsy needles shot, semiautomatic type TRU-CUT, guillotine gauge between 14 and 20 G that allow you to make multiple microhistological withdrawals from the suspected area;
- **Vacuum Biopsy (VB)** or biopsy with aspiration technique, which through gauge needles between 8 and 14 G, allow large mammary withdrawals with a single access.

No method of percutaneous biopsy is 100% accurate, even with very high sensitivity values, 95/97%, compared with 90% of percutaneous cytology [13–16]. The diagnostic capacity depends on the type of lesion (node or calcification), the diameter of the needle used (from 14G to 18G), and the amount of tissue (number of frustules) taken. Moreover, it has to be considered that 10–30% of microhistologically diagnosed carcinoma in situ is associated with foci of invasiveness discovered during the subsequent surgery. This further limits the difficulty of interpreting morphologically complex but benign diseases (atypical epithelial hyperplasia, injury sclero-elastosica or radial scar), which require for their characteristics and their possible association with foci of ADH or DCIS, excisional biopsy surgery [18–21].

Percutaneous biopsy, according to major scientific societies, is indicated in many cases, particularly in assessing [22]:

- Lesions considered highly suggestive or suspicious for malignancy (BIRADS category 4 and 5), to confirm the diagnosis and guide the definitive treatment;
- Lesions with multicentric distribution to facilitate the planning of the treatment;
- Lesions assessed as probably benign (BIRADS category 3), only when there are valid clinical indications, in particular in the diagnosis of fibroadenoma (greater diagnostic confidence of benign lesion which relieves the patient's stress);
- Lesions undiagnosed after FNAC (C1 and C3, the discrepancy between the radiologist and pathologist);
- Injuries characterized by the discrepancy between cytologic findings and clinical signs;

The use of PB also is recommended (given the paucity of material obtainable with FNAC and the high number of inadequate results) when dealing with suspicious lesions characterized by calcification and breast and radial distortions of the drawing-scar. In particular, several authors suggest using vacuum biopsy in cases of calcification to possibly take a greater quantity of material and open biopsy when dealing with the distortions of the drawing breast and the radial-scar [20, 21].

Percutaneous biopsy, generally performed as outpatient or day-hospital under (optional) local anesthesia, can be performed under ultrasound guidance, stereotactic, or magnetic resonance imaging, depending on the visibility and instrumental characteristics of the lesion.

4.3.1 Preliminary Evaluation

Before performing the biopsy, the available clinical indications must be evaluated: profiles of technical feasibility, considering the BIRADS of the target lesion, and the outcome of global imaging techniques, including mammography, echography, and mammary magnetic resonance.

It is of particular relevance that a written, informed consent is obtained and that the document contains a brief description of the procedure and includes a note that details the option of leaving a small, nonmagnetic clip (from the stereotactic guide) and the expected duration of the procedure. Moreover, it is important that the expected results and available alternatives to the biopsy are clearly stated, suggesting that this procedure has been shown to deliver a high percentage of accurate diagnoses. Finally, the risks associated with this procedure must be described, in particular the rather rare complications, typically hemorrhagic in nature, as well as short-lived neck and back discomfort due to the particular body position that must be held for several minutes during the procedure.

The general evaluation of the patient is key: in particular, the pharmacological treatment with anti-coagulant and anti-aggregant drugs must be suspended with standard methodology; and the ability of the patient to hold a supine position (for the echographic guide) or prone (for the stereotactic table) for a long enough time.

It is good practice to place a cannula on the arm that is not used for the biopsy to keep a venous access open in case complications arise during the procedure or just to satisfy standard ambulatory procedures.

4.3.2 US Breast Biopsy

When the lesion can be located through echography, this should be the method of choice to guide the intervention, because it is cheaper, more practical, simpler, and faster (3–10 min); moreover, it offers the ability to locate the needle in real-time within the lesion, as already listed for the case of the echo-guided cytological biopsy [8].

The preferred types of needle for this procedure include: Tru-cut, semiautomatic, and snap types (tip + drawer histological and shirt must be activated with two clicks imprinted on the handle by the operator) [2, 9].

The procedure is as follows: having ensured sterile conditions, the appropriate choice of needle gauge (14–20 G), and under a regime of local anesthesia, a small skin incision is performed, which facilitates the crossing of the cutaneous layer, and the needle is inserted with the tip facing the lesion. The needle path is visualized on the echography monitor (keep the probe at either 45° or parallel), and the needle is arrested when it is facing (or it has penetrated) the target lesion. We extract the guillotine (to be able to follow the progress inside the lesion), it triggers the shirt, thus cutting the carrot tissue, and pull the needle with the frustule intact inside (Fig. 4.1).

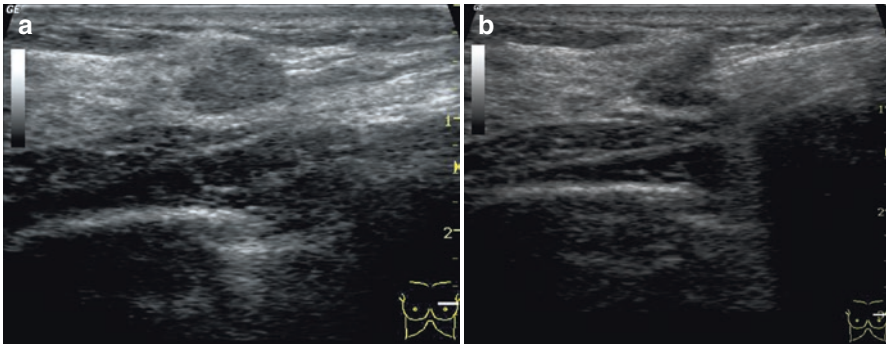


Fig. 4.1 Nodular area, hypoechoic multilobulated contours (BIRADS 3, cytology C3) (a). Extraction technique microhistology with TRU-CUT (histology: fibroadenoma) (b)

This procedure is generally repeated three to six times from different orientations, so that enough tissue might be gained from different regions of the lesion. The extracted samples must be fixed in formalin. At the end of the procedure, it is advisable to press manually onto the interested region for several minutes to minimize the risk of bleeding and hematoma formation. It is not necessary to suture the skin incision, but a sterile-strep type of medication and ice treatment can suffice. The dressing can be removed the next day.

Adopting a similar procedure, a tissue sample can be obtained with a vacuum-assisted biopsy (VAB), employing needles with larger gauge (8 and 14 G), through which multiple samples can be obtained from a single access point. Moreover, in the case of a benign pathology, the same procedure can be adopted for the complete vacuum-assisted percutaneous removal of the mammarian lesion. It can be considered as a viable alternative to all surgeries for lesions smaller of centimeters, that did not result in “atypia” of the core-biopsy, but that are candidates for complete removal.

This procedure can be performed in the echographic room, and it is generally better accepted from patients, because of the absence of scars and because it does not requires an operating room. Also, it is generally much cheaper. Complications similar to the “open surgery” alternative are possible [23].

Once the target has been identified, a local dosage of anesthetic is delivered between the skin and the lesion and “a ventaglio” around the lesion. At that point, a small skin incision (3–4 mm) is realized and the VAB needle introduced. It is preferable to position the needle below the lesion, which is then explored in a layer-by-layer fashion. Once the removal is complete, as assessed by a real-time echography, a nonmagnetic clip can be placed.

4.3.3 Stereotactic Breast Biopsy

Stereotactic breast biopsy is an interventional radiology method for the localization, sample extraction, and, in selected cases, removal of a breast lesion that is clinically

nonpalpable but has a mammographic readout. It is based on a geometrical argument, for which a pair of two-dimensional images incident at a known angle (typically 30°) can be processed to determine the localization of a given feature, such as a lesion, in a three-dimensional space (with coordinates x, y, z).

It is currently used mostly in digital mammography, where the radiographic film is replaced by a detector that transduces incident x-rays into electronic signals that can be digitized and operated on using a computer. From these data, an image can be reconstructed, so-called digital mammography, which is then visualized on a high-definition monitor. Once the lesion is spatially localized, the sample-taking system allows the precise positioning of needles and the extraction of histological samples for diagnostic purposes.

4.3.4 Procedure

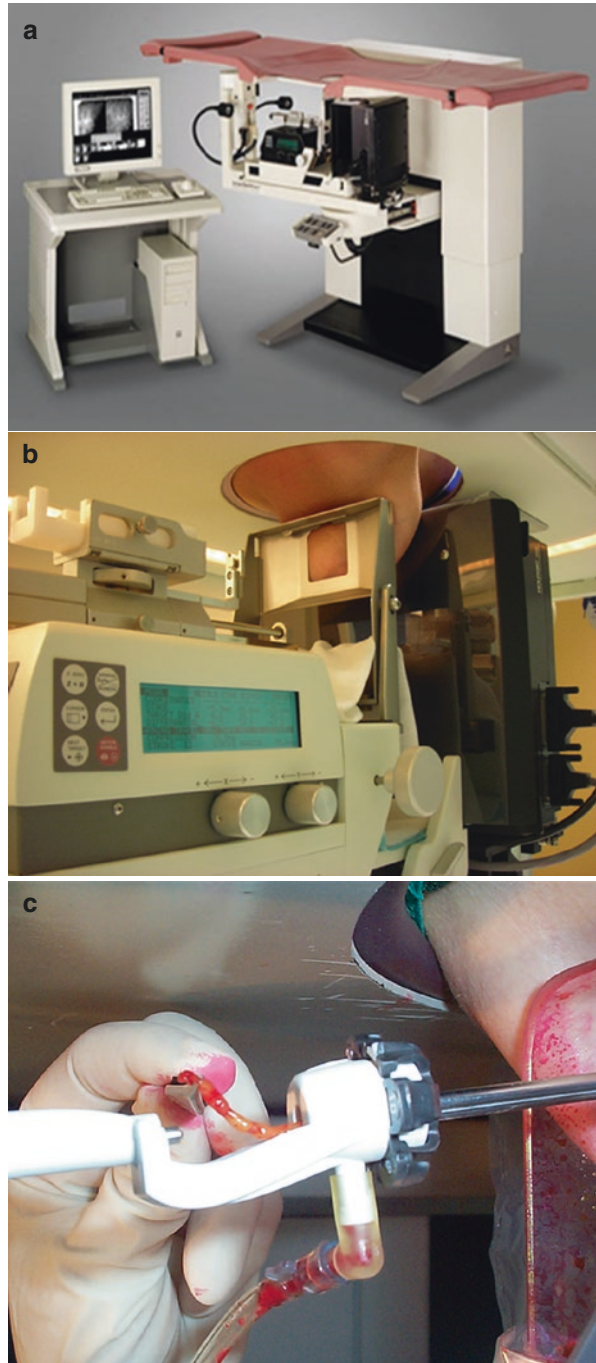
Having acquired a mammography standard image, which can be cranial-caudal, oblique, or lateral depending on the visibility and the location of the lesion, a stereotactic pair of images can be acquired. The images should be angled between them of 30° ($+15$ and -15 compared with the standard image). The location of the lesion is then manually identified in each image before a computational algorithm evaluates the tridimensional coordinates of the lesion. Under local anesthesia, a needle can be inserted to extract the tissue sample. X-ray images of the extracted samples are acquired and analyzed to select the most significant ones for further pathological classification, such as those containing microcalcification or dense breast tissue. Finally, the extracted samples are fixed using formalin and sent to the pathologist along with a form that specified patient personal information, clinical question, the radiological suspicion, and the possibility of a biological characterization.

4.3.5 Extractions Systems

This method can be performed with the adaptive systems placed on normal mammograms (patient sitting in front of the machine) or with dedicated stereotactic table (Fig. 4.2). The latter case, against a higher cost, allows to work with the patient prone, with operational area outside the visual field of the patient and allows to have an access to the udder to 360° .

The stereotactic table is a table consists of an ergonomically shaped, height-adjustable, padded surface on which the patient lies prone. A circular opening of diameter of approximately 25 cm allows the breast to protrude in the operational area, located below the table top. Under the table, an arm to “C” supports the x-ray tube and the collimator spherical $+15^\circ$ and -15° for the acquisition of the stereotactic images. A second arm to “C” provides the support to the compression plate of the breast and to the pointing device that received the stereotactic coordinates, driving on the lesion the operating instrumentation. The characteristics of the various tables

Fig. 4.2 Stereotactic table and console work (a). Positioning of the patient and mammographic detection of the lesion (b). Tissue sample to be examined (c)



and the possibility of positioning the patient allows to follow in most cases the shortest route between the skin and the lesion of the breast (Fig. 4.2).

4.3.6 Instruments

The stereotactic biopsy history began with the ABBI system (Fig. 4.3) (Advanced Breast Biopsy Instrument) in the early 1990s, whose goal was the complete removal of the mammary LNP. Trocars ranging from 5 to 20 mm were utilized to perform an excisional biopsy of the lesion with local anesthesia providing very little advantages over a surgical biopsy, which requires an operating room.

In the spring of 1993, four radiologists (Burbank, Parker, Brody, Zerhouni) and a surgeon (Thomas J. Fogarty) developed the MAMMOTOME, a dedicated system for stereotactic breast biopsy [17]. On August 5, 1994, the first stereotactic biopsy was performed.

The MAMMOTOME was the ancestor of a series of systems built around an aspiration unit (vacuum biopsy) and an operating window positioned lateral to the needle tip and a diameter ranging between 12 and 7 G. Using MAMMOTOME instead of ABBI systems, the lesion is not removed as a monolithic unit but rather it is divided and removed in pieces. This is important, because it leads to reduced trauma and much improved tolerability.

The procedure is typically performed in Day Hospital. Once the lesion and the needle insertion point are located, a local anesthetic is administered by infiltration to skin and target. Then, a 3- to 4-mm skin incision is performed and the needle introduced (Fig. 4.2). After centering the target, the tissue is ready to be extracted (Fig. 4.4). The radiological control of the operating region and of the extracted samples permits real-time quality control over the entire procedure (Fig. 4.4). The typical duration of the procedure is approximately 20 min.

Another commonly adopted technique is the core-biopsy, in which tissue extraction is performed with needles snap, with gauges greater than 1 mm (18–8 G) (Fig. 4.5). In this technique, a series of repetitive extractions consent a tissue-map of the breast. This procedure, which is less invasive, better tolerated, and more versatile of the vacuum-biopsy types, unfortunately tends to underestimate the lesions type. Limitations of the core biopsy include reduced amount of material in adipose breasts, presence of fragmented tissues or noncontiguous samples, the need for multiple reintroductions, and a general tendency to underestimate microcalcifications.

At the end of the procedure, it is important to perform a control mammography to prove the effective removal of the target and to evaluate the breast clinically to rule out hemorrhages and hematoma. If those are present, first perform manual compression, followed by mechano-compressive after a few minutes, and finally, if necessary, apply compression with tenso-plast. A simple sterile-strip medication is applied to the needle point of entry.

Fig. 4.3 ABBI cannula (a).
Sample with ABBI (b).
X-ray sample ABBI (c)

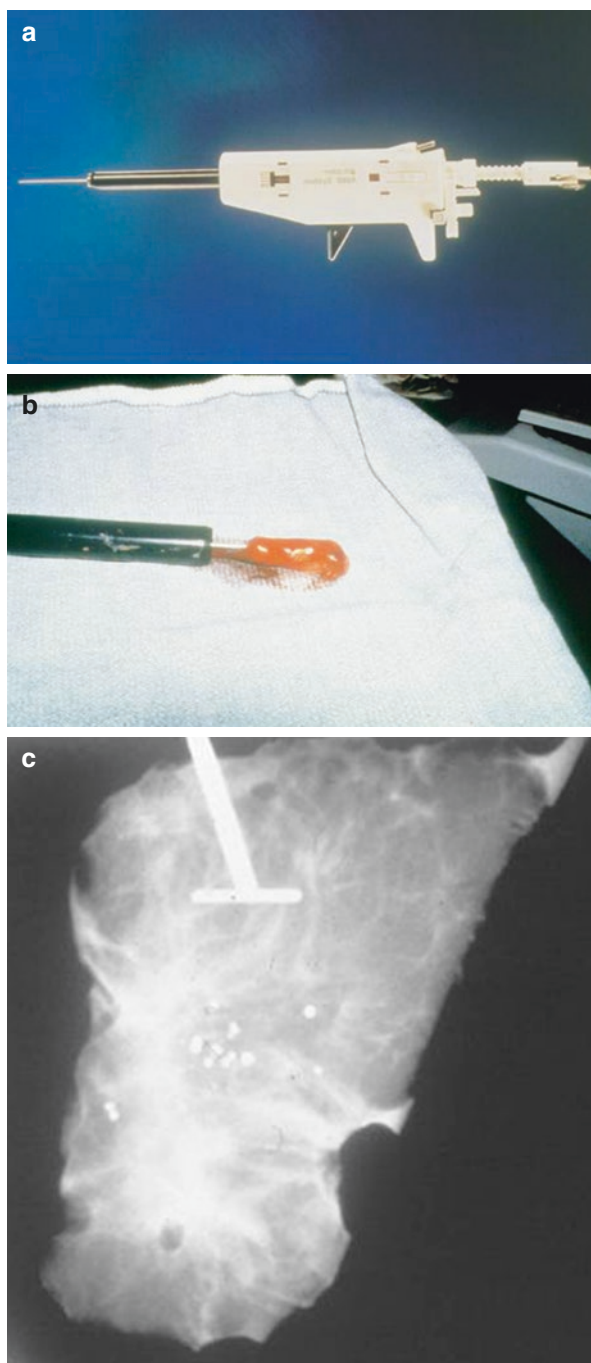


Fig. 4.4 Breast at the end of the procedure (a). Rx control (b). Rx control: microcalcifications (c)


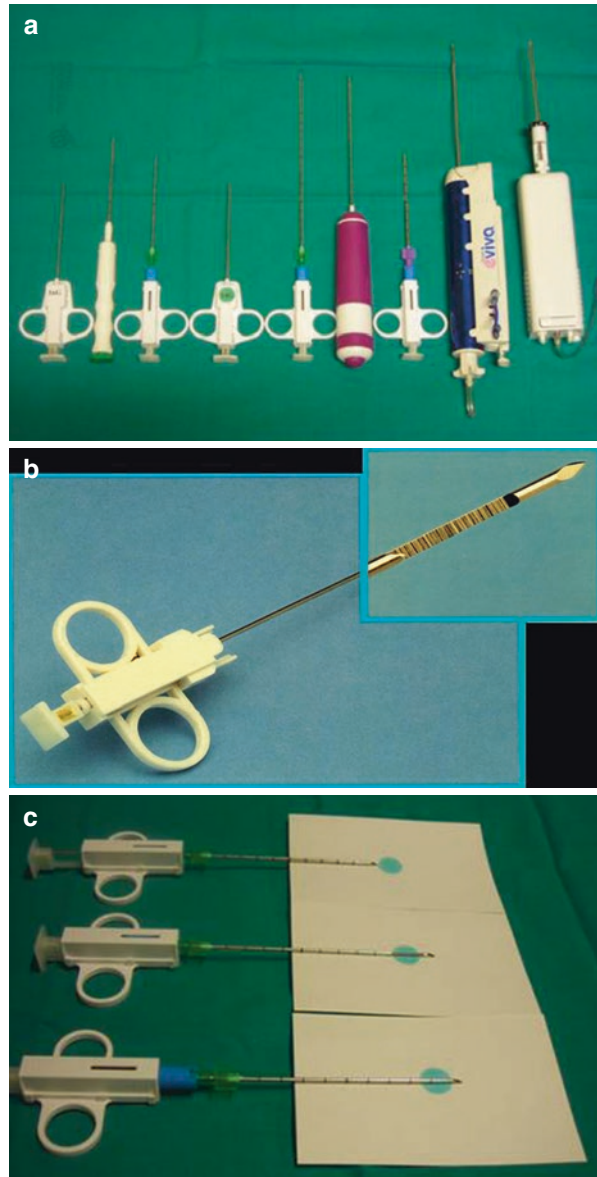


Fig. 4.5 Breast needles biopsy of different gauges. On the left needle mechanism “snap” to the right VABB (vacuum-assisted breast biopsy) system (a). Needle core biopsy from 14 G, details of the sampling window (b). On Aug pick mechanism “snap” in three movements: placing it in front of the lesion (c needle bottom), discharge from the spindle with window sampling in the lesion (c center needle), execution of the collection (c needle in the foreground)



4.3.7 Magnetic Resonance-Guided Breast Biopsy

As magnetic resonance (MR) became the imaging technique of choice in senology, due to unparalleled diagnostic sensitivity (95–99%), lesions have been noticed that can be detected with MR but not with echography or mammography [2, 24]. Interpreting a novel breast lesion, characterized using either morphological or dynamical criteria during an MR session, is difficult due to the high rate of false-positive detections that may

occur even when the procedure is perfectly executed. When a lesion is first detected with MR, and presents itself with concerning characteristics, it is necessary to confirm it in a “second-look” traditional imaging session and then proceed to extract a sample using either the echographic or mammographic-guided biopsy techniques discussed earlier. If a lesion cannot be confirmed with traditional imaging, then the biopsy must be performed under magnetic resonance guidance despite increased difficulties, execution times, and costs [25–28].

This technique requires ad-hoc instrumentations, including a dedicated support, or open coil, which permits the positioning of a compression and localization system, such as “Universal Grid” or “Post & Pillar” through which the biopsy needle can be introduced. Notably, the needle needs to be made of a material that is compatible with strong magnetic fields. Nonmagnetic coaxial needles are inserted and under MR guidance, either manually or through CAD (computer-assisted detection), localized to a lesion that was previously detected with basic examination or after mdc ev administration. Through the coaxial needles, cutting needles are introduced (14–16 G) or greater caliber VAB needles (11–8 G). After the extraction, it is good practice to leave radiopaque clips or echo-reflecting in the place of the lesion, which can be later recognized via traditional imaging techniques [24, 26].

The patient needs to be adequately informed of the possible MR contraindications, including paramagnetic contrast agent, and possible complications, such as bleeding or the presence of a needle close to the chest wall. Moreover, the patient must be able and willing to remain prone for the duration of the examination (approximately 45 min).

4.3.8 Sample Handling for the Pathologist

Typically, four frustules must be extracted for a diagnosis of neoplasia to be treated with primary systemic therapy PST (number of frustules correlates with \emptyset of neoplasia). The samples must then be immediately fixed with neutral-buffered formalin 4% (pH 6.8–7.2) for 6–48 h. The request for histological examination must be accompanied with full clinical information (including the intention of treating with PST when the neoplasia is locally advanced) and a copy of the mammography (or echography) report containing the time of the examination, the characteristics of the detected lesion, its location and dimensions, the Bi-RADS category, and the number of extracted samples. If microcalcifications are detected, the frustules containing them must be identified on the postextraction radiograph and sent in separate marked containers. The quality of the material must be described along with the length of the biggest frustule. Each container holds two to three frustules at max. For each inclusion, four sections are obtained at two different levels (approximately each 50 μ m) and stained with hematoxylin-eosin.

The pathologist can require further sectioning of the samples if there is inconsistency between the clinical inquiry and the report of the pathologist (particularly for microcalcifications). Moreover, the presence of microcalcifications can be confirmed through additional x-ray scanning of the samples.

Table 4.2 Conclusion diagnostic histological type (NHS Breast Screening Programme)

B1	Normal tissue. May indicate that the lesion was not sampled properly or that there is a benign lesion, such as lipoma or hamartoma characterized by normal glandular tissue
B2	Benign lesion. This category includes fibroadenoma, the many paintings of fibrocystic disease, sclerosing adenosis, ductal ectasia, and inflammatory processes, such as fat necrosis and abscess
B3	Lesions uncertain. Malignant potential are included in this category; pathological conditions, such as ductal epithelial hyperplasia and/or atypical lobular, papillary lesions, radial scar, and phyllodes tumor
B4	Suspected lesion. Included those pictures in which the definitive histologic diagnosis of carcinoma in situ or invasive cannot be made with certainty or for problems mainly of necrotic or for example when there are apparently neoplastic cells in the context of a blood clot
B5	Neoplastic lesion. Includes cases of carcinoma in situ and invasive carcinoma. The diagnosis of carcinoma in situ in PB does not exclude the presence of invasive carcinoma of the limited sample

4.3.9 Medical Reporting

The pathologist report must contain a full diagnosis of the detected lesions and their eventual relationship with microcalcifications (distinguishable in intraluminal and stromal) and the specification of the category B (NHS Breast Screening Programme) (Table 4.2). It also must contain, in a dedicated session, the clinical information that was given in the request for the histological exam. When a carcinoma is diagnosed, the following must be specified: in situ/invasive, extent of infiltrating foci, histological type, nuclear grade.

Biomarkers (ER, PgR, Ki67, HER-2) are not routinely evaluated. Their evaluation is performed on all available frustules that contain the lesion.

References

1. Zuiani C, et al. Biopsie citologiche. *Radiol Med.* 2004;107(Suppl 2 n 5–6):47–52.
2. Giuseppetti GM, Panizza P, Baldassarre S, editors. *Imaging in Senologia-Testo atlante.* Poletto Editore. 2011.
3. Dennison G, Anand R, Makar SH. A prospective study of the use of fine needle aspiration cytology and core biopsy in the diagnosis of breast cancer. *Breast J.* 2003;9(6):491–3.
4. Kocjan G. Needle aspiration cytology of the breast: current perspective on the role in diagnosis and management. *Acta Med Croatica.* 2008;62(4):391–401.
5. Kocjan G, Bourgain C, Fassina A, Hagmar B, Herbert A, Kapila K, Kardum-Skelin I, Kloboves-Prevodnik V, Krishnamurthy S, Koutselini H, Majak B, Olszewski W, Onal B, Pohar-Marinek Z, Shabalova I, Smith J, Tani E, Vielh P, Wiener H, Schenck U, Schmitt F. The role of breast FNAC in diagnosis and clinical management: a survey of current practice. *Cytopathology.* 2008;19(5):271–8.
6. Garund HT, Sheet D, Mahadevappa M, Chatterjee J, Ray AK, Ghosh A. Breast fine needle aspiration cytology practices and commonly perceived diagnostic significance of cytological features: a pan-India survey. *J Cytol.* 2012;29(3):183–9.

7. Smith MJ, Heffron CC, Rothwell JR, Loftus BM, Jeffers M, Geraghty JG. Fine needle aspiration cytology in symptomatic breast lesions: still an important diagnostic modality? *Breast J*. 2012;18(2):103–10.
8. O'Flynn EA, Wilson AR, Michell MJ. Image-guided breast biopsy: state-of-the-art. *Clin Radiol*. 2010;65(4):259–70.
9. Nori J, Bazzocchi M, editors. *Senologia. Stato dell'arte in interventistica*. Napoli: Idelson Gnocchi; 2003.
10. Zagorianakou P, Fiaccavento S, Zagorianakou N, Makrydimas G, Stefanou D, Agnantis NJ. FNAC: its role, limitations and perspective in the preoperative diagnosis of breast cancer. *Eur J Gynaecol Oncol*. 2005;26(2):143–9.
11. Masood S. Core needle biopsy versus fine needle aspiration biopsy: are there similar sampling. *Clin Lab Med*. 2005;25(4):679–88.
12. Tse GM, Tan PH. Diagnosing breast lesions by fine needle aspiration cytology or core biopsy: which is better? *Breast Cancer Res Treat*. 2010;123(1):1–8.
13. Nassar A. Core needle biopsy versus fine needle aspiration biopsy in breast—a historical perspective and opportunities in the modern era. *Diagn Cytopathol*. 2011;39(5):380–8.
14. Leifland K, Lagerstedt U, Svane G. Comparison of stereotactic fine needle aspiration cytology and core needle biopsy in 522 non-palpable breast lesions. *Acta Radiol*. 2003;44(4):387–91.
15. Willems SM, Van Deurzen CH, Van Diest PJ. Diagnosis of breast lesions: fine-needle aspiration cytology or core needle biopsy? A review. *J Clin Pathol*. 2012;65(4):287–92.
16. Garg S, Mohan H, Bal A, Attri AK, Kochhar S. A comparative analysis of core needle biopsy and fine-needle aspiration cytology in the evaluation of palpable and mammographically detected suspicious breast lesions. *Diagn Cytopathol*. 2007;35(11):681–9.
17. Guerrieri AM, et al. Mammotome®. *Radiol Med*. 2004;107(Suppl 2, n 5–6):61–67.
18. Bonnet M, Wallis T, Rossmann M. Histological and radiographic analysis of ductal carcinoma in situ diagnosed using stereotactic incisional core biopsy. *Med Pathol*. 2002;15(2):95–101.
19. Jackman RJ, Marzoni FA Jr, Rosenberg J. False-negative diagnoses at stereotactic vacuum-assisted needle breast biopsy: long-term follow-up of 1,280 lesions and review of the literature. *AJR Am J Roentgenol*. 2009;192(2):341–51.
20. Al Hassan T, Deli Fraine P, El-Khoury M, Joseph L, Zheng J, Mesurole B. Accuracy of percutaneous core needle biopsy in diagnosing papillary breast lesions and potential impact of sonographic features on their management. *J Clin Ultrasound*. 2013;41(1):1–9.
21. Murray MP, Luedtke C, Liberman L, Nehhozina T, Akram M, Brogi E. Classic lobular carcinoma in situ and atypical lobular hyperplasia at percutaneous breast core biopsy: outcomes of prospective excision. *Cancer*. 2013;119(5):1073–9.
22. ACR Council. ACR practice guideline for the performance of ultrasound guided percutaneous breast interventional procedures. Revised 2009.
23. Park H-L, Kim LS. The current role of vacuum assisted breast biopsy system in breast disease. *J Breast Cancer*. 2011;14(1):1–7.
24. Panizza P, De Cobelli F, De Gaspari A. MR-guided stereotactic breast biopsy: technical aspects and preliminary results. *Radiol Med*. 2003;106(3):232–44.
25. Floery D, Helbich TH. MRI-guided percutaneous biopsy of breast lesions: materials, techniques, success rates, and management in patients with suspected radiologic-pathologic mismatch. *Magn Reson Imaging Clin N Am*. 2006;14(3):411–25.
26. Hellerhoff K, Schlossbauer T, Herzog P, Reiser M. Interventional MRI of the breast. Indications, technique, results and perspectives. *Radiologe*. 2008;48(4):367–74.
27. Carbognin G, Girardi V, Brandalise A. MR-guided vacuum-assisted breast biopsy in the management of incidental enhancing lesions detected by breast MR imaging. *Radiol Med*. 2011;116(6):876–85.
28. Kuhl CK, Morakkabati N, Leutner CC, Schmiedel A, Wardelmann E, Schild HH. MR imaging-guided large-core (14-gauge) needle biopsy of small lesions visible at breast MR imaging alone. *Radiology*. 2001;220:31–9.

Isabella Castellano, Jasna Metović, Riccardo Bussone,
and Gretha Grilz

5.1 Pathological Definition of DCIS

Ductal in situ carcinoma (DCIS) or intraductal carcinoma refers to a group of lesions characterized by a neoplastic proliferation confined to the mammary duct. They are composed of epithelial cells with different grade of cytological and architectural atypia, surrounded by a layer of myoepithelial cells and by an intact basement membrane. This pathological definition excludes the invasion of the mammary stroma by cancer cells [1].

5.2 Histological Classification

In standard histologic sections, DCIS is confined within duct and lobules, and pathologists must identify myoepithelial cells around these neoplastic structures. The lack of myoepithelium is a marker of invasiveness. Several antibodies have been proposed to detect myoepithelial cells, such as p63, smooth muscle actin, calponin, CD10, cytocheratin 5/6, and, more recently, p40 [2]. In general, expression of more than one marker is tested based on cytoplasmic or nuclear staining; several recommendations suggested performing routinely both nuclear and cytoplasmic antibodies on the same samples [3].

Due to the current understanding of DCIS as a heterogeneous group of cancers, with different morphology, immunophenotype, and molecular biology, there is no agreement on their classification.

I. Castellano (✉) • J. Metović
Department of Medical Sciences, University of Turin, Turin, Italy
e-mail: isabella.castellano@unito.it

R. Bussone (✉) • G. Grilz
Ospedale Cottolengo, Surgical Section, Turin, Italy
e-mail: bussonericcardo@gmail.com

Over the past 25 years, a number of histological and cytological criteria have been proposed to subdivide these lesions in groups with different prognosis.

Traditionally, DCIS was classified based on architectural growth pattern of the epithelial proliferation, into comedo, solid, cribriform, papillary, micropapillary, clinging, apocrine, and mixed subtypes [4].

However, due to: (1) the low reproducibility of these diagnoses, (2) the high rate of mixed lesions, and (3) the low predictive value of local recurrences, this classification was then replaced by a modern systems based on cyto-nuclear atypia [5]. In particular several international Consensus Conferences recommended that the classification of DCIS should be based primarily on nuclear grade and encouraged pathologists to secondarily include in their diagnoses additional information on necrosis, cell polarization, and architectural differentiation [5, 6].

Depending on the degree of nuclear atypia, DCIS is generally classified in low (small, monomorphic, well-polarized cells, with uniform size and regular chromatin pattern and rare mitotic figures, Fig. 5.1), intermediate (similar to those of low grade but with occasional nucleoli, mitotic figures, and coarse chromatin, Fig. 5.2), or high nuclear grade (large size, pleomorphic, and poorly polarized nuclei, with prominent nucleoli, numerous mitotic cells, and presence of necrosis, Fig. 5.3) [7].

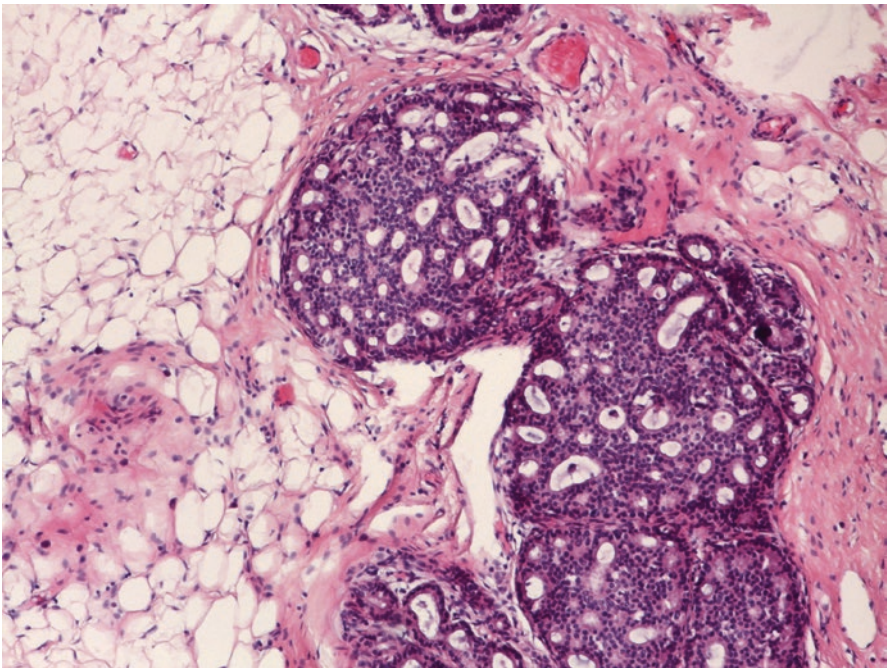


Fig. 5.1 Low nuclear grade DCIS with small, monomorphic cells, with uniform size; generally cribriform proliferation is the most common phenotype

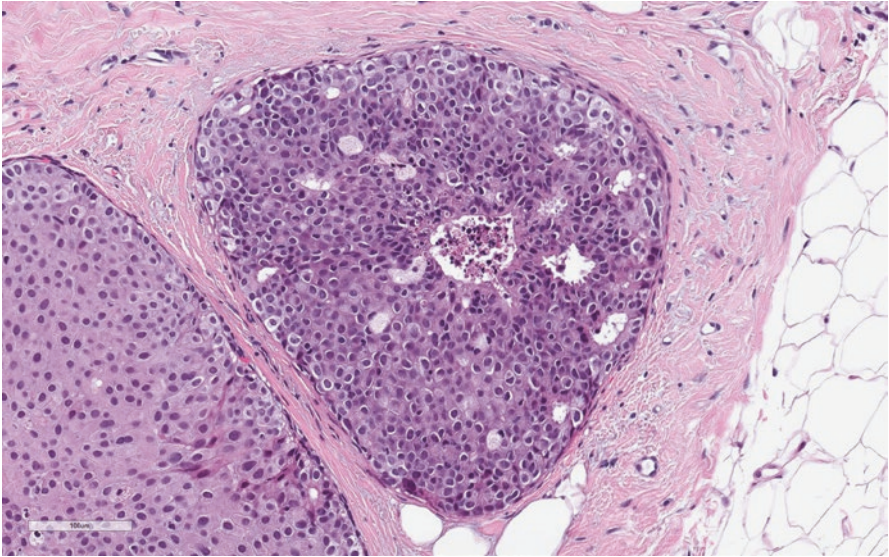


Fig. 5.2 Intermediate nuclear grade DCIS with moderate variation in nuclear size and nuclear pleomorphism. Necrosis may be present

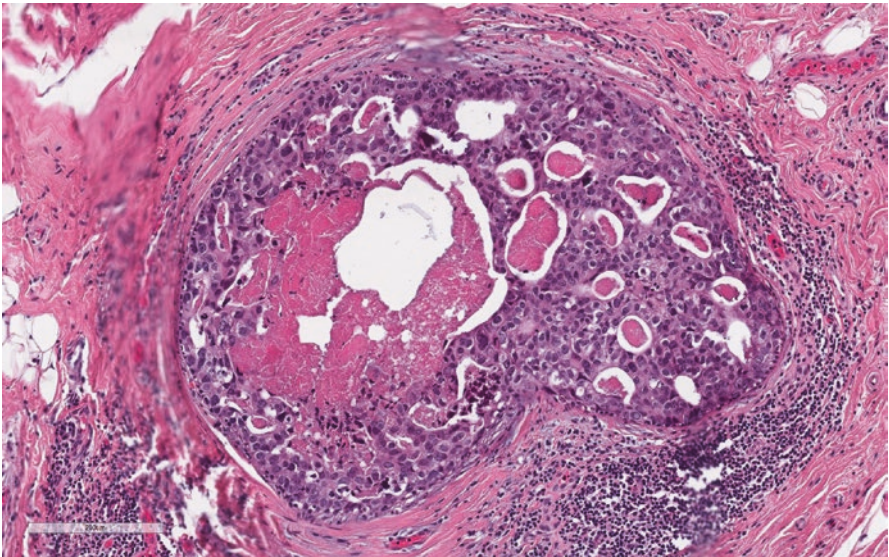


Fig. 5.3 High nuclear grade DCIS with cytological atypia, prominent nucleoli, presence of comedo-necrosis and mitotic cells

5.3 DCIS Carcinogenesis and Progression

In recent years, molecular studies suggested that the assessment of nuclear grade, as proposed by WHO, not only could better correlate with prognosis [8, 9], but it may highlight distinct genetic alternations [10] and distinct evolutionary pathways [11].

In fact, low-grade DCIS tends to be estrogen receptor (ER)/progesterone receptor (PR) positive (Fig. 5.4 a, b) and HER2 negative, and it is frequently characterized by the concurrent presence of deletion of 16q and gains of 1q and 16p. Otherwise, high-grade DCIS tends to be ER/PR negative and HER2 positive (Fig. 5.5 a, b), and it has complex karyotypes [12, 13], including frequent events in 1q+, 5p+, 8p-, 8q+, 11q-, 13-, 14q-, and 17q+ and focal amplifications on 6q22, 8q22, 11q13, 17q12, 17q22–24, and 20q13 [10, 14–16]. Thus, low- and high-grade DCIS may represent two distinct disorders, which may evolve in two distinct forms of invasive cancers (with low and high aggressiveness). In particular, genomic studies of synchronous and metachronous DCIS-invasive carcinoma have shown that there is a molecular continuum between low-grade DCIS and low-grade, well-differentiated invasive carcinoma (such as tubular carcinoma), as well as between high-grade DCIS and high-grade invasive carcinoma. The “low-grade arm” has similar gene expression profile, characterized by ER activation. On the contrary “high-grade arm” lacks ER in favor of the expression of genes related to cell proliferation and promoting invasive growth pattern [17].

Although the mechanisms underlying the progression from DCIS to invasive ductal carcinoma of the breast are yet to be fully elucidated, recent gene expression profile studies demonstrated that, inside specific molecular subtypes, DCIS and invasive carcinoma cells share similar genes and that the largest part of molecular changes occurs from normal epithelium to in situ carcinoma cells [18–21]. These mutations may include TP53 [22], PTEN [23], likewise amplifications of chromosome 20, 11, and 17 [24, 25]. In line with these findings, experimental data confirmed that precursor cells with ability to invade the stroma and with metastatic potential may be present in DCIS lesion and that treating breast cancer before it can become invasive may prevent the progression to infiltrating carcinoma [26]. Another important gene involved in the process of DCIS growth and progression is CDH1 (E-cadherin) that is expressed in normal and DCIS epithelial cells. CDH1 is a cell–cell adhesion protein with a role in epithelial differentiation. It has been shown that a partial or total loss of its expression may occur in the transition from DCIS to invasive breast cancer and in metastatic behavior and poor prognosis [27–29].

It is well established that the evolution of DCIS to invasive breast cancer is not only determined by molecular changes in epithelial cells, but may also strongly depend on stroma, cell-mediated immune mechanisms, and myoepithelial cells [20, 30–32]. In particular, myoepithelial cells seem to act as a tumor suppressor in DCIS [32], and several studies demonstrated that many of the genes that are specific for normal myoepithelial cells, such as CTK14, CTK17, and EGFR, are absent or downregulated in the myoepithelial cells of DCIS lesions. Hence, these changes may lead to breakdown of the ducts and release of the tumor epithelial cells into the surrounding stroma [32, 33]. Other genes involved in extracellular matrix

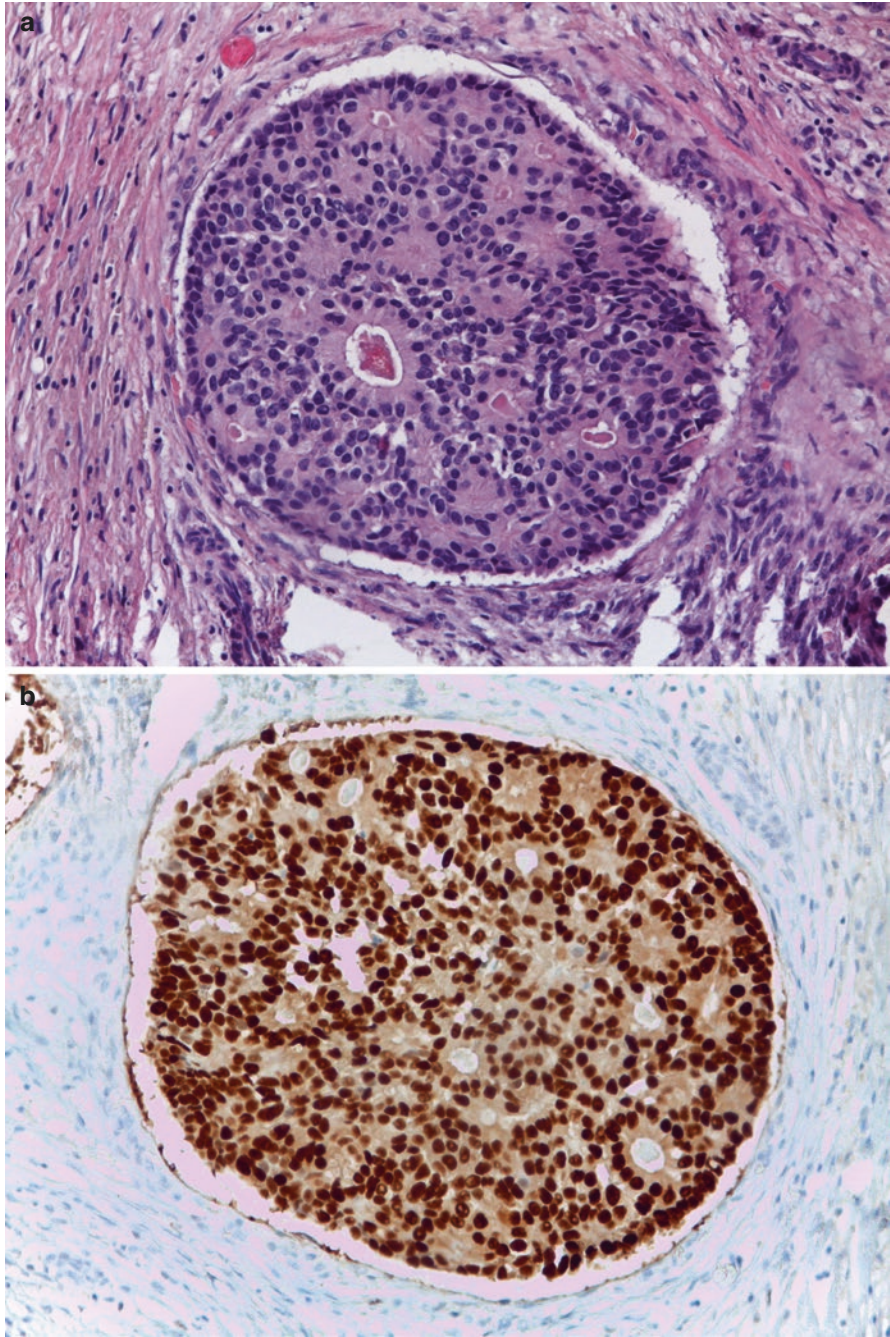


Fig. 5.4 Low nuclear grade DCIS (a) that shows uniform immunostain for estrogen receptor (b)

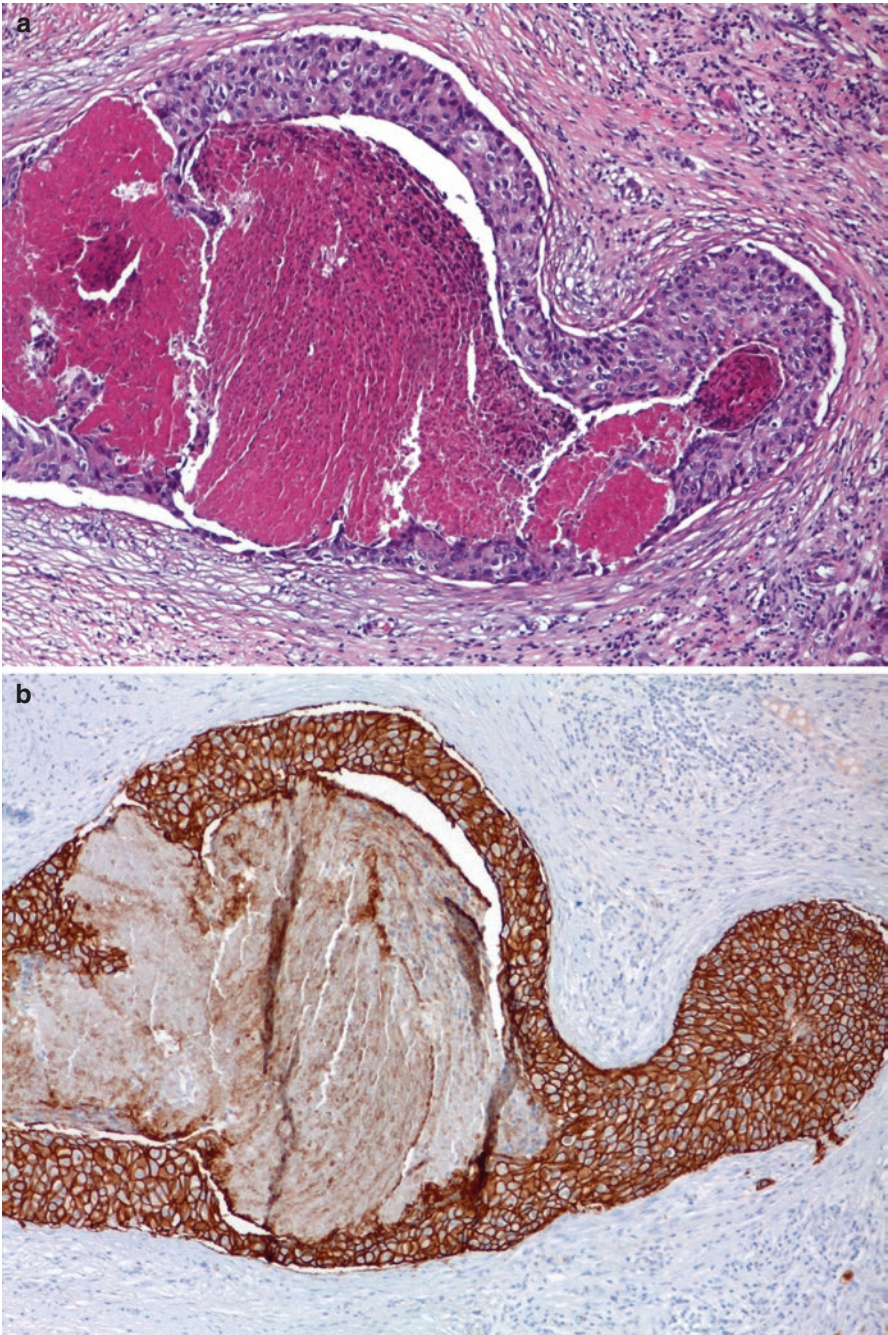


Fig. 5.5 High grade DCIS (a) with HER2 overexpression in immunohistochemistry (b)

remodeling, such as matrix metalloproteinase 2 (MMP2), are closely related to DCIS progression in invasive cancer. It has been shown that MMP2 overexpression can lead to a degradation of the basement membrane, a barrier that inhibits the migration of cells in the surrounding stroma [34].

5.4 The Concept of “DIN”

Due to these emerging genetic data and to the difficulties in distinguishing between low-grade DCIS and other proliferative intraductal lesions such as atypical ductal hyperplasia (ADH), a new classification system was proposed by Tavassoli et al. in 2003 (WHO, 2003) [35]. They suggested to replace the term DCIS in favor of ductal intraepithelial neoplasia (DIN), reserving the term “carcinoma” only for the invasive neoplasia. The subgroup of lesions classified as “DIN 1” encompassed a series of low-grade intraductal proliferations, such as flat epithelial atypia (DIN1a), ADH (DIN 1b), and low-grade DCIS (DIN1c), not only with similar morphological features but also with similar genetic alterations, typical of low-grade neoplasia. DIN 2 represented intermediate-grade DCIS with intermediate level of differentiation between low- and high-grade DCIS. This latter group was finally classified as DIN 3 lesions, with atypical and pleomorphic cells and genetic features typically observed in high-grade arm. Although several studies supported the DIN classification [36, 37], this terminology did not gain widespread acceptance, in part because it includes entities, such as DIN1a, in which neoplastic nature is not fully demonstrated, partly because, in specific subgroups, such as DIN 1B and DIN 1C, the morphological distinction remains subjective [38]. Thus the latest WHO classification in 2012 [39] abounded the term DIN in favor of the previous classifications based on the nuclear grade. However, this topic remains a matter of discussion, even for the psychological impact on patients. In fact, some works suggested that the term “DIN” may eliminate the anxiety produced by the term “carcinoma,” contributing to reduced adverse psychological reactions and decreased confusion in healthcare settings [37, 40].

5.5 Pathological Prognostic Markers

Traditionally, size of lesion, nuclear grade, type and extension of comedo-necrosis, hormone receptor expression, and margin status have been described as prognostic markers [39, 41, 42].

Thus, when DCIS is diagnosed on surgical specimens, all of these variables should be cited in the pathological report. To reach this aim, the use of large histological tissue sections could help pathologists to better describe DCIS in terms of extension, heterogeneity and margin status.

Among prognostic factors, some studies have reported nuclear grade to be the most significant predictor of local recurrence on both univariate and multivariate analysis [43, 44].

Otherwise, the presence of comedo-necrosis, generally associated with high-nuclear-grade DCIS, is closely related to the risk of ipsilateral recurrences following lumpectomy, and a meta-analysis [44], based on 44 articles, confirmed these data, showing a risk of recurrences for DCIS with comedo-necrosis ranging from 1.3 to 5.0 [45–51].

The prognostic impact of histotype is still debated, mainly due to the low reproducibility of these diagnoses and to the presence of high rate of mixed lesions. Several studies reported that the “cribriform” growth pattern is related to indolent lesions with a low risk of subsequent invasive carcinoma, whereas solid DCIS are generally an aggressive neoplasia, especially if associated with comedo-necrosis [45, 52, 53].

In regards to micropapillary growth patterns, some studies suggested that low-grade micropapillary DCIS may be treated with excision without additional irradiation, for an exceptionally low risk of recurrences of these entities [52]. Otherwise, others reported that this phenotype is often multicentric [54, 55] and larger than other subtypes [56] and that it may remain clinically and radiologically silent, even if it is found to be extensive and of high grade [57]. In addition two studies reported that the micropapillary growth pattern is an independent high-risk factor for local recurrences [58, 59].

Traditionally, both ER and PR are frequently tested in DCIS; however, ER is the only one validated for routine clinical practice in DCIS (WHO 2012) [39]. National Comprehensive Cancer Network (NCCN) guidelines include its determination as part of the workup of DCIS [60].

The majority (80%) of DCIS cases are ER positive [20]; its expression is generally related to low- to intermediate-nuclear-grade DCIS cases. On the other hand, the predictive value of this marker remains a matter of discussion, and there are not enough data to make general recommendations for the use of ER in DCIS to decide about antihormonal treatment [61].

Very few data are available on PR, and there is disagreement regarding its routine determination (WHO 2012, 40) on DCIS samples. Among other immunohistochemical markers that are currently under investigation, HER2 is one of the most studied. Its role in DCIS is unclear. It is overexpressed/amplified in 50% to 60% of DCIS cases, and its detection is generally associated with high-nuclear-grade DCIS with comedo-necrosis and presence of stroma microinvasion [62–64]. Several studies have suggested that HER2 may play a critical role in the progression to invasive carcinoma [65, 66] and its expression has been linked to recurrence after surgical excision, mainly in patients without radiation therapy [67, 68].

The identification of HER2 expression in DCIS may be useful even for a better radiological surveillance program: in a prospective observational study comparing mammography to magnetic resonance, the latter was more sensitive and specific in diagnosing high-grade DCIS [69]. Although several studies have been proposed with trastuzumab [70] or with lapatinib [71, 72] in HER2-positive DCIS patients, to date, there is no evidence of the clinical effect of anti-HER2 treatment. However, a first prospective, randomized phase III multi-institution clinical trial—National Surgical Adjuvant Breast Project (NSABP) B-43— is

currently ongoing. It compares whole breast irradiation alone with WBI given concurrently with trastuzumab in women with HER2-positive DCIS treated by lumpectomy [73].

The expression of ER, PR, and HER2 together with the rate of Ki67 may allow to classify DCIS, using “surrogate molecular subtypes,” in Luminal A, B, HER2, and triple negative DCIS. However, the prognostic impact of molecular subtypes in DCIS, following St. Gallen surrogate definition (St. Gallen Consensus Conference—[74–76]), is yet to be clarified.

Lazzeroni et al. [77] found that immunohistochemically defined molecular subtypes in DCIS may be an indicator of prognosis, mainly due to the assessment of Ki67. Zhou et al. [78] demonstrated that combination of molecular markers ER–/HER2+ was statistically significantly associated with a high risk for a recurrence being in situ and that ER+/HER2–/EGFR– tumors were strongly associated with a subsequent recurrence being invasive. Otherwise, one study failed to demonstrate a prognostic value for the surrogate molecular subtyping of DCIS up to 10 years after diagnosis. However, it was shown that triple-negative DCIS had an elevated risk of recurrence [79].

Other immunohistochemical markers such as TP53, Bcl2, and androgen receptor have been investigated as potential prognostic markers. Presence of TP53 mutation together with an increased level of Ki67 in DCIS lesions are associated with high risk of recurrence [80].

In particular, mutations of TP53 occur more frequently in HG-DCIS and in HER2-positive tumors than in ER/PR-positive low-grade DCIS [81]. The expression of Bcl-2 that is present in the continuum of breast lesions from ADH to well-differentiated DCIS gradually decreases as lesions become more aggressive [82].

On the other hand, the role of AR expression in DCIS is not fully understood, and different results are present in literature [83, 84].

Very recently, to better stratify patients by prognosis, a multigene reverse transcriptase (RT)-PCR assay was recently proposed by Genomic Health. The test, called Oncotype DX Breast Cancer Assay for DCIS, is based on 12 genes from the Oncotype DX Invasive Recurrence Score (Genomic Health, Redwood City, CA, USA). The algorithm uses seven cancer-related genes (Ki67, STK15, Survivin, CCNB1, MYBL2, PR, and GSTM1) and five reference genes to create a score, designed to quantify the 10-year risk of local recurrence, both in situ and invasive, in patients with DCIS treated with breast-conserving surgery without radiation.

The results are reported as a numerical score called “DCIS Score,” which classifies DCIS patients into low-, intermediate-, and high-risk groups with overall local recurrence rates of 10.6, 26.7, and 29.5%, respectively, at 10 years. Invasive recurrence rates are 3.7%, 12.3%, and 19.2% for these groups, respectively [85].

The application of this test, together with clinical, pathological, and immunohistochemical analyses, may result in a better definition of the risk profile of DCIS patients, allowed to avoid radiotherapy in low-risk categories. However, the Oncotype DX Breast Cancer Assay for DCIS is applicable only to patients with low-intermediate-grade DCIS with resection margins of at least 3 mm and to patients with high-grade DCIS with lesion of 1 cm or less in size [85].

In addition, a recent study suggested that incorporating the DCIS Score in routine clinical practice is cost-effective, even if DCIS Score lowered the proportion of women undergoing RT [86].

5.6 Molecular Assessment of DCIS and Future Approaches

In recent years, a number of studies have been proposed to assess the molecular and genetic features of DCIS cells, with the aim to discover biological features involved in growth and progression of these lesions. In particular, microRNA (miRNA) is a class of small RNA molecules that, through the control of mRNA expression, may regulate cellular processes such as stem cell division, cell growth, apoptosis, and carcinogenesis [87–90].

It has recently been discovered that some miRNAs are under- or overexpressed in DCIS in comparison with normal histological breast tissue [91]. For example, miR-132, which is frequently downregulated in DCIS, acts as inhibitor of cell proliferation [92]. The most significant miRNA deregulations seem to occur during the transition from normal to ADH, to DCIS epithelium, such as the loss of the tumor suppressor miR-125b and the gain of miR-182, miR-183, and miR-21 [91, 93]. Furthermore, although most miRNA changes in invasive carcinoma were already apparent in DCIS [94], nine-microRNA signature was identified as invasive carcinoma that progressed from in situ carcinoma, such as miR-210 and miR-221 that were downregulated in the in situ and upregulated in the transition to invasive lesion [95]. In the same study, authors reported that crucial genes in cancer development, such as BRCA1, FANCD, FANCF, PARP1, E-cadherin, and Rb1, are inversely related profiles to miR-210: they were all activated in the in situ and downregulated in invasive carcinoma. Another study found a consistent increase in the expression of miR-21 along with its targets (PTEN, PCCD4, and TMI) in breast cancer progression [96]. Together these findings underline the relevance for studying miRNAs as markers of risk of DCIS growth and progression.

Several molecular DCIS studies aimed to better define the role of DNA methylation in breast cancer differentiation and progression. In line with the above chapters, it has been shown that the number of methylated genes increased from normal breast to DCIS, whereas IDC did not differ from DCIS [20, 97–99]. Thus, DNA methylation seems not to play a role in the development of invasion, but it is very important in early breast carcinogenesis. Finally, a recent work [100] studying the molecular landscape of DCIS at the mutational, transcriptomic, and epigenetic levels, using DNA and RNA-Seq analysis, showed that important and complex epigenetic changes present in the invasive form are already operating at the in situ stage. In addition, they demonstrated that a subgroup of HG-DCIS lesions can be identified displaying more aggressive molecular profiles and that most high-grade DCIS lesions demonstrated profiles indistinguishable from invasive cancers.

Further studies of the genomic landscape of DCIS are needed to clarify the genomic and genetic alterations involved in DCIS progression and to discern the more aggressive phenotypes. Genomic technologies such as next-generation

sequencing (NGS) modalities, which are just beginning to be applied to DCIS [101], may offer in the future a depth molecular analysis of these lesions, revealing mutations, alternative splice variants, novel potential therapeutic targets, and promising biomarkers.

References

1. Tavassoli FA, Eusebi V. AFIP Atlas of tumor pathology-tumors of the mammary gland. Silver Spring: American Registry of Pathology; 2009.
2. Kővári B, Szász AM, Kulka J, et al. Evaluation of p40 as a myoepithelial marker in different breast lesions. *Pathobiology*. 2015;82:165–70.
3. Dewar R, Fadare O, Gilmore H. Best practices in diagnostic immunohistochemistry: myoepithelial markers in breast pathology. *Arch Pathol Lab Med*. 2011;135:422–9.
4. Bellamy CO, McDonald C, Salter DM, et al. Noninvasive ductal carcinoma of the breast: the relevance of histologic categorization. *Hum Pathol*. 1993;24:16–23.
5. The Consensus Conference Committee. Consensus conference on the classification of ductal carcinoma in situ. *Cancer*. 1997;80:1798–802.
6. The Consensus Committee. Consensus conference on the classification of ductal carcinoma in situ. *Hum Pathol*. 1997;28:1221–5.
7. Tavassoli FA, Devilee P. World Health Organization classification of tumors of the breast. Lyon: International Agency for Research on Cancer; 2003.
8. Silverstein MJ, Poller DN, Waisman JR, et al. Prognostic classification of breast ductal carcinoma-in-situ. *Lancet*. 1995;345:1154–7.
9. Lagios MD, Margolin FR, Westdahl PR, Rose MR. Mammographically detected duct carcinoma in situ. Frequency of local recurrence following tylectomy and prognostic effect of nuclear grade on local recurrence. *Cancer*. 1989;63:618–24.
10. Simpson PT, Reis-Filho JS, Gale T, Lakhani SR. Molecular evolution of breast cancer. *J Pathol*. 2005;205:248–54.
11. Bombonati A, Sgroi DC. The molecular pathology of breast cancer progression. *J Pathol*. 2011;223:307–17.
12. Reis-Filho JS, Simpson PT, Gale T, Lakhani SR. The molecular genetics of breast cancer: the contribution of comparative genomic hybridization. *Pathol Res Pract*. 2005;201:713–25.
13. Lopez-Garcia MA, Geyer FC, Lacroix-Triki M, et al. Breast cancer precursors revisited: molecular features and progression pathways. *Histopathology*. 2010;57:171–92.
14. Reis-Filho JS, Lakhani SR. The diagnosis and management of pre-invasive breast disease: genetic alterations in pre-invasive lesions. *Breast Cancer Res*. 2003;5:313–9.
15. Buerger H, Mommers C, Littmann R, et al. Ductal invasive G2 and G3 carcinomas of the breast are the end stages of at least two different lines of genetic evolution. *J Pathol*. 2001;194:165–70.
16. Shackney SE, Silverman JF. Molecular evolutionary patterns in breast cancer. *Adv Anat Pathol*. 2003;10:278–90.
17. Ma XJ, Salunga R, Tuggle JT, et al. Gene expression profiles of human breast cancer progression. *Proc Natl Acad Sci U S A*. 2003;100:5974–9.
18. Lee S, Stewart S, Nagtegaal I, Luo J, Wu Y, Colditz G, Medina D, Allred DC. Differentially expressed genes regulating the progression of ductal carcinoma in situ to invasive breast cancer. *Cancer Res*. 2012;72:4574–86.
19. Knudsen ES, Ertel A, Davicioni E, et al. Progression of ductal carcinoma in situ to invasive breast cancer is associated with gene expression programs of EMT and myoepithelia. *Breast Cancer Res Treat*. 2012;133:1009–24.
20. Mardekian SK, Bombonati A, Palazzo JP. Ductal carcinoma in situ of the breast: the importance of morphologic and molecular interactions. *Hum Pathol*. 2016;49:114–23.

21. Casasent AK, Edgerton M, Navin NE. Genome evolution in ductal carcinoma in situ: invasion of the clones. *J Pathol.* 2017;241:208–18.
22. Kim SY, Jung SH, Kim MS, et al. Genomic differences between pure ductal carcinoma in situ and synchronous ductal carcinoma in situ with invasive breast cancer. *Oncotarget.* 2015;6:7597–607.
23. Yates LR, Gerstung M, Knappskog S, et al. Subclonal diversification of primary breast cancer revealed by multiregion sequencing. *Nat Med.* 2015;21:751–9.
24. Aubele M, Cummings M, Walsch A, et al. Heterogeneous chromosomal aberrations in intra-ductal breast lesions adjacent to invasive carcinoma. *Anal Cell Pathol.* 2000;20:17–24.
25. Buerger H, Otterbach F, Simon R, et al. Comparative genomic hybridization of ductal carcinoma in situ of the breast-evidence of multiple genetic pathways. *J Pathol.* 1999;187:396–402.
26. Espina V, Liotta LA. What is the malignant nature of human ductal carcinoma in situ? *Nat Rev Cancer.* 2011;11:68–75.
27. Berx G, Van Roy F. The E-cadherin/catenin complex: an important gatekeeper in breast cancer tumorigenesis and malignant progression. *Breast Cancer Res.* 2001;3:289–93.
28. Choi Y, Lee HJ, Jang MH, et al. Epithelial-mesenchymal transition increases during the progression of in situ to invasive basal-like breast cancer. *Hum Pathol.* 2013;44:2581–9.
29. Facina G, Lopes-Costa PV, Dos Santos AR, et al. Immunohistochemical expression of E-cadherin in sclerosing adenosis, ductal carcinoma in situ and invasive ductal carcinoma of the breast. *Diagn Cytopathol.* 2010;38:235–8.
30. Liao D, Luo Y, Markowitz D, et al. Cancer associated fibroblasts promote tumor growth and metastasis by modulating the tumor immune microenvironment in a 4T1 murine breast cancer model. *PLoS One.* 2009;4:e7965.
31. Gudjonsson T, Rønnev-Jessen L, Villadsen R, et al. Normal and tumor-derived myoepithelial cells differ in their ability to interact with luminal breast epithelial cells for polarity and basement membrane deposition. *J Cell Sci.* 2002;115:39–50.
32. Adriance MC, Inman JL, Petersen OW, Bissell MJ. Myoepithelial cells: good fences make good neighbors. *Breast Cancer Res.* 2005;7:190–7.
33. Polyak K, Hu M. Do myoepithelial cells hold the key for breast tumor progression? *J Mammary Gland Biol Neoplasia.* 2005;10:231–47.
34. Abba MC, Drake JA, Hawkins KA, et al. Transcriptomic changes in human breast cancer progression as determined by serial analysis of gene expression. *Breast Cancer Res.* 2004;6:R499–513.
35. Tavassoli FA. Breast pathology: rationale for adopting the ductal intraepithelial neoplasia (DIN) classification. *Nat Clin Pract Oncol.* 2005;2:116–7.
36. Buonomo O, Orsaria P, Contino G, et al. Pathological classification of DCIS and planning of therapeutic management. *Anticancer Res.* 2009;29:1499–506.
37. Galimberti V, Monti S, Mastropasqua MG. DCIS and LCIS are confusing and outdated terms. They should be abandoned in favor of ductal intraepithelial neoplasia (DIN) and lobular intraepithelial neoplasia (LIN). *Breast.* 2013;22:431–5.
38. Viale G. Histopathology of primary breast cancer 2005. *Breast.* 2005;14:487–92.
39. Lakhani SR, Ellis IO, Schnitt SJ, et al. WHO classification of tumors of the breast. Lyon: International Agency for Research on Cancer; 2012.
40. Pravettoni G, Yoder WR, Riva S, et al. Eliminating “ductal carcinoma in situ” and “lobular carcinoma in situ” (DCIS and LCIS) terminology in clinical breast practice: the cognitive psychology point of view. *Breast.* 2016;25:82–5.
41. Benson JR, Wishart GC. Predictors of recurrence for ductal carcinoma in situ after breast-conserving surgery. *Lancet Oncol.* 2013;14:e348–57.
42. Zhang X, Dai H, Liu B, et al. Predictors for local invasive recurrence of ductal carcinoma in situ of the breast: a meta-analysis. *Eur J Cancer Prev.* 2016;25:19–28.
43. Wang SY, Shamliyan T, Virnig BA, Kane R. Tumor characteristics as predictors of local recurrence after treatment of ductal carcinoma in situ: a meta-analysis. *Breast Cancer Res Treat.* 2011;127:1–14.

44. Wapnir IL, Dignam JJ, Fisher B, et al. Long-term outcomes of invasive ipsilateral breast tumor recurrences after lumpectomy in NSABP B-17 and B-24 randomized clinical trials for DCIS. *J Natl Cancer Inst.* 2011;103:478–88.
45. Fisher ER, Dignam J, Tan-Chiu E, et al. Pathologic findings from the National Surgical Adjuvant Breast Project (NSABP) eight-year update of Protocol B-17: intraductal carcinoma. *Cancer.* 1999;86:429–38.
46. Bijker N, Peterse JL, Duchateau L, et al. Risk factors for recurrence and metastasis after breast-conserving therapy for ductal carcinoma-in-situ: analysis of European Organization for Research and Treatment of Cancer Trial 10853. *J Clin Oncol.* 2001;19:2263–71.
47. Ringberg A, Nordgren H, Thorstensson S, et al. Histopathological risk factors for ipsilateral breast events after breast conserving treatment for ductal carcinoma in situ of the breast—results from the Swedish randomised trial. *Eur J Cancer.* 2007;43:291–8.
48. Wai ES, Lesperance ML, Alexander CS, et al. Predictors of local recurrence in a population-based cohort of women with ductal carcinoma in situ treated with breast conserving surgery alone. *Ann Surg Oncol.* 2011;18:119–24.
49. Ottesen GL, Graversen HP, Blichert-Toft M, et al. Carcinoma in situ of the female breast. 10 year follow-up results of a prospective nationwide study. *Breast Cancer Res Treat.* 2000;62:197–210.
50. Rudloff U, Jacks LM, Goldberg JI, et al. Nomogram for predicting the risk of local recurrence after breast-conserving surgery for ductal carcinoma in situ. *J Clin Oncol.* 2010;28:3762–9.
51. MacDonald HR, Silverstein MJ, Mabry H, et al. Local control in ductal carcinoma in situ treated by excision alone: incremental benefit of larger margins. *Am J Surg.* 2005;190:521–5.
52. Bijker N, Meijnen P, Peterse JL, et al. Breast conserving treatment with or without radiotherapy in ductal carcinoma-in-situ: ten year results of European Organisation for Research and Treatment of Cancer randomized phase III trial 10853—a study by the EORTC Breast Cancer Cooperative Group and EORTC Radiotherapy Group. *J Clin Oncol.* 2006;24:3381–7.
53. Solin LJ, Fourquet A, Vicini FA, et al. Mammographically detected ductal carcinoma in situ of the breast treated with breast-conserving surgery and definitive breast irradiation: long-term outcome and prognostic significance of patient age and margin status. *Int J Radiat Oncol Biol Phys.* 2001;50:991–1002.
54. Patchefsky AS, Schwartz GF, Finklestein SD, et al. Heterogeneity of intraductal carcinoma of the breast. *Cancer.* 1989;63:731–41.
55. Schwartz GF, Patchefsky AS, Finklestein SD, et al. Nonpalpable in situ ductal carcinoma of the breast. Predictors of multicentricity and microinvasion and implications for treatment. *Arch Surg.* 1989;124:29–32.
56. Scott MA, Lagios MD, Axelsson K, et al. Ductal carcinoma in situ of the breast: reproducibility of histological subtype analysis. *Hum Pathol.* 1997;28:967–73.
57. Tot T, Gere M. Radiological-pathological correlation in diagnosing breast carcinoma: the role of pathology in the multimodality era. *Pathol Oncol Res.* 2008;14:173–8.
58. Fisher ER, Land SR, Saad RS, et al. Pathologic variables predictive of breast events in patients with ductal carcinoma in situ. *Am J Clin Pathol.* 2007;128:86–91.
59. Castellano I, Marchiò C, Tomatis M, et al. Micropapillary ductal carcinoma in situ of the breast: an inter-institutional study. *Mod Pathol.* 2010;23:260–9.
60. NCCN guide lines. www.nccn.org/professionals/physician_gls/PDF/breast.pdf
61. Harris L, Fritsche H, Mennel R, et al. American Society of Clinical Oncology 2007 update of recommendations for the use of tumor markers in breast cancer. *J Clin Oncol.* 2007;25:5287–312.
62. DiGiovanna MP, Chu P, Davison TL, et al. Active signaling by HER-2/neu in a subpopulation of HER-2/neu-overexpressing ductal carcinoma in situ: clinicopathological correlates. *Cancer Res.* 2002;62:6667–73.
63. Yu KD, Wu LM, Liu GY, et al. Different distribution of breast cancer subtypes in breast ductal carcinoma in situ (DCIS), DCIS with microinvasion, and DCIS with invasion component. *Ann Surg Oncol.* 2011;18:1342–8.

64. Fang Y, Wu J, Wang W, et al. Biologic behavior and long-term outcomes of breast ductal carcinoma in situ with microinvasion. *Oncotarget*. 2016;7:64182–90.
65. Roses RE, Paulson EC, Sharma A, et al. HER-2/neu overexpression as a predictor for the transition from in situ to invasive breast cancer. *Cancer Epidemiol Biomark Prev*. 2009;18:1386–9.
66. Curigliano G, Disalvatore D, Esposito A, et al. Risk of subsequent in situ and invasive breast cancer in human epidermal growth factor receptor 2-positive ductal carcinoma in situ. *Ann Oncol*. 2015;26:682–7.
67. Holmes P, Lloyd J, Chervoneva I, et al. Prognostic markers and long-term outcomes in ductal carcinoma in situ of the breast treated with excision alone. *Cancer*. 2011;117:3650–7.
68. Cornfield DB, Palazzo JP, Schwartz GF, et al. The prognostic significance of multiple morphologic features and biologic markers in ductal carcinoma in situ of the breast: a study of a large cohort of patients treated with surgery alone. *Cancer*. 2004;100:2317–27.
69. Kuhl CK, Schrading S, Bieling HB, et al. MRI for diagnosis of pure ductal carcinoma in situ: a prospective observational study. *Lancet*. 2007;370:485–92.
70. Kuerer HM, Buzdar AU, Mittendorf EA, et al. Biologic and immunologic effects of preoperative trastuzumab for ductal carcinoma in situ of the breast. *Cancer*. 2011;117:39–47.
71. Decensi A, Puntoni M, Pruneri G, et al. Lapatinib activity in premalignant lesions and HER-2-positive cancer of the breast in a randomized, placebo-controlled presurgical trial. *Cancer Prev Res (Phila)*. 2011;4:1181–9.
72. Estévez LG, Suarez-Gauthier A, García E, et al. Molecular effects of lapatinib in patients with HER2 positive ductal carcinoma in situ. *Breast Cancer Res*. 2014;16:R76.
73. Siziopikou KP, Anderson SJ, Cobleigh MA, et al. Preliminary results of centralized HER2 testing in ductal carcinoma in situ (DCIS): NSABP B-43. *Breast Cancer Res Treat*. 2013;142:415–21.
74. Goldhirsch A, Wood WC, Coates AS, et al. Strategies for subtypes—dealing with the diversity of breast cancer: highlights of the St. Gallen International Expert Consensus on the Primary Therapy of Early Breast Cancer 2011. *Ann Oncol*. 2011;22:1736–47.
75. Goldhirsch A, Winer EP, Coates AS, et al. Personalizing the treatment of women with early breast cancer: highlights of the St Gallen International Expert Consensus on the Primary Therapy of Early Breast Cancer 2013. *Ann Oncol*. 2013;24:2206–23.
76. Coates AS, Winer EP, Goldhirsch A, et al. Tailoring therapies—improving the management of early breast cancer: St Gallen International Expert Consensus on the Primary Therapy of Early Breast Cancer 2015. *Ann Oncol*. 2015;26:1533–46.
77. Lazzeroni M, Guerrieri-Gonzaga A, Botteri E, et al. Tailoring treatment for ductal intraepithelial neoplasia of the breast according to Ki-67 and molecular phenotype. *Br J Cancer*. 2013;108:1593–601.
78. Zhou W, Johansson C, Jirstrom K, et al. A comparison of tumor biology in primary ductal carcinoma in situ recurring as invasive carcinoma versus a new in situ. *Int J Breast Cancer*. 2013;2013:582134.
79. Zhou W, Jirstrom K, Amini RM, et al. Molecular subtypes in ductal carcinoma in situ of the breast and their relation to prognosis: a population-based cohort study. *BMC Cancer*. 2013;13:512.
80. Tsikitis VL, Chung MA. Biology of ductal carcinoma in situ classification based on biologic potential. *Am J Clin Oncol*. 2006;29:305–10.
81. Vincent-Salomon A, Lucchesi C, Gruel N, et al. Integrated genomic and transcriptomic analysis of ductal carcinoma in situ of the breast. *Clin Cancer Res*. 2008;14:1956–65.
82. Mustonen M, Raunio H, Pääkkö P, Soini Y. The extent of apoptosis is inversely associated with bcl-2 expression in premalignant and malignant breast lesions. *Histopathology*. 1997;31:347–54.
83. Gonzalez LO, Corte MD, Junquera S, et al. Expression of androgen receptor and two androgen-induced proteins (apolipoprotein D and pepsinogen C) in ductal carcinoma in situ of the breast. *Histopathology*. 2007;50:866–74.

84. Tumedei MM, Silvestrini R, Ravaioli S, et al. Role of androgen and estrogen receptors as prognostic and potential predictive markers of ductal carcinoma in situ of the breast. *Int J Biol Markers*. 2015;30:e425–8.
85. Solin LJ, Gray R, Baehner FL, et al. A multigene expression assay to predict local recurrence risk for ductal carcinoma in situ of the breast. *J Natl Cancer Inst*. 2013;105:701–10.
86. Raldow AC, Sher D, Chen AB, et al. Cost effectiveness of the oncotype DX DCIS score for guiding treatment of patients with ductal carcinoma in situ. *J Clin Oncol*. 2016. pii: JCO678532.
87. Guo H, Ingolia NT, Weissman JS, Bartel DP. Mammalian microRNAs predominantly act to decrease target mRNA levels. *Nature*. 2010;466:835–40.
88. Taft RJ, Pang KC, Mercer TR, et al. Non-coding RNAs: regulators of disease. *J Pathol*. 2010;220:126–39.
89. Mattie MD, Benz CC, Bowers J, et al. Optimized high-throughput microRNA expression profiling provides novel biomarker assessment of clinical prostate and breast cancer biopsies. *Mol Cancer*. 2006;5:24.
90. Blenkiron C, Goldstein LD, Thorne NP, et al. MicroRNA expression profiling of human breast cancer identifies new markers of tumor subtype. *Genome Biol*. 2007;8:R214.
91. Hannafon BN, Sebastiani P, de las Morenas A, et al. Expression of microRNA and their gene targets are dysregulated in preinvasive breast cancer. *Breast Cancer Res*. 2011;13:R24.
92. Li S, Meng H, Zhou F, et al. MicroRNA-132 is frequently down-regulated in ductal carcinoma in situ (DCIS) of breast and acts as a tumor suppressor by inhibiting cell proliferation. *Pathol Res Pract*. 2013;209:179–83.
93. Chen L, Li Y, Fu Y, et al. Role of deregulated microRNAs in breast cancer progression using FFPE tissue. *PLoS One*. 2013;8:e54213.
94. Farazi TA, Horlings HM, Ten Hoeve JJ, et al. MicroRNA sequence and expression analysis in breast tumors by deep sequencing. *Cancer Res*. 2011;71:4443–53.
95. Volinia S, Galasso M, Sana ME, et al. Breast cancer signatures for invasiveness and prognosis defined by deep sequencing of microRNA. *Proc Natl Acad Sci U S A*. 2012;109:3024–9.
96. Qi L, Bart J, Tan LP, et al. Expression of miR-21 and its targets (PTEN, PDCD4, TM1) in flat epithelial atypia of the breast in relation to ductal carcinoma in situ and invasive carcinoma. *BMC Cancer*. 2009;9:163.
97. Mugggerud AA, Rønneberg JA, Wärnberg F, et al. Frequent aberrant DNA methylation of ABCB1, FOXC1, PPP2R2B and PTEN in ductal carcinoma in situ and early invasive breast cancer. *Breast Cancer Res*. 2010;12:R3.
98. Lee JS. GSTP1 promoter hypermethylation is an early event in breast carcinogenesis. *Virchows Arch*. 2007;450:637–42.
99. Moelans CB, Verschuur-Maes AH, van Diest PJ. Frequent promoter hypermethylation of BRCA2, CDH13, MSH6, PAX5, PAX6 and WT1 in ductal carcinoma in situ and invasive breast cancer. *J Pathol*. 2011;225:222–31.
100. Abba MC, Gong T, Lu Y, et al. A molecular portrait of high-grade ductal carcinoma in situ. *Cancer Res*. 2015;75:3980–90.
101. Kaur H, Mao S, Shah S, et al. Next-generation sequencing: a powerful tool for the discovery of molecular markers in breast ductal carcinoma in situ. *Expert Rev Mol Diagn*. 2013;13:151–65.

Christian Rizzetto, Luca Seriau, and Paolo Burelli

6.1 Introduction

Breast cancer is the most common form of cancer and second leading cause of death among women in Europe [1], but three decades of breast cancer screening have dramatically changed the type and stage of detected cancer lesions [2]. In particular, the widespread use of breast cancer screening program, which increases patient self-awareness, combined with intensified use of advanced imaging modalities for diagnosis purposes, has resulted in an increase in the identification of clinically occult non-palpable breast cancers which are amendable to breast-conserving surgery [3–5].

Moreover, advances in imaging have resulted in a remarkable rise in the diagnosis of ductal carcinoma in situ (DCIS) of the breast [6], that is, a noninvasive breast cancer that encompasses a wide spectrum of diseases, ranging from low-grade lesions that are not life threatening to high-grade lesions that may harbor foci of invasive breast cancer. For most of the twentieth century, DCIS represented less than 1% of all newly diagnosed cases of breast cancer, and it was mostly a symptomatic disease characterized by patients presenting with a palpable mass or bloody nipple discharge [7]. Currently, DCIS represents 20–45% of all mammographically detected cancers [8–10] evident as microcalcifications alone in about 70%, grouped in segmental or linear arrangements reflecting their presence in the duct [11].

In contrast to invasive breast cancer, DCIS is often diffusely spread and the margins are therefore less discrete [12], and the surgical removal can be challenging because the risk of incomplete excision is substantial, as the involved area is hard to pinpoint. Consequently, an accurate preoperative localization of the lesion is mandatory in order to enable a targeted surgical excision, in favor of cosmetic and conservative surgery [13].

C. Rizzetto • L. Seriau • P. Burelli, M.D. (✉)
Breast Unit, “Ca’ Foncello” Hospital, Piazza Ospedale 1, 31010 Treviso, Italy
e-mail: paolo.burelli1@aulss2.veneto.it

The management of DCIS poses a unique challenge for surgeons because the surgical removal requires a specific approach. The main challenge of resecting non-palpable lesions is to ensure clear margins while minimizing the resection of healthy tissue and cosmetic damage [14, 15]. Recently, the accepted standard of treatment for non-palpable breast cancers, or DCIS, of wire-guided localization (WGL) has been increasingly challenged by radio-guided localization technique in the form of radio-guided occult lesion localization (ROLL). In any case, both procedures depend upon the presence of skilled radiologists to perform either ultrasound or stereotactically guided localization, with the insertion of the hooked wire or the inoculation of the radiolabelled albumin-based colloid into the breast lesion.

6.2 Wire-Guided Localization Technique

The use of a wire to guide surgeons for intraoperative localization of non-palpable breast lesions was first described in 1965 by Dodd and coworkers [16] and then refined by other surgeons, and currently this procedure is the most widely adopted approach, 80% in one survey, in guided breast-conserving surgery [17]. A thin hooked wire is inserted under local anesthesia, in order to localize the lesion to be excised, commonly under stereotactic or ultrasonographic guidance and alternatively by magnetic resonance imaging (MRI) or computerized tomography (CT). After insertion of the wire, a check mammogram is performed in two plans (mediolateral and cranio-caudal) to help visually orient the wire, and the associated lesion, for the surgeon (Fig. 6.1). The entire procedure can be performed immediately before the operation or the day before as the patient's planned surgery. This flexibility in the timing of wire insertion provides a clear advantage by reducing the pressure upon scheduling conflicts between the radiology department and operating theaters and therefore resource management on the day of surgery; however, it collides with the likely discomfort felt by the patient due to the presence of a foreign body into the breast, the possibility of wire migration, and the injury associated with barbs.

6.2.1 Indications

Despite some key disadvantages of the procedure such as the presence of a foreign body at pathological assessment, the possible wire transaction or migration, the patient discomfort especially if the procedure is done the day before the operation, and the interference with the surgical approach [18], WGL has had a considerable spread over the years, becoming the standard of care in several institutions although overall uptake has been slow.

It is indicated in the presence of non-palpable breast lesions or clusters of microcalcifications or parenchymal distortion. This method could be also applied in the case of multicentric and multifocal lesions [19], in case of diffuse microcalcifications or in presence of retroareolar lesions.

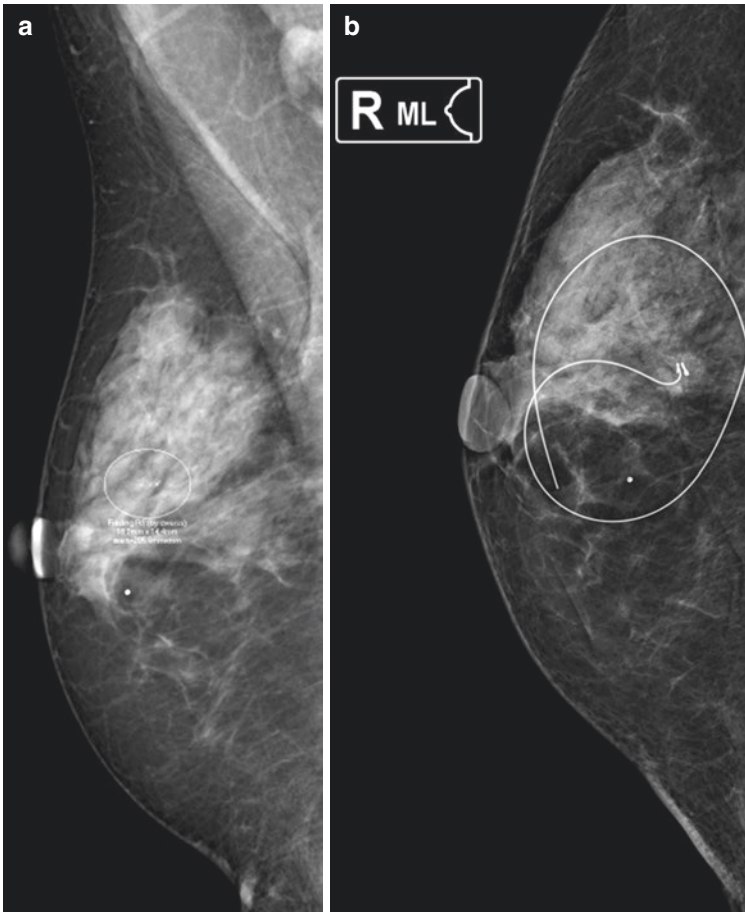
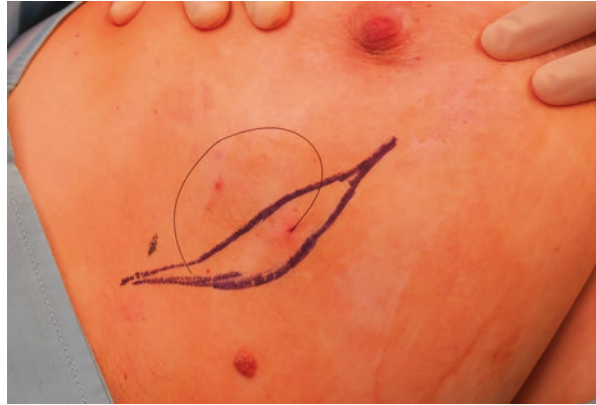

Fig. 6.1 A mammogram demonstrating a non-palpable cluster of microcalcifications in the outer quadrant of the breast (a) and a second mammogram demonstrating the position of the wire located adjacent to the clip left in place after the vacuum-assisted biopsy (b). Microcalcifications (b) non-palpable node

6.2.2 Description of the Surgical Procedure

Once the non-palpable breast lesion is localized with the hooked wire, in order to facilitate incision placement, images should be sent to the operative room with wire entry site indicated on them. The localization wire has the potential to migrate at many stages prior to and during surgery when the patient changes position or when traction is applied by the surgeon. In addition, in cases of small lesions, precise localization of the target lesion may be difficult due to the thickness of the tip of the wire. Besides, there have been reports of wire transection occurring during the time of surgery.

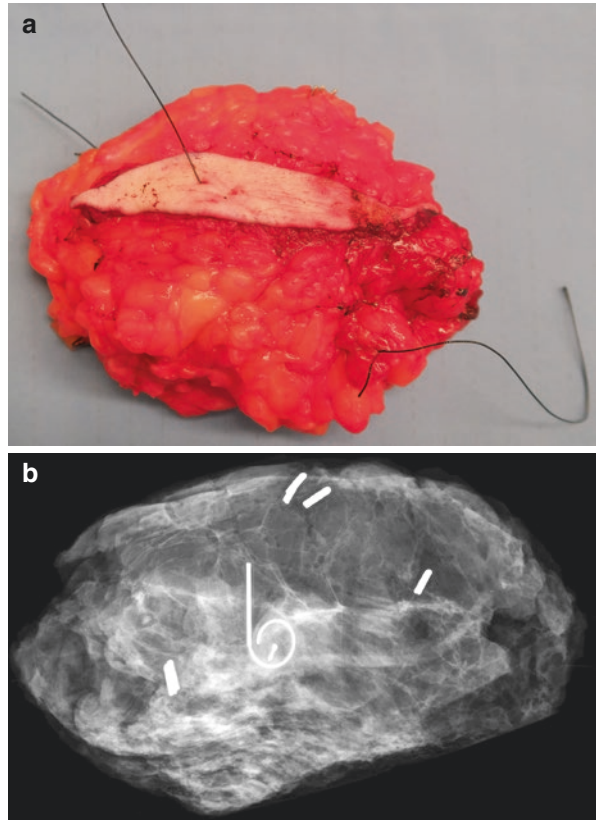
Fig. 6.2 Placement of incision is limited by the way the wire is inserted



Placement of incision is limited by the way the wire is inserted and may have an impact on the cosmetic outcome (Fig. 6.2). Therefore, the incision should be placed as directly as possible over the mass to minimize tunneling through breast tissue, but it should be noted that the insertion site of the wire on the skin may be remote from the ideal surgical incision in many cases, resulting in an undesirable incision and more extensive dissection to locate the lesion and wire tip [20]. With superficial lesions, the wire entry site is usually close to the lesion and thus may be included in the incision. With some deeper lesions, the wire entry site is on the shortest path to the lesion and so may still be included in the incision. Once the incision is made, a block of tissue is excised around and along the wire in such a way as to include the lesion. This process is easier and involves less excision of tissue if the localizing wire has a thickened segment several centimeters in length that is placed adjacent to or within the lesion. The wire itself can then be followed into breast tissue until the thick segment is reached, at which point the excision can be extended away from the wire to include the lesion in a fairly small tissue fragment. With many lesions, the wire entry site is in a fairly peripheral location relative to the position of the lesion, which means that including the wire entry site in the incision would result in excessive tunneling within breast tissue. In such cases, the incision is placed over the expected position of the lesion, the dissection is extended into breast tissue to identify the wire a few centimeters away from the lesion itself, and the free end of the wire is pulled up into the incision. A generous block of tissue is then excised around the wire. Intraoperative ultrasonography may be useful for identifying the tip of the needle and facilitating excision, particularly in the case of a deep lesion or biopsy site in a large breast.

At the end of the surgical procedure, a radiography should be performed intraoperatively on all wire-localized biopsy specimens to confirm the proper excision of the lesion (Fig. 6.3). If the lesion is missed, another tissue sample may be excised if the surgeon has some idea of the likely location of the missed lesion. In case of diffuse microcalcifications, if some of them are close to one margin at radiography, the surgeon has the possibility to remove more glands on that side in order to avoid positive excision margins with DCIS in mural edge. If, however, the

Fig. 6.3 A radiograph of the surgical specimen. The margins of the excised specimen were marked with surgical stitches (a) in order to better orient the X-ray (b). It shows the presence of the entire lesion in the middle of the excised tissue

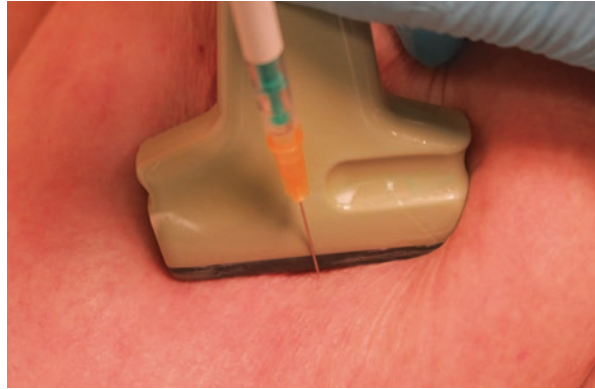


surgeon suspects that the wire was dislodged before or during the procedure, then the incision should be closed, and repeat localization and biopsy should be performed later.

6.3 ROLL Technique

In 1998, Luini and colleagues at the European Institute of Oncology in Milan [21] pioneered a new technique of localizing non-palpable breast lesions, and then it has been refined according to different modalities. This method derives its advantage from the accuracy in locating non-palpable lesions through an intralesional injection of a small amount of high-molecular-weight radioactive tracer, consisting of human serum albumin aggregates conjugated with technetium-99m. It is injected more frequently under ultrasound guidance (Fig. 6.4) but also by stereotactic guide, depending on whether nodes are ultrasonographically visible or microcalcifications are present at mammography or clips are left in place after mammotome biopsy. The size of albumin colloid is 100–150 μm in diameter in order to prevent migration of the radioactive tracer through the lymphatic path, ensuring its permanence in the

Fig. 6.4 The performance of the intratumoral injection of the radioactive tracer under ultrasound guidance



area of inoculum. The dose involves the injection of 99mTc -labelled colloid in 0.1 cm^3 followed by 0.1 cm^3 of air and by 1 cm^3 of iodinated water-soluble contrast if the injection is performed under stereotactic guide. The use of a proper probe for the detection of gamma radiations in the form of digital (strokes per second—sps) or acoustic signal enables the intraoperative localization of the inoculated and its precise surgical resection. ROLL requires localization to be performed within 24 h of surgery due to the 6 h half-life of 99mTc -labelled colloid [22], giving flexibility in the scheduling of the procedure and minimizing the discomfort of the patients.

6.3.1 Indications

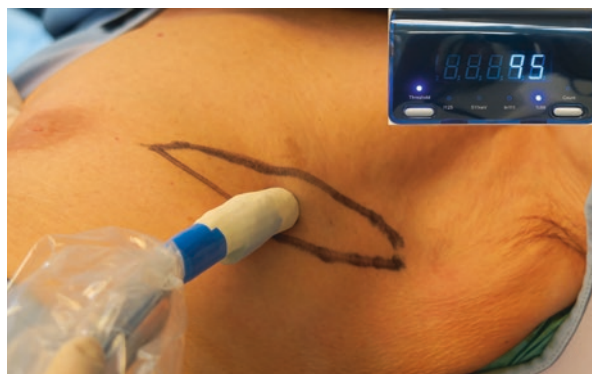In recent years, the ROLL has had an increasing application, so that it is, in many qualified centers, the technical of choice for surgical removal of non-palpable lesions of the breast.

The ROLL is currently indicated in the presence of non-palpable breast lesions detected by ultrasound or mammographic examination, such as clusters of microcalcifications, small opacities with spiculated or irregular margins, parenchymal distortion, and radial scars. This method is not however applied in the case of multicentric and multifocal lesions, in case of diffuse microcalcifications, or in presence of retroareolar lesions for possible radioactive contamination of the ducts.

6.3.2 Description of the Surgical Procedure

ROLL is a composite multidisciplinary procedure based on several connected steps and therefore there are many specialized skills involved in the procedure. First of all, the inoculation of the 99mTc -labelled colloid is performed by nuclear medicine in collaboration with the radiologist inside the lesion or in the area corresponding to the microcalcifications or near the clip. Then, a breast scintigram in anterior-posterior and lateral projections performed after the injection is mandatory to verify

Fig. 6.5 Intraoperative use of the handheld gamma probe, inserted in a sterile sheath, in order to confirm the presence of radioactive peak counts on the skin to determine the appropriate incision



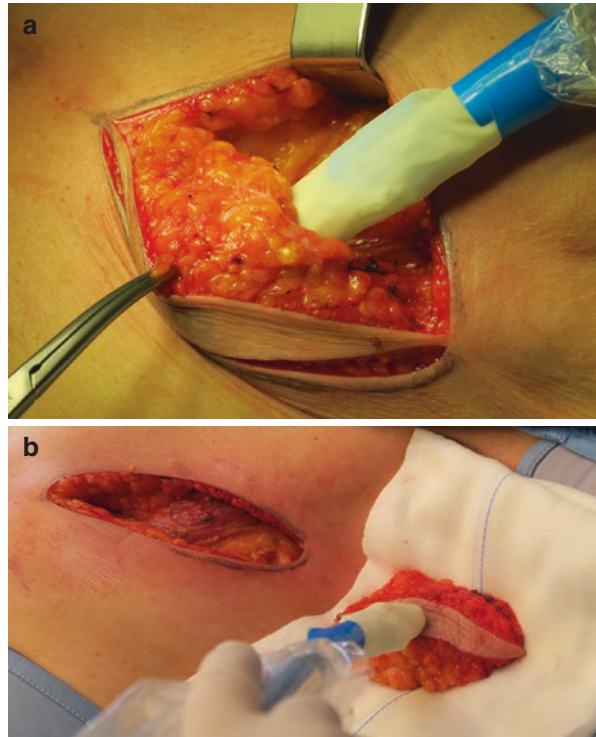
the proper and punctiform centering of the lesion with reference to the nipple, the inframammary fold, and the axilla. Moreover, any possible spills with skin contamination must be highlighted as well as any possible intraductal or intravascular spread that could make difficult or impossible the identification and then the excision of the centered lesion [18].

The equipment used in the operative room for the excision of the breast lesion involves the application of a radioactivity detector—handheld gamma probe—in the form of a metal cylinder containing inside a scintillator crystal capable of detecting gamma radiations emitted by ^{99m}Tc previously inoculated and transforming them into an electrical signal. The probe is connected by wire or by Bluetooth to an external digital reader that allows to convert the detected radioactivity both into a digital signal (sps) readable on a display and into an acoustic signal with an intensity and frequency proportional to the radioactivity captured over the investigated area [21].

In the operating room, even before preparation of the surgical field, the probe can be passed slowly by the surgeon over the surface of the breast in a perpendicular fashion; this maneuver allows to locate the orthogonal projection of the lesion itself on the skin and the surgeon can highlight it with a skin-marker pencil. In this way, the surgeon can choose the more appropriate surgical incision according to the position of the lesion (Fig. 6.5). In fact, depending on the location and the lesion characteristics (size, suspicion of malignancy), and the size and shape of the breast, skin incisions can be performed radial or arched. Radial incisions are generally preferred in case of intraductal calcifications, highly suspicious lesions, and lesions located in the lower quadrants of the breast, while arched incisions are mostly preferred for lesions located in the upper quadrants because they provide a better cosmetic result. Incisions around the nipple, with an excellent aesthetic result, are preferred, if possible, for all benign lesions.

Once the incision has been performed, the probe, inserted in a sterile sheath, allows to identify the area with higher signal intensity, thus indicating the direction in which surgical resection should be performed. Moving the probe slowly, the surgeon can verify that the higher acoustic signal intensity is always at the center of the specimen being excised, maintaining a look on the surgical field constantly.

Fig. 6.6 The surgeon used the gamma probe to confirm that the radioactive hotspot was centrally located within the excision specimen (a) and, once the specimen was excised, the surgeon used the gamma probe to ensure that maximal radioactivity with a rapid fall in gamma signal intensity was confined within the specimen (b)



Therefore, the surgeon is able to precisely identify the area with the highest intensity of the acoustic signal and guide the surgical resection around it (Fig. 6.6). When the excision is completed, the probe can immediately verify the absence of residual signal on the surgical field, proving that the lesion was completely removed; if there is residual radioactivity, the surgeons have the possibility to enlarge the margins of resection.

An X-ray of the surgical specimen must always be performed in order to confirm the actual presence of the non-palpable lesion or the clip or the cluster microcalcifications in the excised piece and to assess the extent of surgical resection margins and the possibility of proceeding to enlarge the resection. Moreover, the specimen should be oriented, defining the surgical margins with clips or stitches in order to make the pathologist's task easier.

6.4 Alternative Methods of Localization

6.4.1 Radioactive-Seed Localization

In contrast to ROLL, radioactive seed localization (RSL) involves percutaneous injection of a small titanium seed (with a size of 4 mm by 0.8 mm) radiolabelled with ^{125}I into the non-palpable lesion under either stereotactic or ultrasound

guidance via a standard 18-gauge needle. At surgery, the gamma probe is guided to the focal hotspot on the skin directly overlying the lesion. Once an incision is made at this location, the gamma probe is used to detect the distance from the dissection plane to the seed and to ensure that the excised specimen contains the radioactive hotspot; intraoperative radiography can also be used to provide further visible confirmation. In RSL, however, because a radiolabelled titanium seed is used for localization (instead of radiocolloid), a separate injection of radiocolloid that can migrate to the axillary nodes is necessary for the performance of sentinel lymph node biopsy.

Several advantages and limitations are associated with RSL technique. ROLL needs to be performed within 24 h before surgery because of the short (6 h) half-life of the radiolabelled colloid (^{99m}Tc), whereas RSL is generally performed within 5 days before surgery [23, 24] because the half-life of ^{125}I is 60 days [25, 26]. This flexibility in the timing of seed insertion in RSL provides a clear advantage of this technique over ROLL by reducing the time pressure on the radiology department and operating theaters, thereby enabling better resource management on the day of surgery [27]. Concern over migration and subsequent loss of inserted seeds has been raised in RSL procedures, but clinically relevant seed migration is rare and has been reported in less than 1% of patients [28].

6.4.2 Ultrasound-Guided Surgery

Ultrasonographic imaging has been used for interventional purposes to acquire histological diagnosis using core biopsies and also for preoperative placement of wires for non-palpable lesion localization [26, 29]. With advancements in ultrasonography technology, by reducing the size of scanners, enhancing their portability, and improving imaging quality, and with the increased use of ultrasonography by breast surgeons, patients with lesions that are visible on ultrasonographic images can now undergo excision guided by intraoperative ultrasound (IOUS) without the need of preoperative localization [30]. Despite the aforementioned data, current evidence on IOUS has limitations owing to the lack of data from large RCTs comparing IOUS to the standard WGL in the published meta-analyses. Although no significant difference was found in the distribution of in situ disease between treatment groups, only one small RCT [31] comprising 49 patients (26 in the IOUS group versus 23 in WGL group) was included in the meta-analysis [29], and the remaining cohort-controlled studies had differences in potential confounding factors between groups. Therefore, the risk of selection bias toward less defined in situ malignancy being excluded from the IOUS group and the WGL group was not identified [29]. The lack of data from RCTs of non-palpable breast cancer, combined with a lack of long-term oncological outcomes from large series, is prohibitive in gaining insightful conclusions about the efficacy of IOUS in this disease. Another major limitation to the widespread implementation of IOUS has been the ability of surgeons to acquire formal training and accreditation in breast ultrasonography. The successful application of IOUS is dependent on expertise in the technique and experience in the use of ultrasonography during tumor excision.

6.5 Discussion

Widespread use of diagnostic breast imaging and screening programs has revolutionarily changed the diagnosis of breast cancer: this has directly resulted in a substantial increase in the number of diagnosed breast cancers which are clinically non-palpable, and, accordingly, the technology to deal with these lesions has developed commensurately.

However, as DCIS is being detected as radiographic lesions only, the need for image-guided localization of non-palpable breast lesions prior to surgical excision emerged, and identifying the presence and extent of a carcinoma in situ component is more difficult using standard clinical or radiological techniques than in isolated invasive disease. Primary breast-conserving surgery may therefore result in incomplete excision of cancer or inadequate clearance margins, which both typically require women to have reoperation to the breast. In a recent retrospective study among women who have undergone breast-conserving surgery in England, the authors found that the reoperation rates differed between women with and without carcinoma in situ. In particular one in five women who had breast-conserving surgery had a reoperation, but reoperation was nearly twice as likely when the tumor had a carcinoma in situ component associated [32].

Furthermore, margin of excision is an important prognostic indicator, because positive surgical margins are consistently associated with increased DCIS and invasive breast cancer recurrence, although the magnitude of excess risk varies considerably [33, 34]. There is considerable debate, however, regarding whether width of a negative margin is associated with a decreased risk of recurrence, and classification of the margins makes summary statements difficult. Nevertheless, the EORTC DCIS trial [35], where 503 patients after local excision were randomized to observation without any further treatment and 507 patients were randomized to postoperative intact breast radiotherapy after the local excision, reported a high local recurrence rate of 36% at 10 years in patients with close or involved margins compared to those with clear margin (15% at 10 years) irrespective of the use of radiotherapy.

Based on the aforementioned considerations, the debate regarding which technique should be preferred is still a matter of discussion. Owing to a lack of trials in various localization techniques, such as IOUS, and a less adoption of RSL in the standard practice, we can only draw our analysis over WGL and ROLL. The first randomized clinical trial (RCT) comparing WGL and ROLL was published in 2004 by Rampaul and coworkers. This small study randomized 95 patients to receive ROLL or WGL [36] and demonstrated no significant difference between groups when comparing duration of surgery, specimen weight, or the need for intraoperative re-excision. Moreover, there was no statistical difference between the accuracy of marking and duration of localization procedure; however, notably, radiologists found ROLL technically easier to perform than WGL. Since then, several other studies have been published. All RCTs included in situ disease in their inclusion criteria, and in the randomization process, the number of invasive and in situ lesions among patients who underwent wire-guided or radio-guided

localization did not differ significantly [20, 36–41]. The small cohort sizes and the lack of power calculations for sample sizes also weakened the conclusions from these studies [36–38, 40, 41].

However, despite these limitations current literature consistently demonstrates that technically high success rates can be achieved with the use of both techniques. More in details, a meta-analysis of seven RCTs identified a significant difference between the two techniques, favoring use of radio-guided surgery for shorter operating times, but at the expense of a significantly greater volume of tissue excised [42]. In particular, the study by Postma et al. [39] reported a significant increase in volume of tissue excised in the radio-guided group compared with the WGL group, with median values of 71 cm³ (range 50–101 cm³) and 64 cm³ (range 39–91 cm³), respectively ($P = 0.02$), but the increase in volume excised did not translate into a significant difference in cosmetic outcome between the two groups ($P = 0.55$). This result suggests that the difference in volumes excised between the two techniques is likely to have a negligible impact on cosmetic appearance but must be assessed in future trials [43].

More recently, Chan and coworkers [44] performed a detailed Cochrane review identifying six randomized controlled trials [20, 36–40] that compared ROLL versus WGL and confirmed the same results, summarized in Table 6.1. In details, ROLL demonstrated favorable results, summarized in Table 6.1, in successful localization, positive tumor margins, and reoperation rate versus WGL, but none of these results were statistically significant. In contrast, WGL had fewer postoperative complications to ROLL, although this was also not statistically significant.

Due to current financial constraints in world healthcare system, it is very important to consider the economic impact of these two techniques. Postma et al. [45] in their comprehensive cost–benefit analysis of their RCT between ROLL and WGL found that there was no economic difference between the two techniques when considered overall in terms of costs associated with morbidity and reoperation rates. Interestingly, they found that ROLL was even better than WGL in terms of costs associated with localization because it allowed radioisotope injection for sentinel lymph node biopsy to be performed concurrently with localization as opposed to WGL which required an additional procedure to localization.

Another important aspect that needs to be considered is the issue of learning curves associated with ROLL and WGL. Certainly, studies comparing ROLL to WGL have suggested that surgeons favored the radio-guided technique over WGL in terms of ease of performance [36, 40], even if the issue of a learning curve

Table 6.1 Comparison in terms of outcomes between ROLL and WGL

Outcomes	No. of studies	No. of participants	Risk ratio [95% CI]
Localization complication	6	869	0.60 [0.16, 2.28]
Successful excision	6	871	1.00 [0.99, 1.01]
Positive margins	5	517	0.74 [0.42, 1.29]
Reoperation rate	4	583	0.51 [0.21, 1.23]
Postoperative complications	4	642	1.18 [0.71, 1.98]

associated with ROLL has never been formally assessed within the published evidence. However, the largest published cohort series for ROLL [46] did not suggest the presence of a significant learning curve, prompting that ROLL is intuitive and the necessary skills easily acquired.

Conclusions

Currently WGL is the most widely adopted approach for localizing non-palpable breast lesions and DCIS for surgical excision. Although ROLL has proven to be competitively priced in comparison with WGL, to have no significant learning curves for surgeons, and to have several advantages, it cannot entirely replace WGL for large breast lesions. Problems have been reported with ROLL when used for stereotactic-guided procedures: the radiotracer is not visible on mammograms and localization under stereotactic guidance is therefore difficult to perform. Moreover, errors in depth secondary to compressed breast tissue have resulted in inaccurate injection of the radiotracer [47]. This can cause potential problems in patients with small breast cup sizes as the release of pressure following stereotaxis has resulted in leakage of the radiotracer into neighboring breast quadrants [48]. Lastly, in cases of extensive microcalcifications in the breast, the placement of several wires may be the preferable localization technique.

Nevertheless, ROLL can be offered to patients as a comparable replacement for WGL as it is equally reliable. Moreover, ROLL supporters claim a much higher flexibility of this technique, which allows approaching all breast quadrants through cosmetic incisions. This differs from WGL, which inevitably has to rely on the track of the wire as inserted by the radiologist.

References

1. Ferlay J, Autier P, Boniol M, Heanue M, Colombet M, Boyle P. Estimates of the cancer incidence and mortality in Europe in 2006. *Ann Oncol.* 2007;18:581–92.
2. Bleyer A, Welch HG. Effect of three decades of screening mammography on breast-cancer incidence. *N Engl J Med.* 2012;367:1998–2005.
3. Cady B, Stone MD, Schuler JG, Thakur R, Wanner MA, Lavin PT. The new era in breast cancer. Invasion, size and nodal involvement dramatically decreasing as a result of mammographic screening. *Arch Surg.* 1996;131:301–8.
4. Altekruse SF, Kosary CL, Krapcho M, et al. SEER cancer statistic review, 1975–2007. Bethesda: National Cancer Institute; 2010.
5. Lovrics PJ, Cornacchi SD, Farrokhyar F, Garnett A, Chen V, Franic S, Simunovic M. The relationship between surgical factors and margin status after breast-conservation surgery for early stage breast cancer. *Am J Surg.* 2009;197:740–6.
6. Siegel RL, Miller KD, Jemal A. Cancer statistics, 2015. *CA Cancer J Clin.* 2015;65:5–29.
7. Gillis DA, Dockerty MB, Clagett OT. Pre-invasive intraductal carcinoma of the breast. *Surg Gynecol Obstet.* 1960;110:555–62.
8. Sakorafas GH, Farley DR, Peros G. Recent advances and current controversies in the management of DCIS of the breast. *Cancer Treat Rev.* 2008;34:483–97.
9. Ernster VL, Ballard-Barbash R, Barlow WE, Zheng Y, Weaver DL, Cutter G, Yankaskas BC, Rosenberg R, Carney PA, Kerlikowske K, Taplin SH, Urban N, Geller BM. Detection of

- ductal carcinoma in situ in women undergoing screening mammography. *J Natl Cancer Inst.* 2002;94:1546–54.
10. Burstein HJ, Polyak K, Wong JS, Lester SC, Kaelin CM. Ductal carcinoma in situ of the breast. *N Engl J Med.* 2004;350:1430–41.
 11. Choi DX, Van Zee KJ. Memorial Sloan-Kettering Cancer Center: two decades of experience with ductal carcinoma in situ of the breast. *Int J Surg Oncol.* 2012;2012:723916.
 12. van Riet YE, Jansen FH, van Beek M, van de Velde CJ, Rutten HJ, Nieuwenhuijzen GA. Localization of non-palpable breast cancer using a radiolabelled titanium seed. *Br J Surg.* 2010;97:1240–5.
 13. Zgajnar J, Hocevar M, Frkovic-Grazio S, et al. Radioguided occult lesion localization (ROLL) of the non palpable breast lesions. *Neoplasma.* 2004;51:385–9.
 14. Altomare V, Guerriero G, Giacomelli L, Battista C, Carino R, Montesano M, Vaccaro D, Rabitti C. Management of nonpalpable breast lesions in a modern functional breast unit. *Breast Cancer Res Treat.* 2005;93:85–9.
 15. Ramesh HS, Anguille S, Chagla LS, Harris O, Desmond S, Thind R, Audisio RA. Recurrence after ROLL lumpectomy for invasive breast cancer. *Breast.* 2008;17:637–9.
 16. Dodd GD, Fry K, Delany W. Pre-operative localization of occult carcinoma of the breast. In: Nealon TF, editor. *Management of the patient with breast cancer.* Philadelphia: WB Saunders; 1965. p. 88–113.
 17. Van Esser S, Hobbelink M, Van der Ploeg IM, Mali WP, Van Diest PJ, Borel Rinkes IH, Van Hillegersberg R. Radio guided occult lesion localization (ROLL) for non-palpable invasive breast cancer. *J Surg Oncol.* 2008;98:526–9.
 18. De Cicco C, Pizzamiglio M, Trifiro G, Luini A, Ferrari M, Prisco G, Galimberti V, Cassano E, Viale G, Intra M, Veronesi P, Paganelli G. Radioguided occult lesion localisation (ROLL) and surgical biopsy in breast cancer. Technical aspects. *Q J Nucl Med.* 2002;46:145–51.
 19. Rose A, Collins JP, Neerhut P, Bishop CV, Mann GB. Carbon localisation of impalpable breast lesions. *Breast.* 2003;12:264–9.
 20. A MM, Solà M, de Tudela AP, Julián JF, Fraile M, Vizcaya S, Fernández J. Radioguided localization of nonpalpable breast cancer lesions: randomized comparison with wire localization in patients undergoing conservative surgery and sentinel node biopsy. *AJR Am J Roentgenol.* 2009;193:1001–9.
 21. Luini A, Zurrada S, Galimberti V, Paganelli G. Radioguided surgery of occult breast lesions. *Eur J Cancer.* 1998;34:204–5.
 22. McGhan LJ, McKeever SC, Pockaj BA, Wasif N, Giurescu ME, Walton HA, Gray RJ. Radioactive seed localization for nonpalpable breast lesions: review of 1,000 consecutive procedures at a single institution. *Ann Surg Oncol.* 2011;18:3096–101.
 23. Gray RJ, Pockaj BA, Karstaedt PJ, Roarke MC. Radioactive seed localization of nonpalpable breast lesions is better than wire localization. *Am J Surg.* 2004;188:377–80.
 24. Hughes JH, Mason MC, Gray RJ, McLaughlin SA, Degnim AC, Fulmer JT, Pockaj BA, Karstaedt PJ, Roarke MC. A multi-site validation trial of radioactive seed localization as an alternative to wire localization. *Breast J.* 2008;14:153–7.
 25. Gobardhan PD, de Wall LL, van der Laan L, ten Tije AJ, van der Meer DC, Tetteroo E, Poortmans PM, Luiten EJ. The role of radioactive iodine-125 seed localization in breast-conserving therapy following neoadjuvant chemotherapy. *Ann Oncol.* 2013;24:668–73.
 26. Ahmed M, Rubio IT, Klaase JM, Douek M. Surgical treatment of nonpalpable primary invasive and in situ breast cancer. *Nat Rev Clin Oncol.* 2015;12:645–63.
 27. Ahmed M, Douek M. Radioactive seed localisation (RSL) in the treatment of non-palpable breast cancers: systematic review and meta-analysis. *Breast.* 2013;22:383–8.
 28. Barentsz MW, van den Bosch MA, Veldhuis WB, van Diest PJ, Pijnappel RM, Witkamp AJ, Verkooijen HM. Radioactive seed localization for non-palpable breast cancer. *Br J Surg.* 2013;100:582–8.
 29. Ahmed M, Douek M. Intra-operative ultrasound versus wire-guided localization in the surgical management of non-palpable breast cancers: systematic review and meta-analysis. *Breast Cancer Res Treat.* 2013;140:435–46.

30. Ahmed M, Abdullah N, Cawthorn S, Usiskin SI, Douek M. Why should breast surgeons use ultrasound? *Breast Cancer Res Treat.* 2014;145:1–4.
31. Rahusen FD, Taets van Amerongen AH, van Diest PJ, Borgstein PJ, Bleichrodt RP, Meijer S. Ultrasound-guided lumpectomy of nonpalpable breast cancers: a feasibility study looking at the accuracy of obtained margins. *J Surg Oncol.* 1999;72:72–6.
32. Jeevan R, Cromwell DA, Trivella M, Lawrence G, Kearins O, Pereira J, Sheppard C, Caddy CM, van der Meulen JH. Reoperation rates after breast conserving surgery for breast cancer among women in England: retrospective study of hospital episode statistics. *BMJ.* 2012;345:e4505.
33. Warren JL, Weaver DL, Bocklage T, Key CR, Platz CE, Cronin KA, Ballard-Barbash R, Willey SC, Harlan LC. The frequency of ipsilateral second tumors after breast-conserving surgery for DCIS: a population based analysis. *Cancer.* 2005;104:1840–8.
34. Fisher B, Land S, Mamounas E, Dignam J, Fisher ER, Wolmark N. Prevention of invasive breast cancer in women with ductal carcinoma in situ: an update of the National Surgical Adjuvant Breast and Bowel Project experience. *Semin Oncol.* 2001;28:400–18.
35. EORTC Breast Cancer Cooperative Group, EORTC Radiotherapy Group, Bijker N, Meijnen P, Peterse JL, Bogaerts J, Van Hoorebeeck I, Julien JP, Gennaro M, Rouanet P, Avril A, Fentiman IS, Bartelink H, Rutgers EJ. Breast-conserving treatment with or without radiotherapy in ductal carcinoma-in-situ: ten-year results of European Organisation for Research and Treatment of Cancer randomized phase III trial 10853—a study by the EORTC Breast Cancer Cooperative Group and EORTC Radiotherapy Group. *J Clin Oncol.* 2006;24:3381–7.
36. Rampaul RS, Bagnall M, Burrell H, Pinder SE, Evans AJ, Macmillan RD. Randomized clinical trial comparing radioisotope occult lesion localization and wire-guided excision for biopsy of occult breast lesions. *Br J Surg.* 2004;91:1575–7.
37. Medina-Franco H, Abarca-Pérez L, García-Alvarez MN, Ulloa-Gómez JL, Romero-Trejo C, Sepúlveda-Méndez J. Radioguided occult lesion localization (ROLL) versus wire-guided lumpectomy for non-palpable breast lesions: a randomized prospective evaluation. *J Surg Oncol.* 2008;97:108–11.
38. Ocal K, Dag A, Turkmenoglu O, Gunay EC, Yucel E, Duce MN. Radioguided occult lesion localization versus wire-guided localization for non-palpable breast lesions: randomized controlled trial. *Clinics (Sao Paulo).* 2011;66:1003–7.
39. Postma EL, Verkooijen HM, van Esser S, Hobbelink MG, van der Schelling GP, Koelemij R, Witkamp AJ, Contant C, van Diest PJ, Willems SM, Borel Rinkes IH, van den Bosch MA, Mali WP, van Hillegersberg R, ROLL study group. Efficacy of ‘radioguided occult lesion localisation’ (ROLL) versus ‘wire-guided localisation’ (WGL) in breast conserving surgery for non-palpable breast cancer: a randomised controlled multicentre trial. *Breast Cancer Res Treat.* 2012;136:469–78.
40. Lovrics PJ, Goldsmith CH, Hodgson N, McCreedy D, Gohla G, Boylan C, Cornacchi S, Reedijk M. A multicentered, randomized, controlled trial comparing radioguided seed localization to standard wire localization for nonpalpable, invasive and in situ breast carcinomas. *Ann Surg Oncol.* 2011;18:3407–14.
41. Moreno M, Wiltgen JE, Bodanese B, Schmitt RL, Gutfilen B, da Fonseca LM. Radioguided breast surgery for occult lesion localization - correlation between two methods. *J Exp Clin Cancer Res.* 2008;27:29.
42. Ahmed M, van Hemelrijck M, Douek M. Systematic review of radioguided versus wire-guided localization in the treatment of non-palpable breast cancers. *Breast Cancer Res Treat.* 2013;140:241–52.
43. Ahmed M. Significance of the volume of excised specimens in radio guided occult lesion localization (ROLL). *J Surg Oncol.* 2013;107:874.
44. Chan BK, Wiseberg-Firtell JA, Jois RH, Jensen K, Audisio RA. Localization techniques for guided surgical excision of non-palpable breast lesions. *Cochrane Database Syst Rev.* 2015;(12):CD009206.
45. Postma EL, Koffijberg H, Verkooijen HM, Witkamp AJ, van den Bosch MA, van Hillegersberg R. Cost-effectiveness of radioguided occult lesion localization (ROLL) versus wire-guided

- localization (WGL) in breast conserving surgery for nonpalpable breast cancer: results from a randomized controlled multicenter trial. *Ann Surg Oncol.* 2013;20:2219–26.
46. Monti S, Galimberti V, Trifiro G, De Cicco C, Peradze N, Brenelli F, Fernandez-Rodriguez J, Rotmensz N, Latronico A, Berrettini A, Mauri M, Machado L, Luini A, Paganelli G. Occult breast lesion localization plus sentinel node biopsy (SNOLL): experience with 959 patients at the European Institute of Oncology. *Ann Surg Oncol.* 2007;14:2928–31.
 47. Chu TY, Lui CY, Hung WK, Kei SK, Choi CL, Lam HS. Localisation of occult breast lesion: a comparative analysis of hookwire and radioguided procedures. *Hong Kong Med J.* 2010;16:367–72.
 48. Rampaul RS, MacMillan RD, Evans AJ. Intraductal injection of the breast: a potential pitfall of radioisotope occult lesion localization. *Br J Radiol.* 2003;76:425–6.

The Surgical Treatment of DCIS: from Local Excision to Conservative Breast Surgery and Conservative Mastectomies

7

Carlo Mariotti and Eugenia Raffaelli

7.1 The Evolution of Surgical Treatment for DCIS: From Silverstein to Current Guidelines

Before the era of mammography, DCIS was an infrequent find and diagnosis was mainly clinical: it showed itself as palpable mass, nipple bloody discharge, or Paget's disease of NAC [1, 2]. Surgeons were dealing with large DCIS, for whose the only surgical option was radical (traditional or modified) mastectomy (that was, at that time, the only operation considered oncologically safe); reconstruction was never performed, resulting in considerable cosmetic mutilation. Development and diffusion of mammography led to a critical change in this trend: at the time of diagnosis, DCIS became increasingly small. In the meantime, the success of breast-conserving surgery (BCS), which was proved safe for DCIS [3], brought to a decrease in the use of mastectomy for this type of breast neoplasm: today, 75% of ductal carcinomas in situ are treated with BCS [4], and the few cases of mastectomy are followed by breast reconstruction. Once clinical trials proved the oncological safety of all the surgical options cited above, attention was focused on the factors that would influence recurrence rate in DCIS, because recurrence is invasive in 50% of cases and 10–20% of invasive recurrences become metastatic [5–7]. Over the years, several predictive factors for recurrence were identified (age [8–10], family history, BRCA gene mutation, clinical presentation, nuclear grade [8, 9], histological subtype, comedo necrosis, size [8, 9], margin status [8, 9], radiotherapy [11], systemic therapy [12]). In 1996, Silverstein identified the most important predictive factors and combined them in an algorithm, the Van Nuys Prognostic Index, in order to identify the most suitable treatment for every single DCIS. Basing on size, margin status, histological features, and patient's age, the recommended treatment

C. Mariotti (✉) • E. Raffaelli
Department of Oncology and Robotic Surgery,
Breast Surgery Unit, AOU Careggi, Firenze, Italy
e-mail: mariotticarlo@alice.it; eugenia.raffaelli@gmail.com

Score	Size	Margin	Histology	Age
1	< 16 mm	> 10 mm	Nuclear grade 1-2 without necrosis	> 60 yy
2	16 – 40 mm	1 – 10 mm	Nuclear grade 1-2 with necrosis	40-60 yy
3	> 40 mm	< 1 mm	Nuclear grade 3	< 40 yy

VPNI score	Recommended Treatment
4-6	Excision only
7-9	Excision + RT
10-12	Mastectomy

Fig. 7.1 Van Nuys Prognostic Index

could be excision alone (VPNI score 4–6), excision followed by adjuvant radiotherapy (VPNI score 7–9), or mastectomy (VPNI score 10–12) (see Fig. 7.1).

Basing on Silverstein’s and other authors’ following studies, at present, the most important factor in DCIS surgical treatment is margin status. According to current guidelines, whatever operation able to remove the entire DCIS without margin involvement is considered appropriate. The debate concerns the meaning of “margin involvement”: according to Morrow et al., margin is positive if ink is present on tumor [13]; according to NCCN guidelines, reoperation should be performed if distance between tumor and margin is <1 mm [14].

7.2 Choice of the Operation

7.2.1 Anamnesis

Anamnesis has a key role in treatment selection because it allows the identification of contraindications, risk factors for recurrence, and predictive factors for cosmetic outcome and patient’s satisfaction. Questions should focus on:

- *Age*. DCIS presents a higher recurrence rate in women >60 [8, 9]; comorbidities of the elderly may represent relative or absolute contraindications for procedures such as general anesthesia, radiotherapy, or reconstruction.
- *Family history*. DCIS recurrence is more frequent in patients with family history of breast cancer.

- *Hereditary Neoplastic Syndrome (BRCA mutation or others)*. If there is a suspect of a hereditary breast and ovarian cancer syndrome (multiple close relatives with BC, BC in males, bilateral BC, ovarian cancer, BC in young patient) in a DCIS patient, she should be sent for genetic counseling. If a DCIS arises in a woman with a proven genetic mutation, a bilateral mastectomy should be considered.
- *Personal history of breast cancer*. Previous breast surgery may influence the selection of operation in different ways: surgical (modified breast vascularization), aesthetical (symmetry), psychological (patients with propensity for mastectomy), and oncological factors (high-risk breast) play a role.
- *Previous radiotherapy*. RT represents a contraindication to breast-conserving therapy (BCT), because it implies a new breast irradiation in most cases.
- *Other contraindications to radiotherapy*. Some cardiovascular and lung diseases contraindicate radiotherapy [15–19], which is part of BCT in most of cases.
- *Psychological aspects*. If more than one surgical option is feasible and the patient has been accurately informed, treatment selection should be based on patient's will (refusal of mastectomy or, on the other hand, request for a more radical operation).

7.2.2 Physical Examination

The vast majority of DCIS is clinically silent; it might in rare cases show itself as a palpable mass or through nipple discharge. Once the presence of suspect finds is ruled out, the breast physical examination of patients with DCIS focuses on the pinpointing of aesthetic outcome predictive factors:

- *Breast volume*. Both small and large volumes pose problems in obtaining aesthetically acceptable symmetry after surgery. If, on one hand, a small breast is not suitable for undergoing conservative surgery (as the resulting asymmetry would be unacceptable), on the other mastectomy can pose reconstructive problems (as even the smallest prosthesis can be too large compared to the contralateral breast in the presence of small volumes); in such case, contralateral symmetrization can be opted for. Large volumes do not pose problems as far as conservative surgery is concerned, as residual asymmetry is either low or imperceptible; however, should mastectomy be recommended, the reconstructive outcome can hardly replicate the contralateral breast, which is therefore often symmetrized (i.e., reduction mammoplasty).
- *Breast ptosis*. As breast ptosis is difficult to replicate, the problems it poses involve not so much conservative surgery as post-mastectomy reconstruction; symmetrization can be opted for also in this case (i.e., mastopexy).

7.2.3 Radiology

Correct presurgery radiological characterization is one of the key points for intraductal carcinoma conservative surgery to be successful, which means obtaining a negative margin. Detailed information on the following aspects is required:

- *Location*
- *Size*. The ratio between neoplasm and breast size is important when choosing what type of surgery the patient is to undergo; performing quadrantectomy on a patient whose ratio is high can affect oncological radicality (margins affected due to inadequate resection) or aesthetic outcomes (symmetry is affected if overly extended quadrantectomy is performed).
- *Morphological features*. The presence of a nodular image within the framework of a DCIS-compatible radiological find can indicate an infiltration focus; such parameter does not greatly influence the choice between quadrantectomy and mastectomy; however, it is to be taken into consideration when choosing whether to perform a sentinel lymph node biopsy in the DCIS.
- *Multifocality and multicentricity*. The presence of multifocality and especially multicentricity contraindicates conservative surgery.

Each of the breast medical imaging methodologies plays a role in characterizing intraductal carcinoma.

- *Mammography*. Examining mammography images is the first step toward the planning of surgery, as it enables the assessment of DCIS location, size, morphological features, multifocality, and multicentricity; microcalcification distribution guides the choice between mastectomy and conservative surgery, as well as that between the two types of conservative surgery (traditional quadrantectomy or oncoplastic surgery). However, mammography has one major limit as far as DCIS size assessment is concerned, as dimensional and topographic correspondence between microcalcifications and DCIS is far from exact: intraductal carcinoma can be larger (as calcifications only indicate necrosis areas within the neoplasm) or smaller (as lesions causing microcalcifications, such as sclerosing adenosis or papillomatosis [20], can be found on the margins of the DCIS); such phenomenon can mislead the surgeon, who still obtains a neoplasm-affected margin after planning surgery and carrying out the intraoperative radiological examination of the removed tissue.
- *Ultrasound*. Ultrasound has a minor role in the characterization of in situ ductal carcinoma, as the latter is often undetectable by ultrasounds. What is to be ruled out by use of ultrasound is the presence of nodular images suspected of infiltration, which indicate the need for a sentinel lymph node biopsy.
- *Nuclear magnetic resonance*. Resonance enables a better assessment of DCIS size and multicentricity and therefore leads to a lower risk of obtaining neoplasm-affected margins after conservative surgery.

7.2.4 Core Biopsy

Stereotactic-guided core biopsy followed by a histological examination is required in the presence of mammography-detected suspect microcalcifications. Anatomicopathological examinations, other than enabling diagnosis, provide indications on nuclear grade (considered by Silverstein as a predictive factor of local recurrence). Given the higher biological aggressiveness (in terms of progression toward invasive neoplasm) of DCIS with HER2 and basal-like phenotypes, the routine phenotypical characterization of in situ neoplasms could be useful in modulating therapeutic approach aggressiveness also based on biological characteristics [21].

7.3 The Problem of Intraoperative Identification

As DCIS develops inside ducts following the anatomy of the gland, it is macroscopically invisible and scarcely palpable, which leads to intraoperative difficulties in locating and defining its limits; therefore, the surgeon, when performing resection, is to rely on data collected prior to surgery rather than intraoperative palpation so as to define resection size, as the latter would mean adopting a blinkered approach and therefore increasing the risk of obtaining an inadequate margin. In order to maximize radical excision likelihood, the surgeon makes use of techniques enabling them to track down the location of the non-palpable lesion when operating and techniques enabling resection margin state to be assessed.

7.3.1 Non-palpable Lesion Localization

Non-palpable lesion localization encompasses all those methods enabling the tracking down of radiological finds lacking a clinical equivalent when operating, which is a feature of most intraductal carcinomas. There are several non-palpable lesion localization techniques, which are more thoroughly discussed in Chap. 6.

7.3.2 Intraoperative Margin Definition

Intraoperative margin definition would reduce the high reintervention rate (38–46%) [22, 23]; however, none of the proposed methods have proved significantly effective as of today; therefore DCIS intraoperative margin definition remains controversial.

- *Microscopic examination*: not useful, as a complete study of the margin would require a high number of samples and an amount of time not compatible with an intraoperative examination.

- *Macroscopic examination (visual and tactile)*: scarcely reliable because DCIS is macroscopically invisible and scarcely palpable.
- *Optical segmentation and confocal reflection microscopy*: based on the innate optical properties of inner breast tissues, especially collagen and adipose tissue; the identification of such tissues and their removal leads to the identification of epithelial tissue, which corresponds to tumor tissue. Based on the images obtained by use of such technology, the pathologist can easily pinpoint the areas running a higher risk of margin affection. Although the usefulness of optical segmentation in the study of the margin when carrying out the final histological examination has been proved [24], its intraoperative usefulness has not been proved as of yet.
- *Radiofrequency (MarginProbe®)*: consisting of a single-use probe and a console. The technology this device is based on enables the characterization of tissues and therefore the real-time identification of neoplasm areas at margin level. Studies [25] have shown the effectiveness of such device in reducing non-palpable lesion reintervention rates; however, the method is not used on a large scale yet.
- *Intraoperative X-ray*. Every time conservative surgery is performed due to a non-palpable mammography find, a radiological examination should be carried out on the surgical sample so as to verify the presence of the find inside the excised tissue and therefore reduce the reintervention rate. However, intraoperative X-rays are not completely reliable, as stated above, due to the size-morphology ratio between microcalcification areas and DCIS: the inclusion of all the microcalcifications inside the excised glandular portion does not always mean the intraductal carcinoma has been completely excised, as it may be larger than the mammography find. A study by Folli et al. indicated a 15 mm cutoff as the adequate radiological margin for the obtainment of surgical radicality [26] (Figs. 7.2 and 7.3).

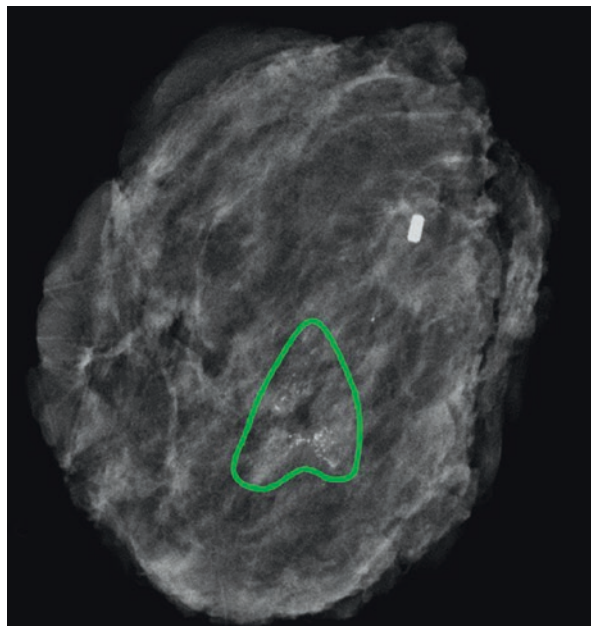


Fig. 7.2 Surgical sample X-ray showing the presence of the microcalcification cluster and the clip, which was left there during the performing of the stereotactic-guided core biopsy

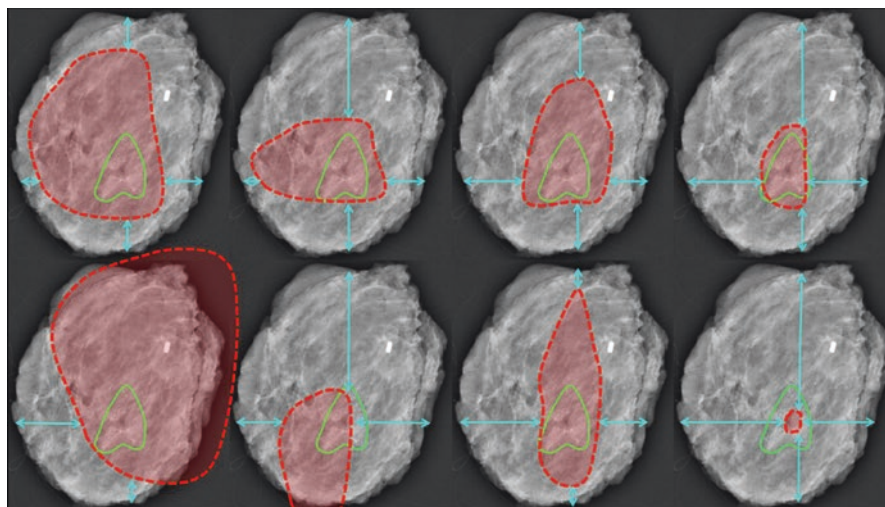


Fig. 7.3 Hypothetical size of possible intraductal carcinomas compared to the microcalcification area

7.4 The Surgical Techniques

Conservative Surgery	Lumpectomy	
	Traditional Quadrantectomy	
	Oncoplastic Surgery	
	BCS and Substitution with Autologous Tissue	Flaps Fat grafting
Mastectomies	Radical Mastectomies	Halsted
		Patey
		Madden
	Conservative Mastectomies	Nipple-Sparing Mastectomy
		Areola-Sparing Mastectomy
		Skin-Sparing Mastectomy
Skin-Reducing Mastectomy		

Surgical Piece Orientation

In the presence of DCIS-affected margins, knowing the target of the new resection is required (should a conservative reintervention be opted for). It is therefore paramount to maximize the correspondence between the orientation of the surgical piece in its bed and that which the pathologist's description is based on; in this framework, communication between surgeons and pathologists is facilitated by the intraoperative application of multiple adequately marked landmarks (sutures, clips) on the excised tissue. However, there is a high level of subjectivity in the interpretation of piece orientation by different pathologists.

7.4.1 Conservative Surgery

7.4.1.1 Lumpectomy

Lumpectomy is a safe surgical option for treatment of ductal carcinomas in situ with limited size. The operation involves the complete excision of the tumor with clear margins. It results in a minimal scar, no asymmetry, and an excellent cosmetic outcome.

7.4.1.2 Traditional Quadrantectomy

Traditional quadrantectomy is the standard surgical treatment for DCIS. It involves the excision of a section of breast parenchyma containing the tumor, together with the overlying skin. Skin incision varies depending on tumor localization (see Fig. 7.4); if DCIS arises in a quadrant at high risk of deformity (inner and inferior quadrants), the surgeon should opt for a different operation (lumpectomy or oncoplastic surgery, depending on tumor size). Glandular dissection occurs along a vertical or slightly oblique plane and reaches the muscular fascia. The specimen is then detached from the deep plane and removed. Glandular resections carried out for small tumors result in a minimal substance loss. In these cases, a simple glandular suture is sufficient for the obtainment of an excellent cosmetic outcome. If larger resections (up to 10% of breast tissue) are carried out, this approach might be insufficient, resulting in deformations; in these cases, it is advisable to create local glandular flaps by detaching both superficially (from the skin) and deeply (from the muscle fascia) the parenchyma adjacent to the substance loss.

7.4.1.3 Oncoplastic Surgery

Oncoplastic surgery includes various techniques; everyone of each is useful for a precise breast cancer localization in a precise breast type (in terms of volume and ptosis). The different proposed classifications of operations reflect the variety of opinions and experiences among authors and have mainly a didactic purpose. Yang's group, in Korea, proposed a classification based on the size of excised breast tissue, which is directly related to the technique of breast reconstruction: transposition of residual breast tissue (*volume displacement* techniques) or use of other autologous

Fig. 7.4 Skin incisions in traditional quadrantectomy

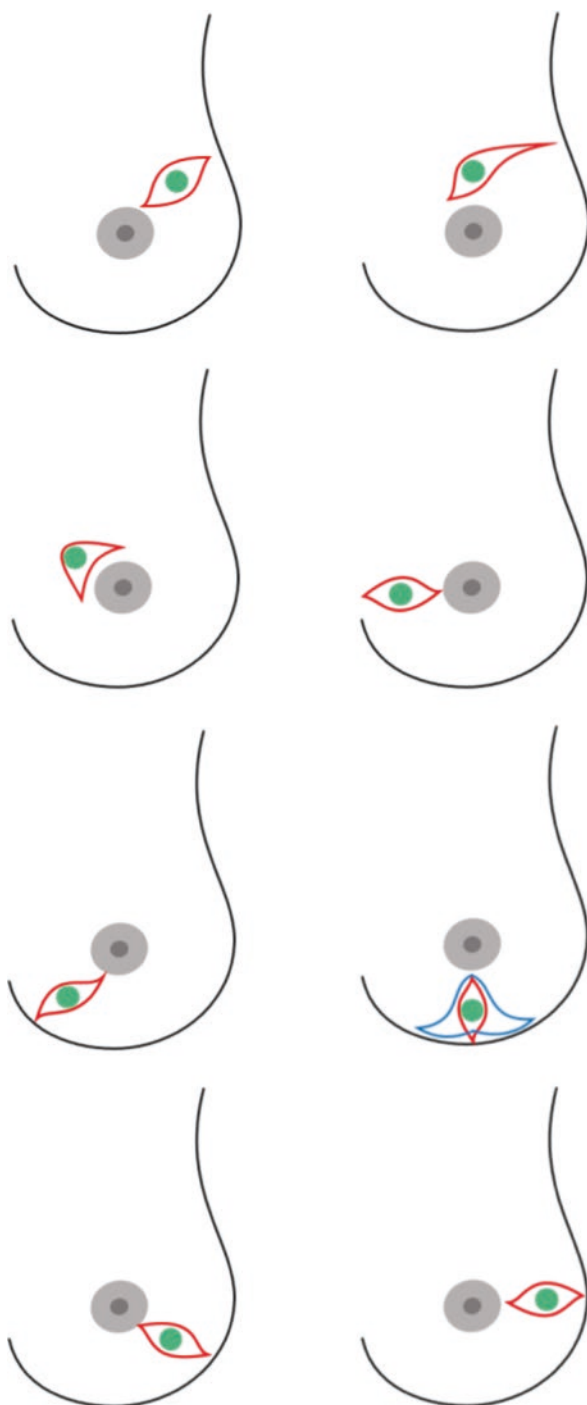


Table 7.1 OPS Yang

Volume replacement	Volume displacement
Lateral thoracodorsal flap Thoracoepigastric flap ICAP flap TDAP flap LD myocutaneous flap	Glandular reshaping: Parallelogram mastopexy lumpectomy Purse-string suture Round-block technique Batwing mastopexy Tennis racket method Rotation flap Reduction mammoplasty: Wise pattern (inverted T) Vertical pattern

OPS techniques (modified from Yang et al.)

Table 7.2 OPS White

Central tumors, occupying 10–20% of breast volume	Peripheral tumors, occupying 10–20% of breast volume	Excision of >20–40% of breast volume, techniques of tissue transfer
Inferior pedicle (Grisotti) mammoplasty (central tumors involving the NAC)	Inferior to NAC: inverted T (WISE) mammoplasty, vertical scar mammoplasty	Latissimus dorsi mini-flap
Benelli's round-block technique (central tumors not involving the NAC)	Inferior-outer/inner: J- or L-mammoplasty	Thoracodorsal artery perforator lipodermal flap
	Lateral or medial to NAC: lateral and medial mammoplasty	Intercostal artery perforator flap
	Inframammary fold: IMF-plasty	
	Superior to NAC: inferior pedicle (Grisotti) mammoplasty: peri-areolar (Benelli) mammoplasty	

OPS techniques (modified from White et al.)

tissue (*volume replacement* techniques) (Table 7.1) [27–30]. White, from the British school, focuses attention on two concepts: tumor localization relative to NAC and percentage of breast tissue to be resected (Table 7.2) [31]. When choosing a surgical technique, other authors also take into consideration the density of glandular tissue, classifiable as “almost entirely fatty,” “scattered fibro-granular densities,” “heterogeneously dense,” and “extremely dense” [32]. An extremely dense and highly vascularized parenchyma allows a glandular detachment from skin and muscle with no risk of tissue necrosis; this type of approach is not suitable for a fatty, scarcely vascularized breast parenchyma. Clough combined the previous assumptions in a classification of OPS techniques based on percentage of breast tissue excised (more or less than 20%), tumor localization, and parenchymal density:

- Level I: excision volume <20%, requiring simple glandular remodeling techniques
- Level II: excision volume more than 20% (up to 50%), requiring specific oncologic surgical techniques (Table 7.3) [33]

Table 7.3 OPS Clough

Tumor position	Procedures
Lower pole	Superior pedicle mammoplasty/inverted T or vertical scar
Lower-inner quadrant	Superior pedicle mammoplasty/V scar
Upper-inner quadrant	Batwing
Upper pole	Inferior pedicle mammoplasty/round-block mammoplasty
Upper-outer quadrant	Racquet mammoplasty/radial scar
Lower-outer quadrant	Superior pedicle mammoplasty/J scar
Central subareolar	Inverted T or vertical scar mammoplasty with NAC resection

OPS techniques (modified from Clough et al.)

Inferior Pedicle Mammoplasty (IPM)

IPM is ideal for the treatment of tumors located in the upper central quadrant near the NAC, especially in ptotic breasts. Operation starts with an inverted T skin incision. Then quadrantectomy (excision of tumor with clear margin, up to muscle fascia, including skin) takes place at the upper central quadrant; NAC vascularization is ensured by the inferior pedicle, according to Ribeiro and Robbins [34, 35]. De-epithelization takes place in the lower central quadrant, according to pre-operative drawing. Then the surgeon resects gland in the lower lateral and medial columns. Reconstruction starts with NAC being shifted cranially, filling the substance loss left by quadrantectomy, and then sutured in this position; after this, lower lateral and medial columns are sutured one to another and in the caudal part for reconstruction of inframammary fold (Fig. 7.5).

Superior Pedicle Mammoplasty with Inverted T Scar

This technique is suitable for tumors in the lower quadrants, especially in large breasts, with or without ptosis; cosmetic outcome improves if a contralateral symmetrizing mammoplasty is performed. Skin incision takes place in a reduction, inverted T pattern, and de-epithelization involves the peri-areolar skin. Starting from a hemi-peri-areolar inferior glandular incision, NAC is detached from the underlying gland, creating an 8–10 mm-thick flap, whose vascularization is ensured by the superior pedicle [36, 37]. An extensive quadrantectomy takes place in the lower quadrants, starting from the inframammary fold and proceeding cranially. Reconstruction is made through a re-approximation of the lateral and medial columns, a T suture in the lower pole, and a suture of NAC in its new position (Fig. 7.6).

V-Mammoplasty

V-mammoplasty is suitable for tumors involving the lower quadrants, especially the lower-inner quadrant of medium-sized breasts with no ptosis. Skin incision is represented in Fig. 7.7. De-epithelization involves the peri-areolar skin and then resection is carried out, up to the fascia. A skin-glandular flap is prepared from the lower-outer quadrant, which is then shifted medially to fill the substance loss; the

Fig. 7.5 Inferior pedicle
mammoplasty

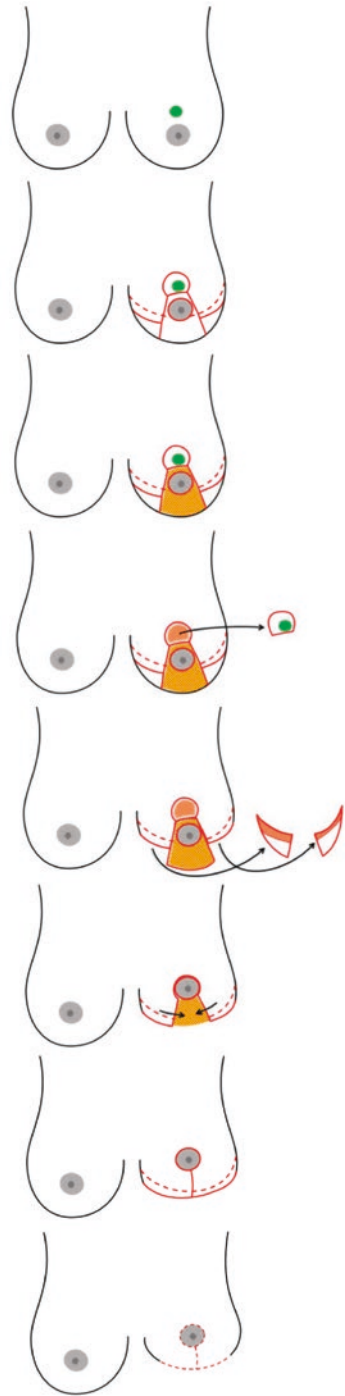


Fig. 7.6 Superior pedicle mammoplasty

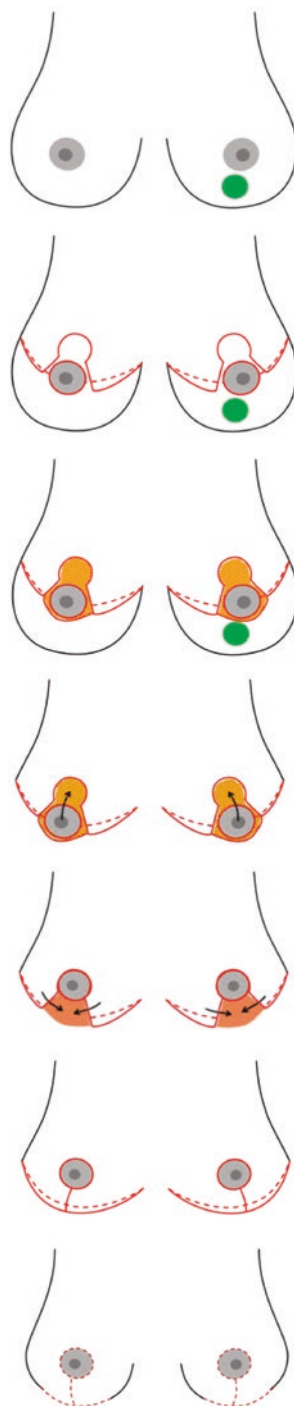
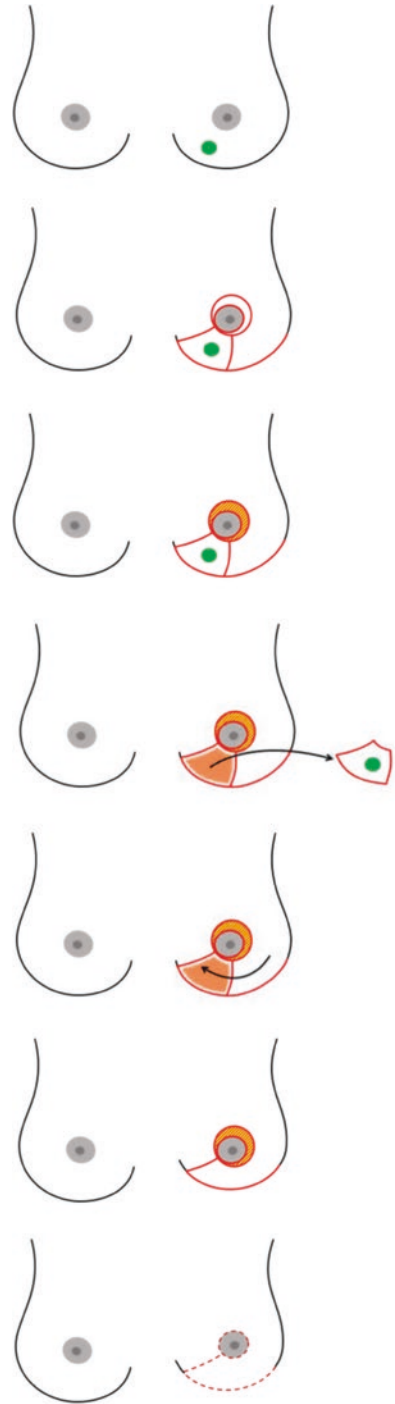


Fig. 7.7 V-mammoplasty

flap is then sutured in this position and to the inframammary fold. Operation ends with NAC repositioning.

J-Mammoplasty

Tumors in the lower-outer quadrants can be treated with a J-mammoplasty. Skin incision involves the peri-areolar zone and the borders of quadrantectomy (see Fig. 7.8). Peri-areolar de-epithelization is carried out and then tumor is resected. Lateral glandular column is then shifted medially in order to fill the substance loss, and NAC is repositioned.

Horizontal Mammoplasty or Batwing Mastopexy

Batwing mastopexy is chosen for treating tumors of the upper quadrants. It is particularly suitable for the upper-inner quadrant, whose resection carries a high risk of breast deformity. Operation starts with a large omega-shaped skin incision involving the upper breast quadrants. Resection occurs perpendicular to thoracic surface, providing clear margins, until it reaches pectoral fascia. Reconstruction is carried out by shifting cranially and suturing to the upper quadrants the lower breast hemisphere, resulting in a mastopexy (Fig. 7.9).

Clips on Tumor Beds

Clips are used to mark tumor beds for two purposes:

- *Providing guidance during reinterventions.* Clips facilitate the identification of the area of the previous resection in case radicality is not achieved after the first intervention, especially during oncoplastic surgery, which includes major glandular reshaping and the modification and dislocation of the tumor bed.
- *Providing radiation oncologists with a target.* Clips also facilitate the work of radiation oncologists, as they enable the accurate radiological localization of the tumor bed.

EMI-Batwing Mastopexy

This technique is similar to horizontal mammoplasty, but skin incision is differently shaped (see Fig. 7.10).

Lateral Mammoplasty or Racquet Technique

Lateral mammoplasty is applicable for large tumors (predicted resection volume >20% of the entire gland) of the upper-outer quadrant. Skin incision, shown in Fig. 7.11, is lozenge-shaped and includes the whole upper-outer quadrant. De-epithelization of peri-areolar skin is followed by an extensive upper-outer quadrantectomy; two local glandular flaps (upper medial and lower lateral) fill substance loss. Operation ends with skin suture and NAC repositioning.

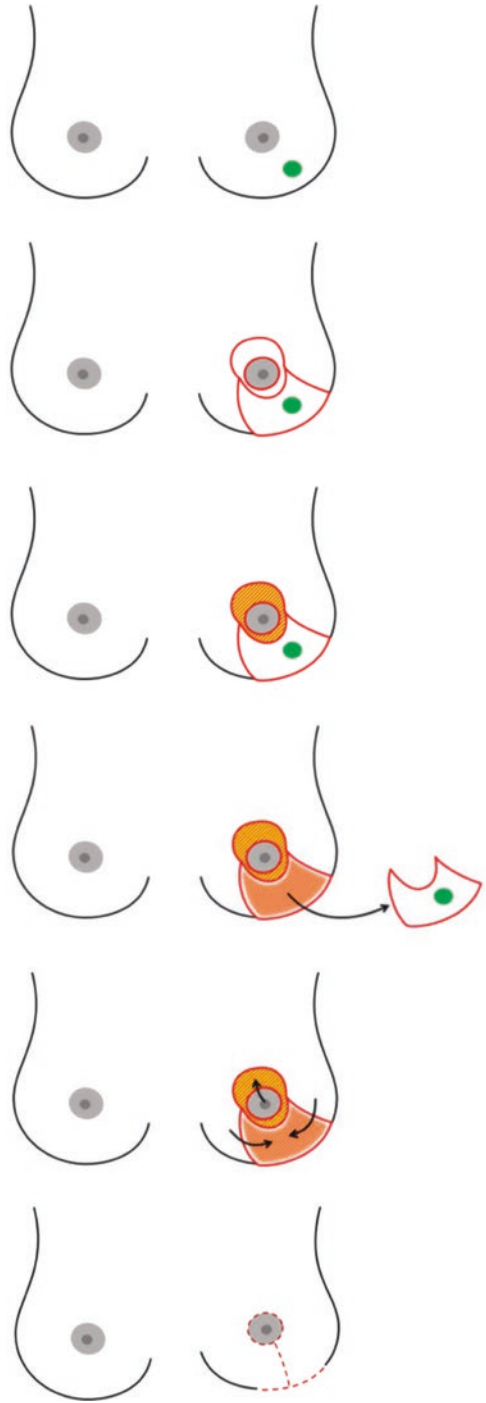
Fig. 7.8 J-mammoplasty

Fig. 7.9 Batwing mastopexy

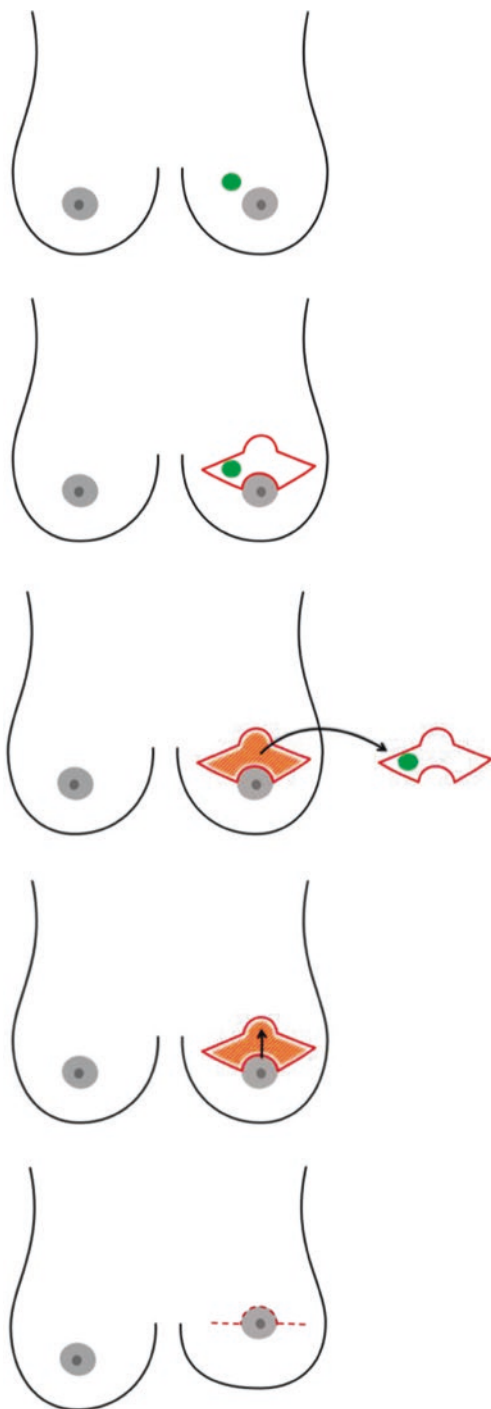


Fig. 7.10 EMI-batwing mastopexy

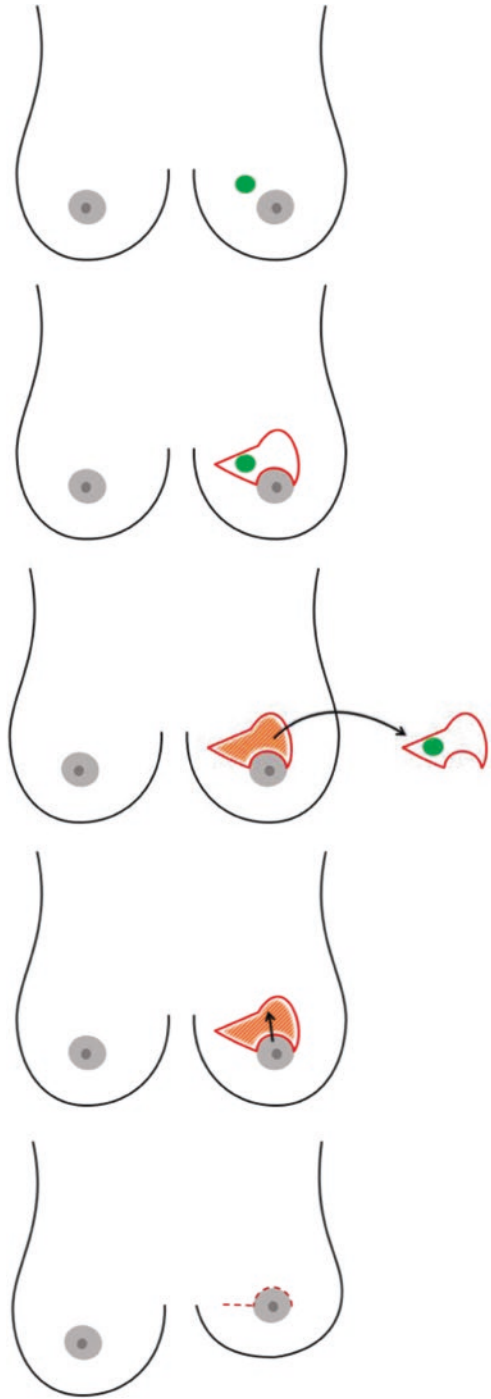
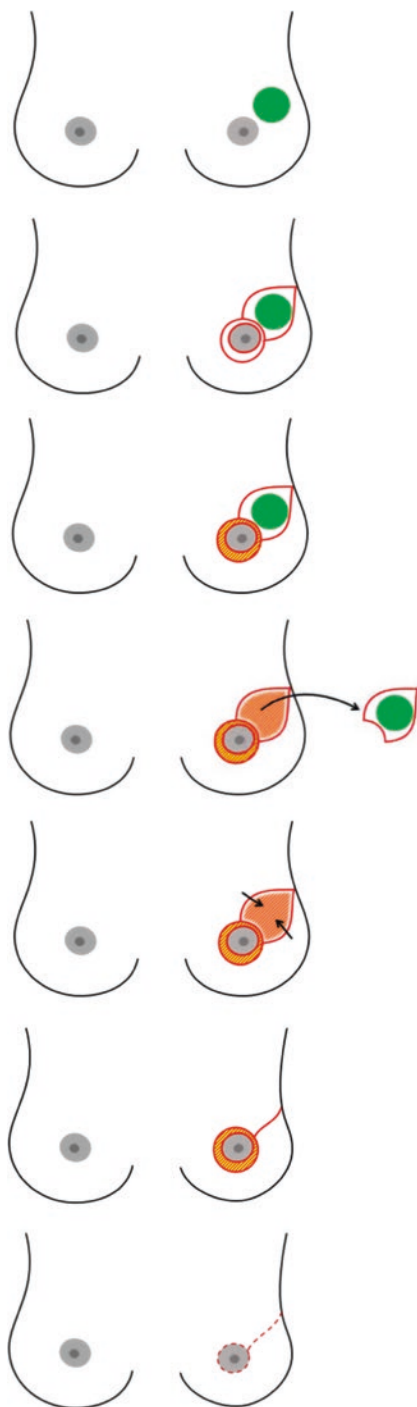


Fig. 7.11 Lateral mammoplasty



Grisotti Flap

Grisotti's technique consists in a retro-areolar quadrantectomy with NAC replacement. Operation starts with skin incision (Fig. 7.12): circum-areolar, peri-areolar, and double comma-shaped incision extended from NAC to inframammary fold. De-epithelization involves peri-areolar area and the lower central quadrant, saving a circular piece of skin for NAC replacement. Glandular resection involves the central quadrant, up to pectoralis fascia, and includes the NAC. Reconstruction starts with glandular suturing in the resected area; the spared piece of skin, shifted thanks to its advancement and rotation flap, replaces the NAC. Operation ends with skin suture.

Round-Block Technique by Benelli

Benelli's operation allows the resection of tumors growing near the NAC, especially in its upper central part (but it might be adapted for other parts of the peri-areolar zone), with a minimal scar. Its use is advisable in small/medium-sized breasts. Skin incision are two and concentric, around the NAC (see Fig. 7.13), and de-epithelization takes place between them, taking care of NAC's blood supply. The inner incision is located at the edge of the areola and the outer at a distance that is dependent upon location and size of tumor, location of nipple, and degree of ptosis. The larger the tumor and the further it is from the nipple, the larger the distance between the two circumferences [38]. Superficial detachment of gland from the subcutaneous layer starts at the external edge of the de-epithelized area, in the point that is closer to tumor, and continues until the working space is sufficient for tumor resection. Quadrantectomy reaches the pectoralis fascia, but it does not include skin overlying tumor. Local glandular flaps fill substance loss. Operation ends with subcutaneous and cutaneous suture of the two circumferences. Round-block technique results in a significant reduction of breast ptosis.

Reintervention

- When? The debate on the DCIS resection margin matter is heated. Blair et al. have underlined the high dissent rate among surgeons when recommending surgery: 53% of surgeons deem a 2 mm margin acceptable, 23% repeat surgery with a <1 mm margin, 12% rely on the presence of ink on the neoplasm, 10% use a 5 mm cutoff, while 2% opt for 10 mm [62]. Taghian et al. have highlighted that European radiotherapists usually prefer a wider margin (>5 mm), while Northern Americans accept lower thickness (1–2 mm) [63]. Morrow et al. hold that the positive margin, marked by the presence of ink on the neoplasm (in situ or infiltrating), is associated with a local relapse risk at least two times higher; such increase in risk cannot be eliminated by use of radiotherapy, systemic treatments (hormone therapy, chemotherapy, biological therapy) or due to biological features favoring the neoplasm [13]. According to NCCN 2016 guidelines, a margin <1 mm should always lead to reintervention (re-excision or mastectomy), as the high probability of residual tumor cannot be reduced significantly with radiotherapy. The same guidelines advise against reintervention with a margin >10 mm, which can also be defined as “overtreatment.” Intermediate cases (1–10 mm) see relapse risk decrease as the margin becomes wider; in such

cases, other factors (age, number of affected margins, extent of margin infiltration, histological subtype, phenotype) are to be taken into consideration when assessing whether to recommend reintervention [14]. Adams et al. underline the fact that the high relapse rate may reflect the biological features of the neoplasm [64]; the branch of research on the biological characterization of intraductal carcinoma and its treatment implications is currently very active, and a better understanding of the link between the biology and relapse of such neoplasm could lead to the tailoring of margins for each patient.

- *Which one?* The parameters to be considered when choosing between re-excision and mastectomy are the following:
 - *Age.* In young patients (<50 years), performing a mastectomy is advisable due to the higher biological aggressiveness of the neoplasm.
 - *Number of affected margins and extent of affection.* A re-excision should be performed in the presence of a single focally or minimally affected margin; the higher the number of affected margins and the extent of the affection, the lower the likelihood of successful conservative surgery, in favor of mastectomy.
 - *Histology and biological features.* Mastectomy should be opted for in the DCIS showing unfavorable histotypes (solid, cribriform, comedo), high nuclear grade, aggressive phenotype (HER-2, basal-like).
 - *Breast volume.* Large volumes are suitable for re-excision, while medium-small volumes are not.
 - *Patient's will.* Also in this case, attaching importance to the patient's will when choosing what intervention to perform is important, provided that she has been adequately informed on the risks and benefits of the different procedures.
- *Consequences and complications.* The gold standard for surgeons is obtaining radicality after the first intervention, as re-excision leads to negative consequences and complications:
 - *Difficulties in identifying the exact location of the re-excision.* Such problem arises especially after major glandular reshaping (oncoplastic surgery); the use of clips during the first intervention can solve such problem.
 - *Repercussions on the aesthetic outcome.* Such problem arises especially in the presence of medium-small volumes. Aesthetic flaws show after reinterventions, as the latter involves the excision of another glandular portion. The minimization of aesthetic consequences depends on the choice of the right reintervention type (re-excision or mastectomy).
 - *Psychological stress.* Distress due to the first step toward healing not being successful, fear of cancer progression, fear of surgery, general anesthesia, post-surgery pain, and lack of trust in the surgeon are some of the factors which can cause stress in patients requiring reintervention.
 - *Delays in the adjuvant therapy.* Reinterventions are to be performed quickly so as to minimize delays in the adjuvant therapy.
 - *Costs*
 - *Positive margin.* The margin may be affected again; in such case, radicalizing by means of mastectomy is advisable.

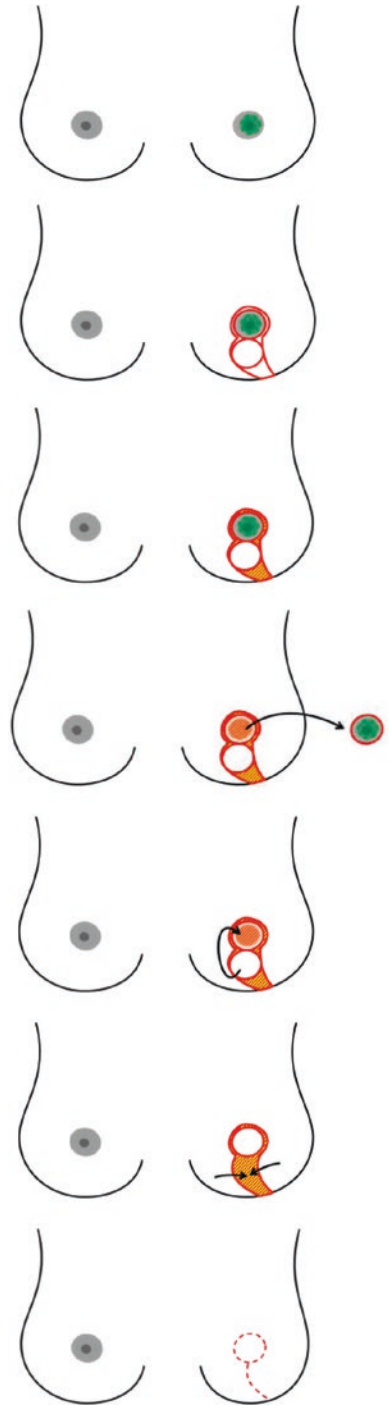
Fig. 7.12 Grisotti flap

Fig. 7.13 Round-block technique

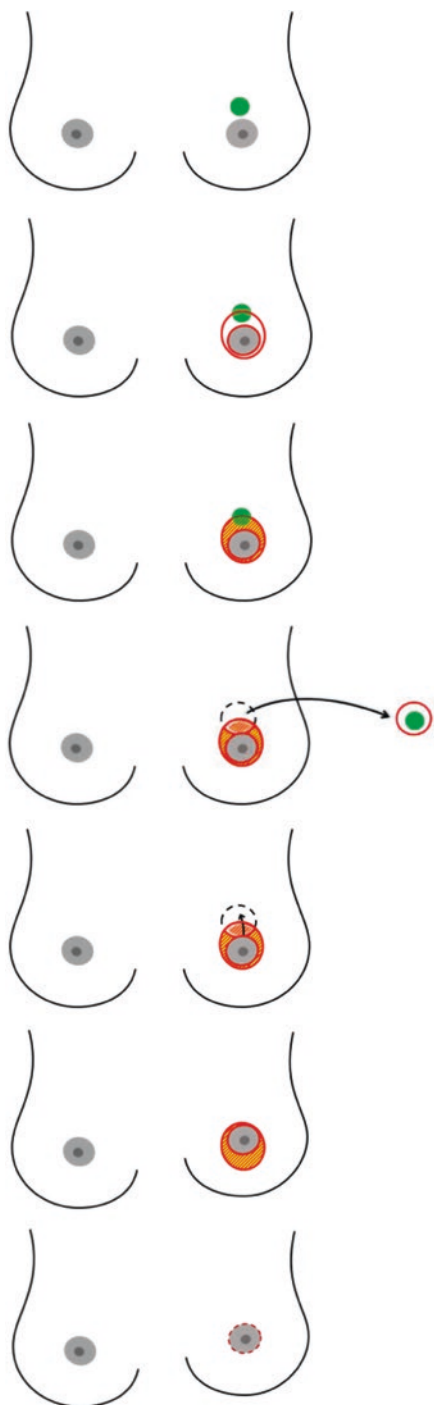


Table 7.4 Deformities

Type I	Displacement of the nipple-areolar complex
Type II	Localized deficiency of parenchyma and/or skin
Type III	Generalized breast contracture with no localized defects
Type IV	Severe damage with heavily scarred parenchyma and/or skin

Deformities post BCS (modified from Berrino et al.)

7.4.1.4 BCS and Substitution with Autologous Tissue

The use of volume replacement techniques, that is, the restoration of previous breast volume after BCS by transposition of autologous tissue (flaps or fat grafting), is necessary when size and/or location of glandular defect does not guarantee for a satisfactory cosmetic outcome with the sole use of residual breast tissue. These techniques have the advantage of offering a natural-looking “new breast” and, therefore, a good degree of symmetry with no need of contralateral breast remodeling. A further advantage is that no prosthetic materials are used, with the possibility of carrying out radiotherapy in safety. These operations require an adequate donor site; they are more invasive, resulting in a longer hospital stay and a longer postoperative period; most of all, they require surgical skills. These techniques can also be used for correcting deformities resulting from failed or incorrect glandular reconstruction, during BCS or after radiotherapy [39] (Table 7.4). Flap surgery and fat grafting is described in Chap. 8.

7.4.2 Mastectomy

In 1894 Halsted delineated radical mastectomy [40], which was considered breast cancer standard treatment for many years; this operation consisted in the en bloc removal of the breast gland, surrounded by skin and nipple-areola complex, both pectoralis muscles and axillary lymph nodes from Berg level I to III. Halsted’s mastectomy was a symbol of destruction of female body image (large scar, loss of nipple-areola complex, impossibility for reconstruction), with a strong psychological impact on patients. In 1948, Patey and Dyson of Middlesex Hospital, London, proposed a new type of mastectomy, in which pectoralis major muscle was preserved, resulting in a decreased morbidity for the patient [41]. Later on, Madden reinforced this course with a modified radical mastectomy, in which both pectoralis muscles were preserved [42]. In the 1980s, with the arousal of Veronesi’s quadrantectomy [43], mastectomy progressively lost importance; in fact, today over two thirds of breast cancer patients are treated conservatively. On the other hand, there are still patients who require mastectomy (25–30%) because of multifocality, multicentricity, problems with radiotherapy, etc. The impossibility of treating all breast cancer women with breast-conserving surgery lead to an effort toward the cosmetic enhancement of mastectomy, up to the validation of conservative mastectomies in terms of oncological safety. The history of conservative mastectomy starts in 1962 with the publication, by Freeman [44], of his results with subcutaneous mastectomy. Then, in 1984, a study published by Hinton [45] compared survival in women treated with Madden’s mastectomy and women treated with subcutaneous mastectomy followed by

immediate implant reconstruction. In 1991, Toth and Lappert coined the term “skin-sparing mastectomy” [46], referring to an operation involving the removal of the whole gland, together with the nipple-areola complex and the skin overlying the tumor, through a peri-areolar incision; the effort in skin preservation was aimed at maximizing aesthetic result of reconstruction. Performing this operation, Kroll found only 1 case of recurrence in 100 patients after a 2-year follow-up [47]. Since then, the methodic attracted the attention of several surgeons, and it has been subject to many studies that showed substantial oncological equivalence with radical methods. Cosmetic outcome was satisfactory, thanks to preservation of skin and inframammary fold. The success of this surgical approach, together with the results of the clinical trials on the oncological safety of SSM, increased the interest on this type of operation. Given that cosmetic and emotional impact was still not excellent because of the loss of the entire NAC, whose reconstruction techniques was seldom satisfying, new surgical operations were proposed: the NAC-sparing mastectomy (NSM) [48] and the areola-sparing mastectomy. Similar to SSM and NSM, also another technique was validated, suitable for large and/or ptotic breasts: the skin-reducing mastectomy (SRM), in which part of the skin and, usually, the NAC are removed. SSM, NSM, and SRM belong to the chapter of conservative mastectomies.

7.4.2.1 Radical Mastectomies

Radical mastectomies are used rarely for treating breast cancer, exceptionally for DCIS. Madden’s mastectomy involves the removal of the entire breast parenchyma and the majority of breast skin, leaving two skin flaps (upper and lower) for wound suture; it results in a poor cosmetic outcome, given by the large scar and the complete loss of symmetry. This technique can be used for treating large or multifocal ductal carcinomas in situ in patients with significant comorbidities or in patients that refuse reconstruction.

7.4.2.2 Conservative Mastectomies

Nipple-Sparing Mastectomy (NSM)

NSM involves the complete removal of the breast tissue while preserving the skin of the breast, the NAC, and the inframammary fold. NSM is an oncological-aimed operation characterized by a thorough removal of the glandula, a careful preparation of the skin flaps, and the preservation of a 3–4 mm-thick, pathologically checked NAC. Areola-sparing mastectomy is a variant of NSM: it involves the focal removal of the nipple (with preservation of areola) in case of intraoperative pathological found of tumor in the retro-areolar tissue. Another variant of NSM involves the conservation of a subareolar tissue pad which is irradiated with IORT (intraoperative radiotherapy) [49].

Breast surgical anatomy. Mammary gland is located in the anterior thoracic region, within a splitting of the superficial fascia. The anterior lamina (pre-mammary) of the superficial fascia is found in less than 50% of breasts [50]; if present, it is rarely continuous [51]. Anterior lamina is always interrupted in the NAC area, allowing the opening of the lactiferous ducts on the nipple skin surface. Superficially to the anterior lamina, there is a cellulo-adipose layer, whose thickness varies among

different patients and, in the same patient, from quadrant to quadrant. Considering the aforementioned information, together with the fact that mammary islands can be found externally to the anterior lamina, the definition of an ideal oncologic plane (along which an oncologically safe mastectomy should be carried out) is a real challenge. In 2014 Robertson and Rusby gave a detailed description of the subcutaneous adipose tissue of the breast; they concluded that “elevation of the oncologic plane between the subcutaneous adipose tissue removes most, but not all, breast tissue” [51]. Between the posterior lamina and the pectoralis major muscle fascia, there is the retromammary adipose layer, crossed by fibrous projections (suspensory ligament of the breast) that keep the mammary gland joined to the chest wall. The inframammary fold, that is, the anatomical area of dense fibrous tissue in which the two layers of the superficial fascia fuse together, is of great importance for breast aesthetics, and its preservation is fundamental in conservative mastectomies. The anatomical borders of the breast are classically defined as follows: large infraclavicular muscle bundle, midsternal line, anterior edge of latissimus dorsi, and lower edge of pectoralis major muscle. Further studies demonstrated that mammary ducts frequently extend beyond these borders. In 1940 Hicken found that in 95% of cases, ducts are present in the axillary area, in 15% of cases ducts are in the epigastric region, in 2% of cases ducts are present beyond the anterior border of latissimus dorsi muscle, and in 0.5% ducts extend beyond the midsternal line to the contralateral side [52]. As for mammary borders and superficial lamina, the incongruence of macroscopic and microscopic anatomy is of great importance in neoplastic recurrence.

Breast vascular anatomy. Breast blood supply is derived from the following: the internal mammary perforators (most notably the second to fifth perforators), the thoracoacromial artery, the vessels to serratus anterior, the external mammary artery, and the terminal branches of the third to eighth intercostal perforators. Internal and external mammary arteries supply the arterial vascularization of the NAC; anastomosis of these arteries forms two plexi in the NAC area. The first plexus, massive and rich, is located around the areolar borders; the second plexus, thin and superficial, branches off around the nipple. Recurrent perforating arteries (inner and outer mammary artery perforators, anterior-medial and anterior-lateral intercostal perforators) flow from this plexus and reach the mammary ducts where they anastomose with the subareolar subdermal plexus. Tributary branches of perforating veins of internal mammary vein, intercostal veins, and axillary vein supply NAC's venous outflow.

Breast innervation. The anterior-medial and the anterior-lateral branches of the intercostal nerve IV mainly supply NAC's innervation. The intercostal nerves III and V, together with the supraclavicular nerves, contribute to sensitivity. The intercostal nerve IV enters the breast laterally; it runs medially along the deep fascia and then upward across the parenchyma to reach the NAC. In the light of the fact that various nerves contribute to the innervation of this area, the surgical sectioning of some of these branches should not result in NAC anesthesia. Also true is the fact that it is practically impossible to choose preferential incisional surgical options to conserve the nervous fiber; such impossibility seems to be valid also for vascularization. Many authors reported that NSM significantly reduces nipple sensitivity and erectile function [12], with a 28% recovery rate at 6 months.

Indications and contraindications. NSM is mandatory in DCIS when multifocality and multicentricity are present. In the conditions listed below NSM is advisable:

- Large-sized DCIS, compared to breast size (consider that, usually, preoperatively estimated size of DCIS does not coincide with its actual size; preoperative MRI may sometimes help the decision-making process). This is not an absolute contraindication to BCS: it is possible to remove a large DCIS with a large quadrantectomy or with an oncoplastic approach but not advisable because of the high risk of involved margins and bad cosmetic outcome.
- Involved margins after breast-conserving surgery.
- DCIS recurrence after conservative surgery.
- Patient's refusal of conservative surgery.
- Contraindications to postoperative radiotherapy.
- Difficulty for follow-up after BCS.

We consider contraindications to NSM all the conditions in which conservation of NAC significantly increases the risk of recurrence or in which there is a high risk of postoperative insufficiency of flaps vascularization. In this field, we distinguish relative contraindications and absolute contraindications. If absolute contraindications are present, NSM cannot be performed, but a different type of conservative mastectomy can be chosen.

- Intraoperative evidence of DCIS in subareolar tissue (conversion to SSM).
- Paget's disease of the nipple (consider SSM).
- Nipple retraction (consider SSM).
- Significant ptosis (distance nipple-inframammary fold >8 cm); consider SRM.
- Large breast (>500 cm³); consider SRM.

Relative contraindications represent conditions in which the surgeon is allowed to carry out a NSM, but with a high risk of intraoperative NAC involvement:

- Tumor-NAC distance <2 cm in mammography or MRI
- Subareolar microcalcifications
- Bloody discharge from nipple

Planning the Surgery

1. Evaluation of oncological indication for NSM.
2. Evaluation of reconstruction, in terms of technical approach (implant and/or others, type of implant, expected status of major pectoralis muscle, considering previous operations and/or radiotherapy) and expected outcome (symmetry, patient's satisfaction).
3. Evaluation of contralateral prophylactic mastectomy possibility: this approach must be taken into consideration only for patients who ask for it. CPM is more beneficial in young patients (<45 years) with low-stage cancer (as in the case of

DCIS) [53], and it gives the best cosmetic outcomes in women with small breasts and in small-/medium-sized breasts with ptosis.

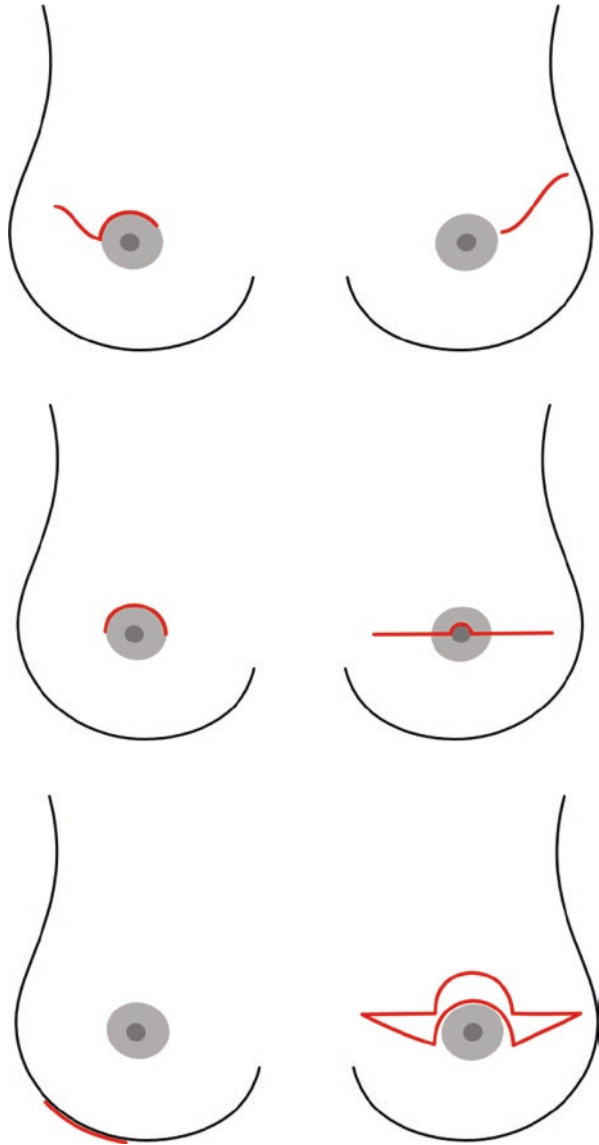
4. Analysis of risk factors for complications (previous radiotherapy, previous breast operations, smoking) and evaluation of the overall benefit.
5. Patient's information and consent for operation. Information must be clear and comprehensive: possibility of intraoperative conversion to skin-sparing mastectomy, expected cosmetic outcome, complications (NAC discoloration, ischemia, necrosis, loss of NAC sensitivity and erectile function, cancer recurrence).

Skin incision. Several skin incisions have been proposed, each one involving advantages and disadvantages.

- *Upper peri-areolar incision.* All the peri-areolar incisions have the strong advantage of leaving a barely visible scar; they also facilitate subareolar dissection but, given the difficulty to reach the medial third of the inframammary fold (and the axilla, if needed), it is preferred in small breasts.
- *Upper peri-areolar incision with lateral extension.* This type of incision is useful when a surgical approach to axilla is required. However, it often results in a lateralization of the NAC, requiring corrective action.
- *Trans-areolar incision.* See Fig. 7.14.
- *Inframammary incision.* Skin incision is carried out at the lateral third of inframammary fold; in this area scar is practically invisible. The surgeon will however find it difficult to perform a complete demolition of the upper quadrants and to carry out axillary surgery, especially in large breasts.
- *Upper-outer radial incision.* This type of incision should be preferred because it facilitates access to axilla, glandular excision, and reconstruction time. Moreover, it minimally damages NAC vascularization, and scar outcome is usually excellent, except for few cases of slight lateral deviation of NAC.
- *Omega incision.* See Fig. 7.14.

Demolition time. Starting from skin incision, dissection occurs along the anterior lamina of the superficial fascia. There is not a standard flap thickness; the surgeon finds the correct dissection plane basing on the surgical anatomy he finds during operation. One must take care of flaps vascularization, avoiding excessive skeletonization of dermis. Flap palpation is fundamental also for detecting residual glandular tissue, whose presence increases recurrence possibility. Dissection plane is almost avascular, but the surgeon may find on his way perforating vessels that must be promptly coagulated. The second surgeon facilitates this time by pulling upwards the skin flap while the first surgeon pushes the gland downwards, in order to obtain easiest identification and opening of dissection plane. The releasing of the gland from the deep planes begins from the upper part, almost where pectoralis major muscle arises on clavicle, and occurs along an almost avascular plane. Dissection then runs caudally and medially, reaching the parasternal line; in this area, muscle fascia is not well defined, and dissection plane is frequently crossed by perforating vessels of internal mammary artery. The surgeon continues dissection caudally up to the inframammary fold and then laterally; at this edge, the gland is detached from the lateral border of pectoralis major muscle, from serratus anterior muscle, and

Fig. 7.14 Skin incision in nipple-sparing mastectomy: upper peri-areolar with lateral extension, upper-outer radial, upper-peri-areolar, trans-areolar, inframammary inferior lateral, and omega



from the anterior axillary pillar (latissimus dorsi muscle). Axillary tail develops partially inside the axilla and is the last part to be dissected; some surgeons are used to carry out a one-piece removal of breast and axillary lymph nodes (if axillary lymph node dissection is required). When sentinel lymph node biopsy is planned, it is advisable to check breast axillary tail for occult sentinel lymph nodes.

Management of subareolar tissue. Nipple-sparing mastectomy can be considered a safe procedure only after a pathological intraoperative examination of subareolar tissue with exclusion of nipple involvement by neoplastic cells. Preparation of

subareolar biopsy takes place during superficial dissection time: getting closer to the areolar area, the surgeon must proceed with meticulous care and perform first a precise detachment of areolar skin from the underlying gland, then the isolation and distal sectioning of lactiferous ducts. Subareolar dissection turns the NAC into a sort of dermoepidermal graft, which will be easily re-vascularized by the underlying muscle tissue. For an accurate and artifact-free histological examination, it is mandatory for the surgeon to avoid electrocautery on the superficial margin. Correctness of this step increases with the use of hydrodissection technique, which consists in a retro-areolar infiltration of epinephrine and saline solution in order to help identification of the anatomical and bloodless incision plane [54]. Subareolar specimen gets accurate orientation and is sent, separately from the rest of the gland, for examination (Fig. 7.15). The pathologist prepares at least three, 200–300 μm -thick, frozen sections from the specimen. Microscopic examination may or may not find

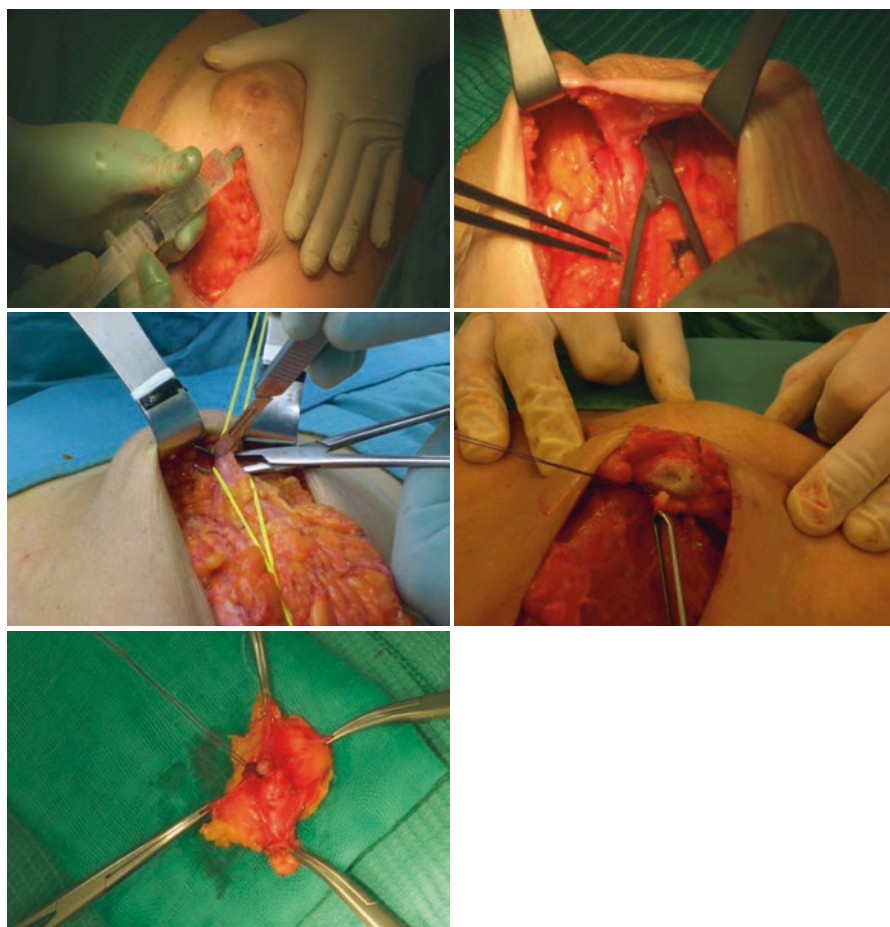


Fig. 7.15 Preparation of subareolar biopsy

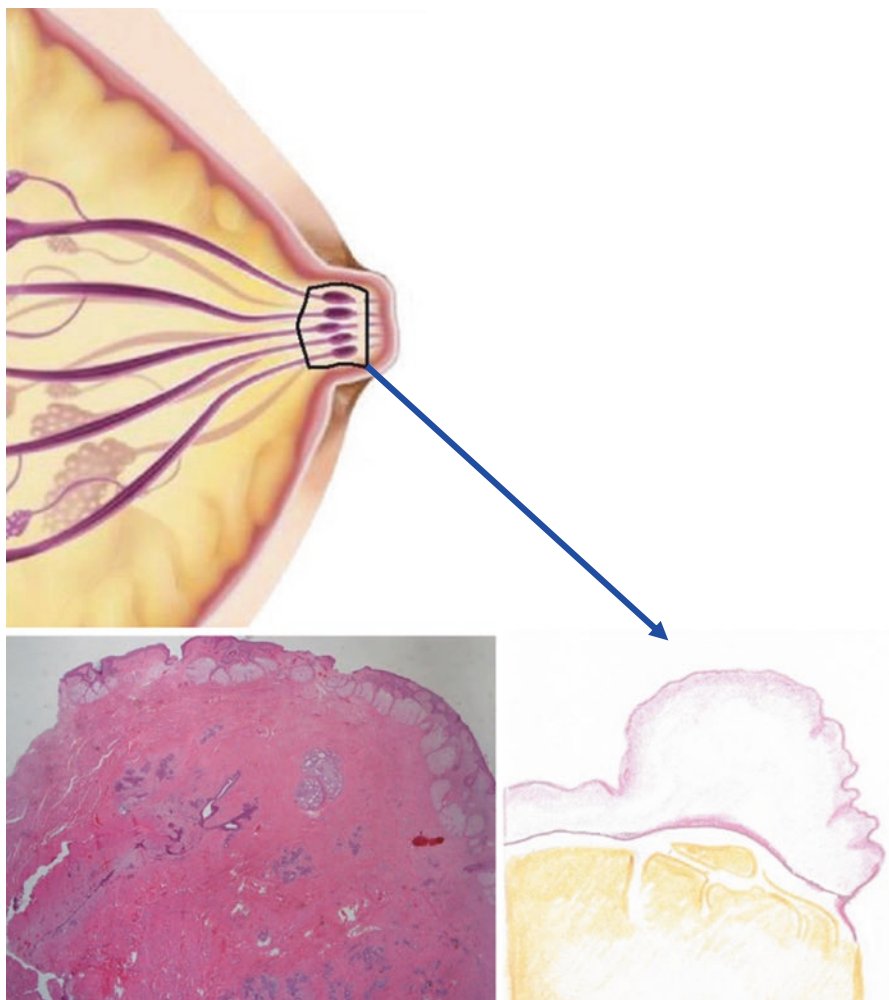


Fig. 7.16 Intraoperative examination of subareolar biopsy

neoplastic cells; if tumor is present, the pathologist specifies the type (invasive or in situ) and the distance from the tip of the nipple (labeled by the surgeon) (Fig. 7.16). Positivity of histological examination recommends the excision of the NAC (conversion to SSM) or, given the paucity of ducts underneath the areola, the nipple alone (areola-sparing mastectomy). In both cases, the surgeon performs a double purse-string suture, which results in a scar with fair projection, somehow similar to the native NAC. Intraoperative histological examination misses cancer in 4.6% of cases; therefore, in a small percentage of patients, the surgeon has to perform NAC resection in a second operation.

Reconstruction time. See Chap. 8.

Complications. See Table 7.5.

Table 7.5 Complications

Minor
Cyanosis/hypopigmentation of the NAC
Localized infection
Major
NAC ischemia (frequent)
NAC necrosis
Flap necrosis (more frequent when risk factors such as diabetes and smoking are present)
Seroma
Bleeding/hematoma
Implant infection
Late
Extended and retracted scar
Nipple or skin retraction
NAC displacement
Changes in sensibility and erectile function of the nipple
Capsular retraction
Bad positioning of the implant
Rotation of the implant
Evident breast asymmetry
Cancer recurrence
NSM complications

Skin-Sparing Mastectomy (SSM)

SSM involves the removal of the entire mammary gland, including the NAC, with preservation of breast skin envelope. In 1997, Carlson [55] proposed a classification of SSM with four types:

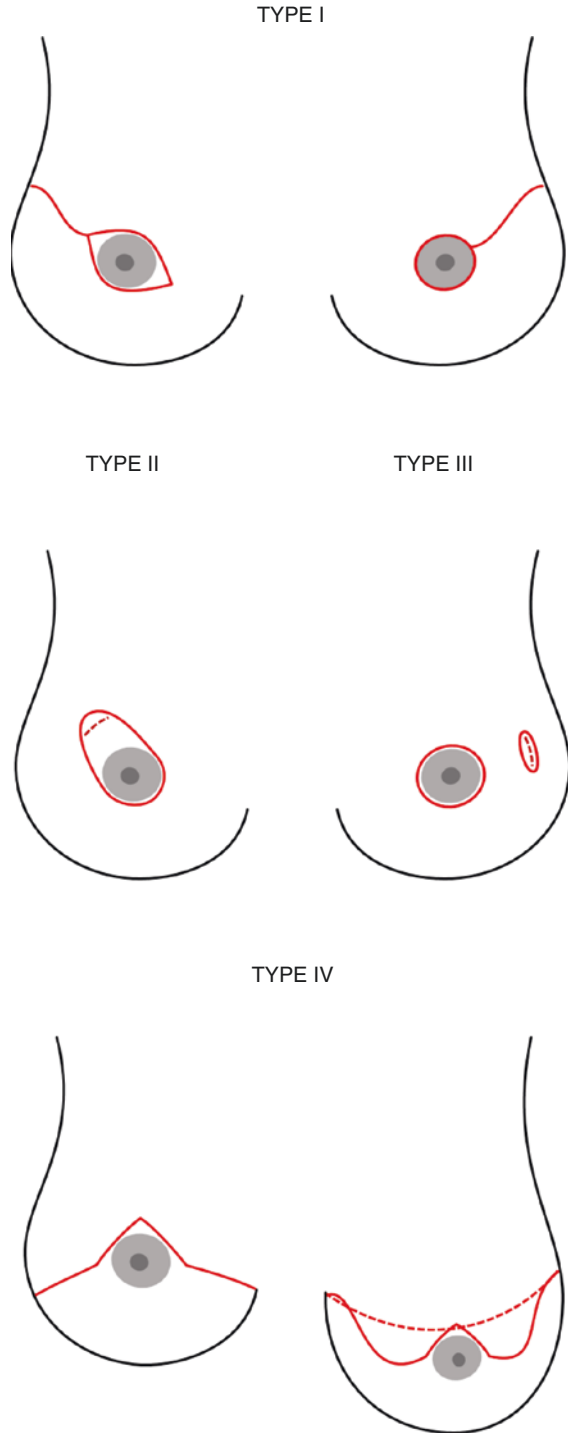
- Type I: removal of breast, nipple, and areola
- Type II: removal of breast, nipple, areola, and, in continuity with the NAC, skin overlying tumor (if superficial) and previous biopsy incision
- Type III: removal of breast, nipple, areola, skin overlying tumor, and previous biopsy incision, without continuity
- Type IV: skin-reducing mastectomy (removal of NAC with an inverted or reduction pattern incision [56–61]) (Fig. 7.17)

SSM should be performed in those cases in which indications for NSM are present, but NAC conservation is not advisable (Paget's disease of the NAC, nipple retraction). SSM may also result from an intraoperative conversion from NSM to SSM because of pathological evidence of tumor in the subareolar tissue.

Skin-Reducing Mastectomy (SRM)

Skin-reducing mastectomy (type IV SSM) should be performed in all cases in which NSM indications are present and breast size is too large (>500 cm³) for a safe preservation of NAC blood supply. SRM is in fact a skin-sparing mastectomy (type IV), which involves the reduction of an excessive skin envelope. The operation is

Fig. 7.17 Skin-sparing mastectomies (Carlson classification)



suitable for patients with large-sized breasts (jugulum-nipple distance >25 cm) and a severe degree of ptosis (areola to inframammary fold distance >8 cm). The operation must be suitably planned: the degree of possible skin reduction must be carefully measured, and, when oncologically safe, the NAC will be conserved (through its reimplantation at the end of operation or conservation of a dermal bridge). This operation is often combined with a breast reduction or contralateral mastopexy. This technique combines the skin incision used for reductive mammoplasty based on the lower pedicle with the conservation of a dermal flap, whose final role is to be part of the lower cover of the prosthetic implant. Mastectomy is then carried out. Reconstruction starts with the sectioning of the lower medial fibers of the pectoralis major muscle which are successively sutured to the upper edge of the lower dermal flap. The implant is then inserted in the pocket, which will be closed laterally with the fascia of anterior serratus muscle.

References

1. Ashikari R, Hadju S, Robbins G. Intraductal carcinoma of the breast. *Cancer*. 1971;28:1182–7.
2. Silverstein MJ. Ductal carcinoma in situ of the breast. *Ann Rev Med*. 2000;51:17–32.
3. Veronesi U, Cascinelli N, Mariani L, et al. Twenty-year follow-up of a randomized study comparing breast-conserving surgery with radical mastectomy for early breast cancer. *N Engl J Med*. 2002;347:1227–32.
4. Baxter N, Virnig B, Durham S, et al. Trends in the treatment of ductal carcinoma in situ of the breast. *J Natl Cancer Inst*. 2004;96:443–8.
5. Silverstein MJ, Lagios M, Martino S, et al. Outcome after local recurrence in patients with ductal carcinoma in situ of the breast. *J Clin Oncol*. 1998;16:1367–73.
6. Romero L, Klein L, Ye W, et al. Outcome after invasive recurrence in patients with ductal carcinoma in situ of the breast. *Am J Surg*. 2004;188:371–6.
7. Patani N, Khaled Y, Al Reefy e S, Kefah M. Ductal carcinoma in situ: an update for clinician practice. *Surg Oncol*. 2011;20:23–31.
8. Silverstein MJ, Lagios M, Craig P, et al. The Van Nuys Prognostic Index for ductal carcinoma in situ. *Breast J*. 1996;2:38–40.
9. Silverstein MJ, Poller D, Craig P, et al. A prognostic index for ductal carcinoma in situ of the breast. *Cancer*. 1996;77:2267–74.
10. Goldstein NS, Vicini FA, Kestin LL, Thomas M. Differences in the pathologic features of ductal carcinoma in situ of the breast based on patient age. *Cancer*. 2000;88:2553–60.
11. Carlson RW, Allred DC, Anderson BO, et al. NCCN clinical practice guidelines in oncology: breast cancer. *J Natl Compr Canc Netw*. 2009;7:122–92.
12. Allred D, Bryant J, Land S, et al. Estrogen receptor expression as a predictive marker of effectiveness of tamoxifen in the treatment of DCIS: findings from NSABP protocol B-24. *Breast Cancer Res Treat*. 2003;76(Suppl 1):36.
13. Moran MS, Schnitt SJ, Giuliano AE, Harris JR, Khan SA, Horton J, Klimberg S, Chavez-MacGregor M, Freedman G, Houssami N, Johnson PL, Morrow M. Society of Surgical Oncology–American Society for Radiation Oncology consensus guideline on margins for breast-conserving surgery with whole-breast irradiation in stages I and II invasive breast cancer. *J Clin Oncol*. 2014.
14. NCCN. NCCN clinical practice guidelines in oncology (NCCN guidelines). 2016.
15. EBCTC Group. Favorable and unfavorable effects on long-term survival of radiotherapy for early breast cancer: an overview of the randomized trials. *Lancet*. 2006;2000:1757–70.
16. Giordano S, Kuo Y, Freeman J, et al. Risk of cardiac death after adjuvant radiotherapy for breast cancer. *J Natl Cancer Inst*. 2005;97:419–24.

17. Darby S, McGale P, Peto R, et al. Mortality from cardiovascular disease more than 10 years after radiotherapy for breast cancer: nationwide cohort study of 90,000 Swedish women. *BMJ*. 2003;326:256–7.
18. Darby S, Taylor C, McGale P, et al. Long-term mortality for heart disease and lung cancer after radiotherapy for early breast cancer: prospective cohort study of about 300,000 women in US SEER cancer registries. *Lancet Oncol*. 2005;2005:557–65.
19. Zablotska L, Neugut A. Lung carcinoma after radiation therapy in women treated with lumpectomy or mastectomy for primary breast carcinoma. *Cancer*. 2003;97:1401–11.
20. Rosen PP, Snyder RE, Robbins G. Specimen radiography for nonpalpable breast lesions found by mammography: procedures and results. *Cancer*. 1974;34(6):2028–33.
21. Tamimi RM, Baer HJ, Marotti J, Galan M, Galaburda L, Fu Y, Deitz AC, Connolly JL, Schnitt SJ, Colditz GA, Collins LC. Comparison of molecular phenotypes of ductal carcinoma in situ and invasive breast cancer. *Breast Cancer Res*. 2008;10:R67.
22. Huston TL, Pigalarga R, Osborne MP, Tousimis E. The influence of additional surgical margins on the total specimen volume excised and the reoperative rate after breast-conserving surgery. *Am J Surg*. 2006;192:509–12.
23. Decker MR, Trentham-Dietz A, Loconte NK, Neuman HB, Smith MA, Punglia RS, Greenberg CC, Wilke LG. The role of intraoperative pathologic assessment in the surgical management of ductal carcinoma in situ. *Ann Surg Oncol*. 2016;23(9):2788–94.
24. Wilson RA, Zavislan JM, Schiffhauer LM. Optical segmentation of unprocessed breast tissue for margin assessment. *Breast*. 2014;23:413–22.
25. Thill M, Dittmer C, Baumann K, Friedrichs K, Blohmer JU. MarginProbe®—final results of the German post-market study in breast conserving surgery of ductal carcinoma in situ. *Breast*. 2014;23(1):94–6.
26. Buggi F, Mingozi M, Curcio A, Rossi C, Nanni O, Bedei L, Sanna PA, Veltri S, Folli S. Intraoperative radiological margins assessment in conservative treatment for non-palpable DCIS: correlation to pathological examination and re-excision rate. *SpringerPlus*. 2013;2(1):243.
27. Yang JD, Lee JW, Cho YK, et al. Surgical techniques for personalized oncoplastic surgery in breast cancer patients with small-to moderate-sized breasts (part 1): volume displacement. *J Breast Cancer*. 2012;15:1–6.
28. Yang JD, Lee JW, Choe YK, et al. Surgical techniques for personalized oncoplastic surgery in breast cancer patients with small-to moderate-sized breasts (part 2): volume replacement. *J Breast Cancer*. 2012;15:7–14.
29. Yang JD, Kim MC, Lee JW, et al. Usefulness of oncoplastic volume replacement techniques after breast conserving surgery in small to moderate-sized breasts. *Arch Plast Surg*. 2012;39:489–96.
30. Anderson BO, Masetti R, Silverstein MJ. Oncoplastic approaches to partial mastectomy: an overview of volume-displacement techniques. *Lancet Oncol*. 2005;6:145–57.
31. White J, Achuthan R, Turton P, Lansdown M. Breast conservation surgery: state of the art. *Int J Breast Cancer*. 2011;2011:107981.
32. American College of Radiology. Breast imaging reporting and data system (BIRADS). Reston: American College of Radiology; 2003.
33. Clough KB, Kaufmann GJ, Nos C, et al. Improving breast cancer surgery: a classification and quadrant per quadrant atlas for oncoplastic surgery. *Ann Surg Oncol*. 2010;17:1375–91.
34. Ribeiro L. Creation and evolution of 30 years of the inferior pedicle in reduction mammoplasties. *Plast Reconstr Surg*. 2002;110:960–70.
35. Robbins TH. A reduction mammoplasty with the areola-nipple based on an inferior dermal pedicle. *Plast Reconstr Surg*. 1977;59:64–7.
36. Pitanguy I. Surgical treatment of breast hypertrophy. *Br J Plast Surg*. 1967;20:78–85.
37. Lejour M. Vertical mammoplasty and liposuction of the breast. *Plast Reconstr Surg*. 1994;94:100–14.
38. Benelli L. A new periareolar mammoplasty: the “round-block” technique. *Aesthetic Plast Surg*. 1990;14:93–100.
39. Berrino P, Campora E, Santi P. Postquadrantectomy breast deformities: classification and techniques of surgical correction. *Plast Reconstr Surg*. 1987;79:567–72.

40. Halsted WS. Clinical and histological study of certain adenocarcinoma of the breast: and a brief consideration of the supraclavicular operation and of the results of operations for cancer of the breast from 1889 to 1898 at the Johns Hopkins Hospital. *Ann Surg.* 1898;28:557–76.
41. Patey DH, Dyson WH. Modified radical mastectomy. *Br J Cancer.* 1948;2:7–13.
42. Madden JL. Modified radical mastectomy. *Surg Gynecol Obstet.* 1965;121:221–30.
43. Veronesi U, et al. Comparing radical mastectomy with quadrantectomy, axillary dissection and radiotherapy in patients with small cancers of the breast. *N Engl J Med.* 1981;30:6–11.
44. Freeman BS. Subcutaneous mastectomy for benign breast lesions with immediate delayed prosthetic replacement. *Plast Reconstr Surg.* 1962;30:676–82.
45. Hinton CP, et al. Subcutaneous mastectomy for primary operable breast cancer. *Br J Surg.* 1984;71:469–72.
46. Toth B, Lappert P. Modified skin incision for mastectomy: the need for plastic surgical input in pre-operative planning. *Plast Reconstr Surg.* 1991;87:1048–53.
47. Kroll SS, et al. The oncologic risks of skin preservation at mastectomy when combined with immediate reconstruction of the breast. *Surg Gynecol Obstet.* 1991;172:17–20.
48. Verheyden CN. Nipple-sparing mastectomy of large breast. *ASPS Am Soc Plastic Surg.* 1998;101:1494–500.
49. Petit JY, Veronesi U, Martella S, et al. The nipple sparing mastectomy: early results of a feasibility study of a new application of perioperative radiotherapy (ELIOT) in the treatment of breast cancer when mastectomy is indicated. *Tumori.* 2003;89:288–91.
50. Beer GM, et al. Incidence of superficial fascia and its relevance in skin-sparing mastectomy. *Cancer.* 2002;94(6):1619–25.
51. Robertson SA, Rusby JE, Cutress RI. Determinant of optimal mastectomy skin flap thickness. *Br J Surg.* 2014;101:899–911.
52. Hicken NF. Mastectomy: a clinical pathologic study demonstrating why most mastectomies result in incomplete removal of mammary gland. *Arch Surg.* 1940;40:6–14.
53. Bedrosian I, Hu CY, Chang GJ. Population-based study of contralateral prophylactic mastectomy and survival outcomes of breast cancer patients. *J Natl Cancer Inst.* 2010;102:401–9.
54. Folli S, Curcio A, Buggi F, et al. Improved sub-areolar breast tissue removal in nipple-sparing mastectomy using hydrodissection. *Breast.* 2012;21:190–3.
55. Carlson GW, Bostwick J III, Styblo TM, et al. Skin sparing mastectomy. *Ann Surg.* 1997;5:570–8.
56. Cunnick GH. Skin sparing mastectomy. *Am J Surg.* 2003;188:78–84.
57. Carlson GW. Local recurrence after skin-sparing mastectomy: tumor biology or surgical conservatism? *Ann Surg Oncol.* 2003;10:108–12.
58. Toth BA, Forley BG, Calabria R. Retrospective study of the skin-sparing mastectomy in breast reconstruction. *Plast Reconstr Surg.* 1999;104:77–84.
59. Torresan RZ, Dos Santos CC, Okamura H, et al. Evaluation of residual glandular tissue after skin-sparing mastectomies. *Ann Surg Oncol.* 2005;12:1037–44.
60. Carlson GW. Technical advances in skin sparing mastectomy. *Int J Surg Oncol.* 2011.
61. Hunter JE, Malata CM. Refinements of the Lejour vertical mammoplasty skin pattern for skin-sparing mastectomy and immediate breast reconstruction. *J Plast Reconstr Surg.* 2007;60:471–81.
62. Blair SL, Thompson K, Rococco J, Malcarne V, Beitsch PD, Ollila DW. Attaining negative margins in breast-conservation operations: is there a consensus among breast surgeons? *J Am Coll Surg.* 2009;209:608–13.
63. Taghian A, Mohiuddin M, Jagsi R, Ceilley E, Powell S. Current perceptions regarding surgical margin status after breast-conserving therapy: results of a survey. *Ann Surg.* 2005;241:629–39.
64. Adams BJ, Zoon CK, Stevenson C, Chitnavis P, Wolfe L, Bear HD. The role of margin status and reexcision in local recurrence following breast conservation surgery. *Ann Surg Oncol.* 2013;20:2250–5.

Surgical Treatment of DCIS: Breast Reconstruction

8

Carla Cedolini, Serena Bertozzi, Ambrogio Pietro Londero,
and Pier Camillo Parodi

Surgical treatment of ductal carcinoma in situ remains an argument of great debate due to its frequent multifocality or multicentricity. Therefore, no standardized treatment exists, but every patient should be individually studied to decide which treatment is best. In this perspective, the always wider use of magnetic resonance imaging determined a significant increase in the number of primary mastectomies, with a consensual decrease of margins widening after conservative surgery. In this chapter, we will discuss breast reconstruction after surgery for ductal carcinoma in situ, including breast remodeling after breast conservative surgery as well as breast reconstruction techniques after mastectomy.

C. Cedolini

Breast Unit, University Hospital of Udine 33100 Udine (UD), Italy

Clinic of Surgery, University Hospital of Udine 33100 Udine (UD), Italy

e-mail: carla.cedolini@asuud.sanita.fvg.it

S. Bertozzi

Breast Unit, University Hospital of Udine 33100 Udine (UD), Italy

A.P. Londero

Unit of Obstetrics and Gynecology, Hospital of Monfalcone 34074 Monfalcone (GO), Italy

P.C. Parodi (✉)

Clinic of Plastic and Reconstructive Surgery, University Hospital of Udine
33100 Udine (UD), Italy

e-mail: pcparodi@hotmail.com

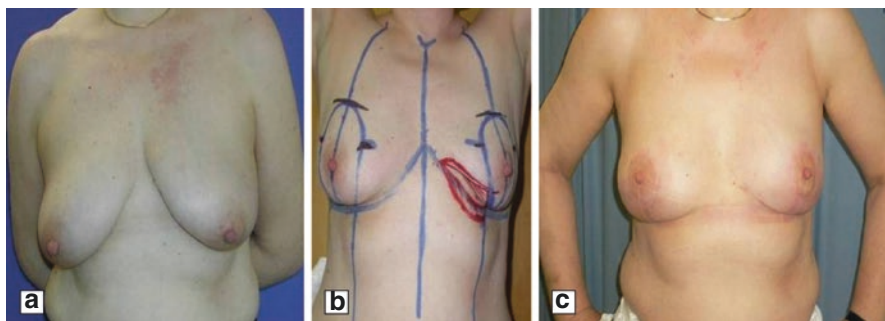


Fig. 8.1 Modeling quart with bilateral breast reduction surgery. Presurgery (a); model of surgery (b); postsurgery (c)

The plastic surgeon has a very important role in tailoring the best surgical option for breast reconstruction and its appropriate timing. The selection of the best reconstructive option involves many factors, including patient expectations, physical appearance, and surgical and nonsurgical treatment. The plastic surgeon is responsible to lead the patient through the decision-making process in order to optimize the outcome of reconstructive surgery.

8.1 Breast Remodeling

Breast remodeling represents the most frequent reconstructive technique after breast-conserving surgery, including both small lumpectomies and wider breast quadrantectomies. It simply consists of mobilizing residual mammary gland tissue from the skin superficially and deeply from the pectoralis major muscle to give the breast the best shape as possible (Fig. 8.1).

This procedure, as well as the site and length of skin incision, should be planned accurately before oncological surgery. After quadrantectomy, all surgical specimens should be weighed to have a precise idea of the quantity of mammary tissue removed. In the case of an important difference in the shape or weight between the healthy breast and the operated one, the contralateral breast could be remodeled.

In particular, in the case of significant breast ptosis, contralateral mastopexy could be purposed. Moreover, in the case of large breast volume, contralateral skin-reducing mastoplasty could be planned, usually together with a nipple-areola complex repositioning. All of these techniques are better explained in the following sections.

8.2 Free Dermal Fat Graft

This technique can be used in any case of breast tissue removal that cannot be successfully replaced by a simple remodeling of the glandular shape. Based on the quadrantectomy specimen size and weight, the free dermal fat graft site is drawn on the inferior abdominal wall. Different from the traditional Kijama technique [1], which excises abundant suprapubic tissue to design it on the breast defect site and

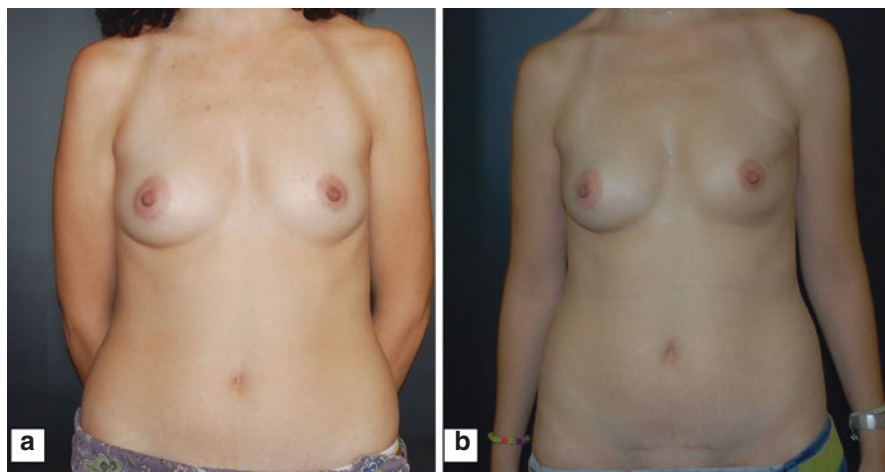


Fig. 8.2 Cosmetic assessment at 18-month follow-up after dermo-hypodermic graft surgery. In the panels, one case is shown. Presurgery (a), postsurgery case 1 (surgery site in left breast upper external quadrant) (b)

consequently wastes some tissue, in our setting a tissue lozenge is excised with a major and a minor diameter and is cut into two parts to duplicate its minor diameter. In accordance with Kijima, we observed that graft size is maintained with the passage of time, so sizing it using dimensions larger than the actual measurements is not required[2].

Suprapubic tissue is then transferred within any breast defect on an adequate receiving bed, i.e., the pectoralis muscle. In particular, a suprapubic area is initially disepithelialized with the accurate preservation of derma vascularization, which is very important for its consequent engraftment. Then, the graft is excised by cold scalpel with a maximal thickness of 2-5 cm, cut, and sutured as previously described, weighed, and finally transferred within the receiving breast area. The graft dermal side is sutured to the pectoralis muscle surface using separate absorbable stitches 3/0 (Fig. 8.2).

Before wound closure, drainage is placed in the graft site, which is maintained in aspiration modality for approximately 24-48 h. Medication of the donor and the receiving areas are performed respectively with mild compression and plate dressing.

8.3 Implant-Based Reconstruction

Implant-based reconstruction represents the most common reconstructive technique after mastectomy. The choice of temporary expanders or definitive implants depends primarily on the quantity of residual skin after surgery and consequently on the type of mastectomy. In particular, definitive prosthesis may be used after nipple-sparing mastectomies or skin-sparing mastectomies accompanied by eventual contralateral skin-reducing mastoplasty, whereas tissue expanders may be indicated after modified total mastectomies or after skin-sparing mastectomies without sufficient residual volume for the definitive implant.

Skin-sparing mastectomy is performed in case of multicentric, extensive, or recurrent lesions and early-stage breast cancer for which breast-conserving therapy results are not suitable, by removing the breast (breast parenchyma and nipple-areola complex), the lining over the pectoralis major, and the biopsy scar but sparing breast skin and the pectoralis major muscle. Skin involvement by the tumor was considered an absolute contraindication. Selection criteria for nipple-sparing mastectomy include no gross clinical, radiographic, or pathologic involvement of the nipple-areola complex, a peripheral cancer location in the breast parenchyma (distance from the nipple-areola complex ≥ 1 cm), and a clinically negative axilla. And nipple-sparing mastectomy is performed as skin sparing mastectomy but skin incision is inframammary and the nipple- areola complex is conserved.

In case of nipple-sparing mastectomy, the subcutaneous dissection under the areola is aimed at removing the glandular and ductal tissue without compromising the vascularization of the nipple-areola complex (Figs. 8.3, 8.4, and 8.5). In case of positive histology by routine intraoperative frozen section of ducts beneath the areola, the nipple- areola complex is removed before proceeding to wound closure. In addition, the breast surgeon could decide to remove the NAC before radiotherapy in case of high risk for NAC necrosis because of poor blood supply.

Reconstruction of the breast with tissue expanders can be performed either immediately at the time of mastectomy or in a delayed modality in a minimum of two stages (Figs. 8.6 and 8.7). Placement of a tissue expander immediately after mastectomy allows the preservation of the overlying skin and the avoidance of the scarring and contracture of the skin that usually occurs when reconstruction is delayed. Conversely, immediate breast reconstruction is burdened by higher risk of skin flap necrosis, hematoma, and infection [3, 4].

The only absolute contraindications for implant-based breast reconstruction are local infections or an insufficient amount of skin to cover the tissue expander after mastectomy. Relative contraindications include previous breast radiation therapy,

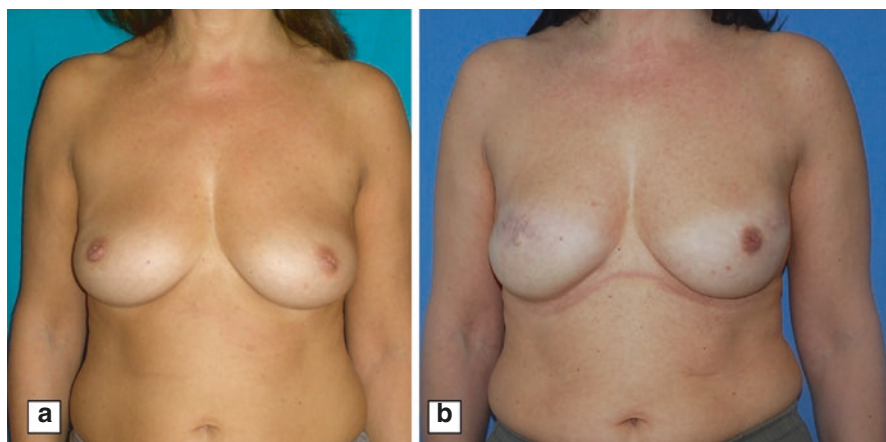


Fig. 8.3 Left nipple-sparing mastectomy and previous right skin-sparing mastectomy. Presurgery (a); postsurgery (b)

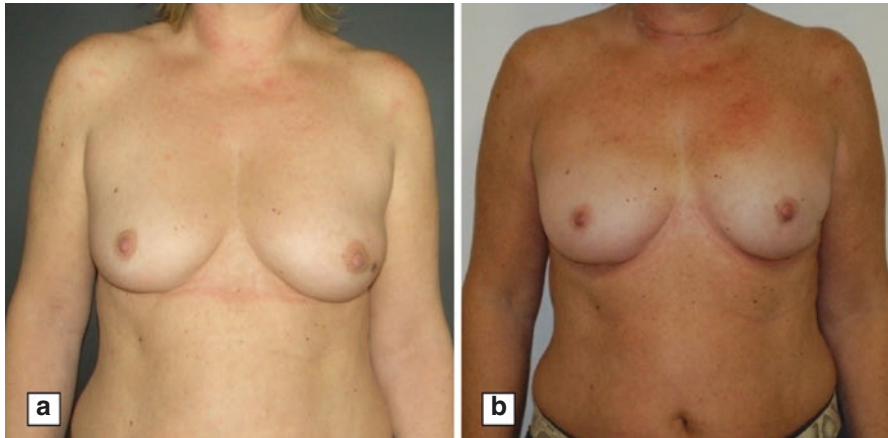


Fig. 8.4 Left nipple-sparing mastectomy and reconstruction with permanent prosthesis and ADM. Presurgery (a); 2 years postsurgery (b)

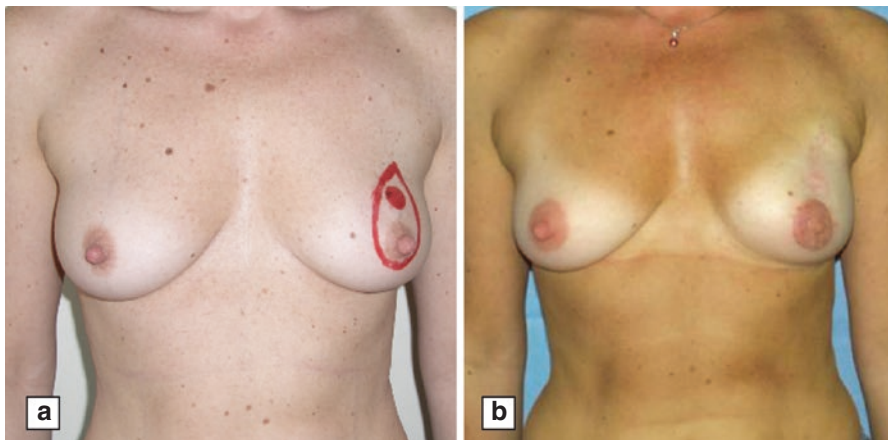


Fig. 8.5 Nipple-sparing with nipple reconstruction and final prosthesis placement. Presurgery (a); postsurgery (b)

high quantity of tobacco smoke in patients who are candidates for two-staged reconstruction, and obesity [5–10].

Tissue expander is placed in a submuscular pocket under pectoralis major muscle. Although some plastic surgeons still advocate placement of the expander only partially in the submuscular position under the pectoralis major, leaving the inferior portion subcutaneous, the complete muscle coverage provides the most protection to the prosthesis in the event of mastectomy skin flap necrosis. In the case of incomplete coverage of the inferolateral portion of the expander, due to individual muscle characteristics or to partial muscle resection for oncological reasons, acellular dermal matrix has been recently introduced, which provides total coverage of the expander with less pain by avoiding dissection of the serratus and rectus fascia [11, 12].

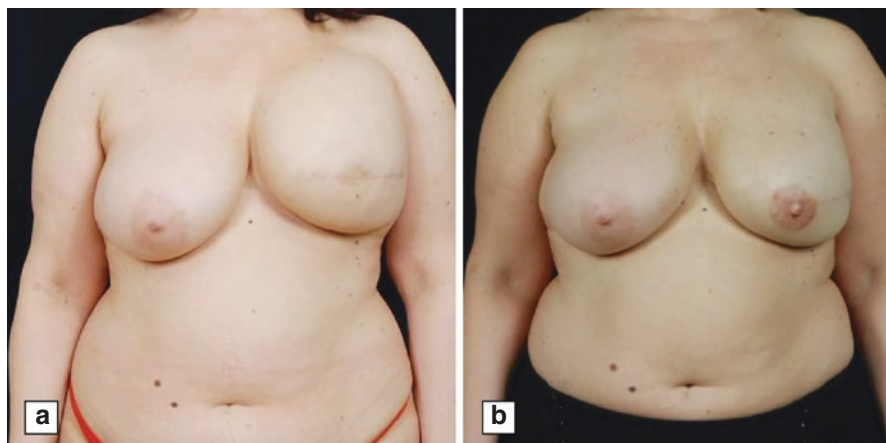


Fig. 8.6 Reconstruction with expander and secondary placement of permanent prosthesis, nipple reconstruction with local flaps and tattoo. Expander (a); after final surgery (b)

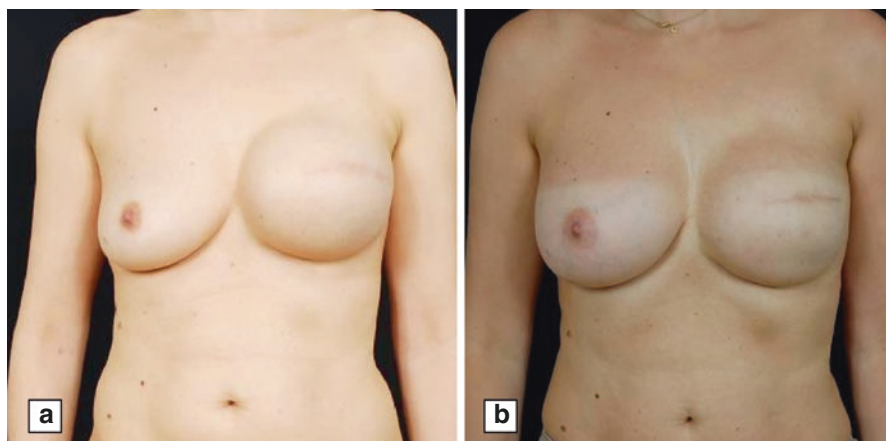
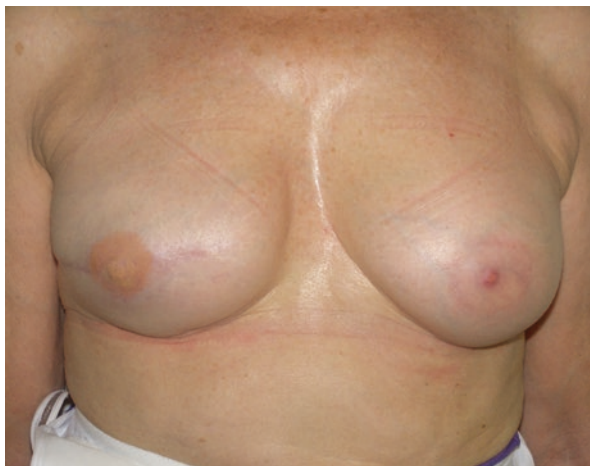

Fig. 8.7 Replacing expander with prosthesis. Expander (a); permanent prosthesis (b)

The availability of skin after mastectomy and the size of the muscle pocket limit the volume of intraoperatively injected fluid into the tissue expander. Obviously, the creation of a larger pocket reduces the number of postoperative tissue expansions with a consequent shortening of the whole reconstructive process.

The two-stage approach implies a serial postoperative expansion of the implant with 60-150 cc at a time or as tolerated by the patient until the desired volume is reached. After 1-6 months of maintenance of the desired volume, it is possible to proceed to the next stage, when the tissue expander is exchanged with the permanent implant. In this occasion, it is possible to perform capsulotomy and reshaping of the breast pocket to correct minor asymmetries and to enhance the texture and appearance of the reconstructed breast. When the anesthesiologic risk exceeds the benefits of the two-stage technique, for example in older women or those with many comorbidities, immediate implant placement is preferable, eventually using

Fig. 8.8 Nipple reconstruction



acellular dermal matrix (Fig. 8.4) but does not guarantee natural shape and appearance. A third stage may be sometimes required, for example, for the nipple reconstruction or nipple repositioning (Fig. 8.8).

Taking into consideration the adjuvant therapies, tissue expansion should be ideally performed during chemotherapy course, and its exchange within a permanent prosthesis should be ultimate before radiation therapy initiation. This delicate argument will be debated in the next sections.

Finally, it is important to remember the impact of implant-based reconstruction on breast cancer detection. Mammography results not indicated for breasts reconstructed with prosthesis, so that follow-up is made by regular ultrasound examination. In case of difficult imaging interpretation, magnetic resonance imaging may be very useful to exclude disease recurrences.

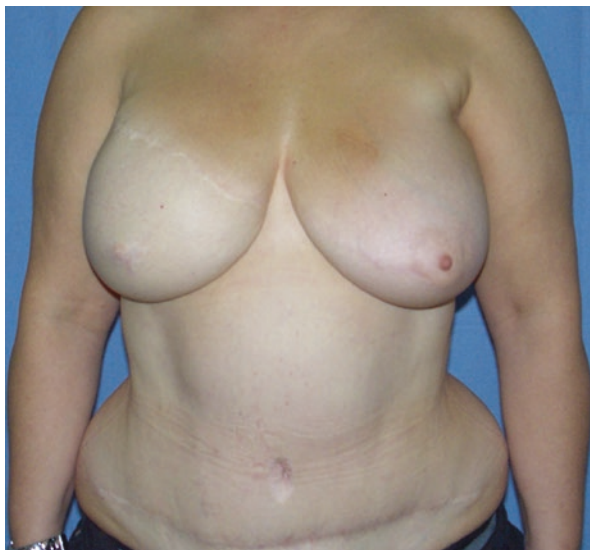8.4 Autologous Tissue Reconstruction

This kind of reconstruction is based on the use of autologous tissue, including myocutaneous flaps, fat dermal grafts (already discussed in a previous section), and simple fat grafts (lipofilling, which will be discussed in a following section).

Myocutaneous flaps have been almost completely replaced by prosthesis reconstruction, which surely implies a simpler and shorter operation. On the other hand, myocutaneous flaps do not require a two-stage surgery, and the aesthetic outcome of autologous reconstruction results obviously better than that of prosthetic surgery. In particular, autologous tissue follows the changes of the whole body, so that if the patient increases or decreases in weight, she does not lose the symmetry of her breasts, which usually seem more natural over the time.

Latissimus dorsi myocutaneous (LDM) flap is commonly used as a salvage procedure in failed reconstructions with other methods, in obese patients where implant will not provide enough volume or definition, and in patients who are not candidates to undergo a transverse rectus abdominis myocutaneous (TRAM) flap [13–15]

Fig. 8.9 Ten years postoperative result after TRAM flap with contralateral symmetrization



(Fig. 8.9). Absolute contraindications to LDM flap include previous posterior thoracotomy and injury of the thoracodorsal pedicle, for example due to previous extensive axillary surgery.

The LDM flap has a single dominant blood supply from the thoracodorsal artery and a segmental supply via perforators branching from the lumbar and posterior intercostal arteries. The integrity of the pedicle can be preoperatively simply tested by assessing the integrity of the nerve, which has the same course of the artery, thus assessing the function of muscle contraction by having the patient actively flex the latissimus dorsi muscle.

A skin paddle with a width of up to 8-10 cm can be harvested and closed primarily depending on patient skin laxity. Once the flap is elevated, it is passed into the breast defect through a tunnel created high in the axilla. The donor site is closed in layers over drains, which will remain in place for several days before the drainage is adequately low to allow their removal. The flap is then sutured to the pectoralis muscle superiorly and the inframammary fold inferiorly and to the chest wall laterally to cover the mastectomy skin defect. Because of the excellent blood supply afforded by the thoracodorsal vessels, LDM flap loss is very rare.

Transverse rectus abdominis myocutaneous (TRAM) flap pedicle are the superior epigastric vessels [16]. The most frequent postoperative complications after TRAM flap performance is an abdominal wall function loss with consequent abdominal bulge. Absolute contraindications to TRAM flap are a thin body habitus with insufficient abdominal pannus, and previous abdominal surgery resulting in the division of the inferior epigastric pedicle or the abdominal wall perforators. Moreover, some conditions may significantly increase fat necrosis and other

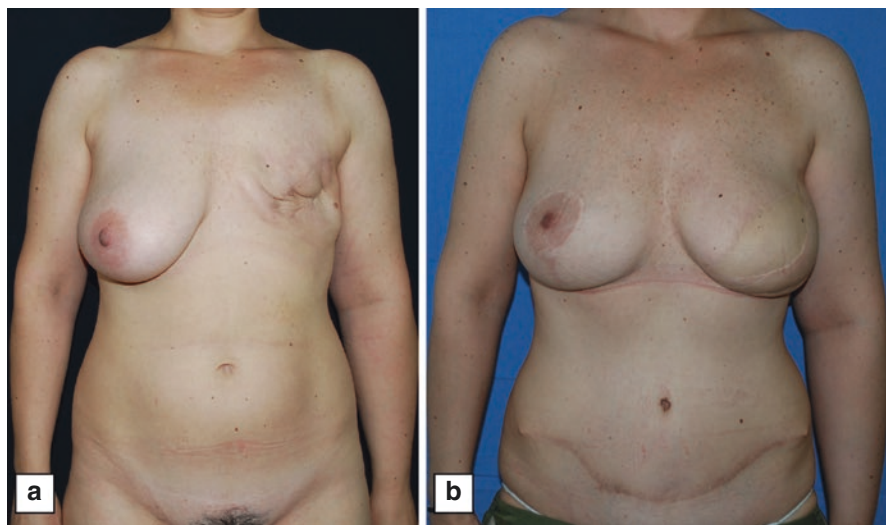


Fig. 8.10 Delayed reconstruction with DIEP

postoperative complications risk, such as smoking habits and obesity, representing relative contraindications [17–20].

Myocutaneous flaps also may be free and reimplanted through microsurgery techniques. They include free TRAM, deep inferior epigastric perforator (DIEP) (Fig. 8.10), superficial inferior epigastric artery (SIEA), superior gluteal artery perforator (SGAP), anterolateral thigh flap (ALT), and the gracilis myocutaneous flap.

8.5 Nipple-Areola Complex Reconstruction

Restoration of the nipple-areola complex after breast demolitive surgery represents a very important step for women's psychophysical wellness [21]. It consists of the establishment of a small mound of tissue that looks like a nipple, but sensation and function will not be restored (Fig. 8.8).

Nipple reconstruction may be performed immediately after breast reconstruction or more commonly delayed in the outpatient setting, especially in patient with high risk of tissue necrosis, such as those with high-volume implant reconstruction or those candidates to radiation therapy [22].

Nipple reconstruction can be accomplished either with the use of a free nipple graft from the contralateral nipple or more frequently with a multitude of well-described local flaps. Free nipple graft can be used in case of a large contralateral areola and the acceptance of smaller bilateral nipples, while local flaps can be performed in any case of breast, ideally reducing the risk of new breast cancers dependent on mammary ducts transplanted from one to the other side.

Reconstructed nipple position should adequately match with the position of the contralateral nipple, which should always be tested in the standing position. The greatest drawback to nipple reconstruction, which also is the main cause of women dissatisfaction, is the loss of long-term projection, which reaches 70% at 2 years of follow-up [23]. The areolar reconstruction is performed with either skin grafting or tattooing, considering an average diameter of approximately 4–4.5 cm.

8.6 Contralateral Breast Management

Breasts reconstructed with an implant will not undergo ptosis as does a natural breast over time. Therefore, the asymmetry after unilateral breast reconstruction with an implant will progressively worsen together with the contralateral breast natural ptosis. For this reason, a contralateral breast remodeling often is indicated.

Obviously, contralateral breast symmetrization implies an increase in postoperative complications, such as nipple sensation loss, fat necrosis, delayed wound healing, seromas, and hematoma; therefore, this kind of procedure should be extensively discussed with patients before.

Many options exist for the contralateral breast management. Depending on its size, ptosis grade, and patient's expectations, it is possible to reduce its size (skin-reducing mastoplasty), increase it (breast augmentation) (Fig. 8.11), or lift the nipple-areola complex (mastopexy) with the goal to obtain the best symmetry as possible between the two breasts.

Augmentation mastoplasty is indicated in women with very small breasts, where an implant will completely impair the symmetry between the native and reconstructed breasts. This kind of surgery can be done through a periareolar, inframammary, or axillary approach. The implant should be placed in a partially subpectoral position to minimize its palpability and facilitate mammographic visualization of breast tissue.

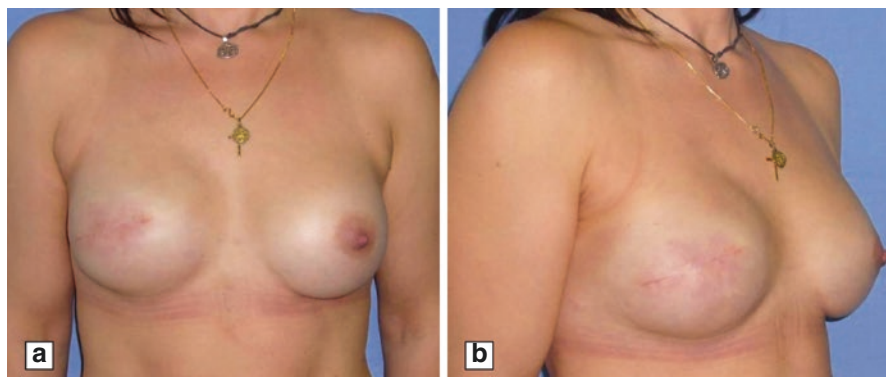


Fig. 8.11 Immediate placement of permanent prostheses and contralateral breast augmentation

Mastopexy is indicated in case of particularly ptotic native breasts, because the implant cannot provide a natural ptotic aspect. In some cases, a periareolar crescentic excision may be sufficient. In the most cases, instead, either a vertical or an inverted T-shaped scar is necessary to obtain the amount of needed lift.

Reduction mastopexy is indicated to balance reconstruction in case of very large and ptotic breasts, both after mastectomy or after conservative breast surgery. The most commonly used technique consists of the isolation of an inferior pedicle, but even a superior pedicle or a supero-medial pedicle can be performed.

Usually contralateral breast surgery is performed immediately after breast cancer surgery, but it can be performed with any timing in case of necessity. In particular, if patients undergo weight gain or loss after primary surgery, it is possible at anytime to repair breast asymmetry through one of the previously described techniques.

8.7 Lipofilling

This technique consists of the withdrawal of fat cells from fatty body parts, its elaboration with some specific instrumentation to select fat stem cells, and their consequent injection in the site of reconstruction (Fig. 8.12). The indications of lipofilling are continuously widening. In particular, in case of conservative breast surgery, lipofilling may have a role in filling small breast defects, as well as in the healing of complicated wounds due to previous infection or postoperative radiation therapy. In case of demolitive surgery, lipofilling may substitute prosthetic

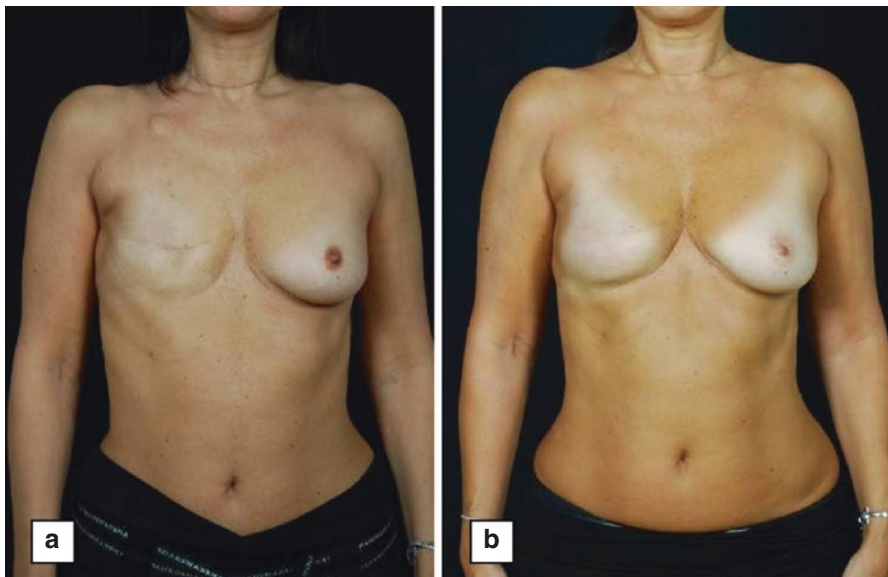


Fig. 8.12 Reconstruction with four successive lipofilling without prosthesis

reconstruction when breast size is very small and other autologous tissue reconstructions seem to be too long and difficult with similar aesthetic results.

Great debate exists about the risks related to the injection of stem cells in the site of cancer excision. The current literature supports the safety of this procedure after breast surgery in specialized centers.

8.8 Reconstruction and Radiation Therapy

Exposure of normal tissue to radiation results in typical early changes due to direct DNA damage or indirect via free radicals release or inflammation pathways, such as skin erythema, desquamation, and pruritus. Late changes include damage to small vessels, cell loss, and fibrosis, which contribute to poor wound healing and consequently worsen the aesthetic outcome in case of implant-based breast reconstruction.

The optimal algorithm for the timing of radiation therapy in patients undergoing implant based reconstruction is still evolving. In our setting, permanent implants are always preferred when possible. In case of radiotherapy indication after tissue expander placement, two possibilities are contemplated by the current literature. First, the expander could be emptied waiting for the completion of all adjuvant treatments. Obviously, this situation increases the difficulties in the following tissue expansion due to the tissutal irradiation. Moreover, there is still no certainty about radiation dose in the site of the expander valve, which may deviate x-rays. Second, the device could be expanded during chemotherapy and then promptly exchanged with the prosthesis in the period between the end of chemotherapy and radiation therapy initiation.

It also is very important to take into account any eventual previous radiation therapy to the chest wall, for example in case of lymphoma or previous breast cancer, because it usually complicates tissue expansion, increasing pain and reducing overexpansion. In this case, autologous tissue reconstruction may be more indicated.

Therefore, reconstructive surgery after mastectomy should always take into consideration the adjuvant therapies that are most likely to be required with special attention for radiation therapy and every case should be multidisciplinary discussed before intervention to plan the more appropriate surgical and nonsurgical treatment as possible.

8.9 Immediate Versus Delayed Reconstruction

The decision of whether to proceed with immediate versus delayed reconstruction is substantially determined by the woman receiving postoperative radiation therapy. The advantage of immediate breast reconstruction is obviously the avoidance of a second intervention and a second anaesthesia, as well as the shorter time of intervention due to more pliable skin. Its disadvantage is an

increased risk of postoperative complications in case of radiation therapy, including wound healing impairment, infections, implant capsule contraction, and scar worsening.

The disadvantages of a delayed breast reconstruction include longer interventions and anaesthesia times, as well as a greater operative difficulty in case of previous radiation therapy with consequent tissutal fibrosis. Therefore, delayed reconstructive surgery may be performed anytime after adjuvant therapy completion but should be discussed with the patient from case to case.

References

1. Kijima Y, Yoshinaka H, Funasako Y, et al. Immediate breast reconstruction using autologous free dermal fat grafts provides better cosmetic results for patients with upper inner cancerous lesions. *Surg Today*. 2011;41:477–89.
2. De Biasio F, Bertozzi S, Londero AP, et al. Surgical and oncological outcome of free dermal fat graft for breast reconstruction after breast conserving surgery. *Adv Clin Exp Med*. 2017 [Accepted for publication].
3. Alderman AK, Wilkins EG, Kim HM, et al. Complications in postmastectomy breast reconstruction: two-year results of the Michigan Breast Reconstruction Outcome Study. *Plast Reconstr Surg*. 2002;109:2265–74. 00401.
4. Holley DT, Toursarkissian B, Váscónez HC, et al. The ramifications of immediate reconstruction in the management of breast cancer. *Am Surg*. 1995;61:60–5. 00040.
5. Cordeiro PG, Pusic AL, Disa JJ, et al. Irradiation after immediate tissue expander/implant breast reconstruction: outcomes, complications, aesthetic results, and satisfaction among 156 patients. *Plast Reconstr Surg*. 2004;113:877–81. 00312.
6. Ascherman JA, Hanasono MM, Newman MI, et al. Implant reconstruction in breast cancer patients treated with radiation therapy. *Plast Reconstr Surg*. 2006;117:359–65.
7. Cordeiro P, McCarthy C. A single surgeon's 12-year experience with tissue expander/implant breast reconstruction: part II. An analysis of long-term complications, aesthetic outcomes, and patient satisfaction. *Plast Reconstr Surg*. 2006;118:832–9.
8. Spear S, Onyewu C. Staged breast reconstruction with saline-filled implants in the irradiated breast: recent trends and therapeutic implications. *Plast Reconstr Surg*. 2000;105:930–42.
9. Goodwin SJ, McCarthy CM, Pusic AL, et al. Complications in smokers after postmastectomy tissue expander/implant breast reconstruction. *Ann Plast Surg*. 2005;55:16–9. Discussion 19–20. 00096.
10. Woerdeman LAE, Hage JJ, Hofland MMI, et al. A prospective assessment of surgical risk factors in 400 cases of skin-sparing mastectomy and immediate breast reconstruction with implants to establish selection criteria. *Plast Reconstr Surg*. 2007;119:455–63. 00127.
11. Breuing K, Colwell A. Inferolateral AlloDerm hammock for implant coverage in breast reconstruction. *Ann Plast Surg*. 2007;59:250–5.
12. Gamboa-Bobadilla G. Implant breast reconstruction using acellular dermal matrix. *Ann Plast Surg*. 2006;56:22–5.
13. Hokin J. Mastectomy reconstruction without a prosthetic implant. *Plast Reconstr Surg*. 1983;72:810–8.
14. Germann G, Steinau H. Breast reconstruction with the extended latissimus dorsi flap. *Plast Reconstr Surg*. 1996;97:519–26.
15. Chang DW, Youssef A, Cha S, et al. Autologous breast reconstruction with the extended latissimus dorsi flap. *Plast Reconstr Surg*. 2002;110:751–9. Discussion 760–761. 00134.
16. Hartrampf C, Schefflan M, Black P. Breast reconstruction with a transverse abdominal island flap. *Plast Reconstr Surg*. 1982;69:216–25.

17. Kroll S. Necrosis of abdominoplasty and other secondary flaps after TRAM flap breast reconstruction. *Plast Reconstr Surg.* 1994;637–43.
18. Kroll SS, Gherardini G, Martin JE, et al. Fat necrosis in free and pedicled TRAM flaps. *Plast Reconstr Surg.* 1998;102:1502–7. 00146.
19. Ducic I, Spear SL, Cuoco F, et al. Safety and risk factors for breast reconstruction with pedicled transverse rectus abdominis musculocutaneous flaps: a 10-year analysis. *Ann Plast Surg.* 2005;55:559–64. 00067.
20. Spear SL, Ducic I, Cuoco F, et al. Effect of obesity on flap and donor-site complications in pedicled TRAM flap breast reconstruction. *Plast Reconstr Surg.* 2007;119:788–95. 00100.
21. Wellisch DK, Schain WS, Noone RB, et al. The psychological contribution of nipple addition in breast reconstruction. *Plast Reconstr Surg.* 1987;80:699–704. 00174.
22. Draper LB, Bui DT, Chiu ES, et al. Nipple-areola reconstruction following chest-wall irradiation for breast cancer: is it safe? *Ann Plast Surg.* 2005;55:12–5. Discussion 15. 00015.
23. Shestak KC, Gabriel A, Landecker A, et al. Assessment of long-term nipple projection: a comparison of three techniques. *Plast Reconstr Surg.* 2002;110:780–6. 00139.

Sentinel Node Biopsy in Ductal Carcinoma In Situ of the Breast

9

Matteo Ghilli and Manuela Roncella

Abbreviations

ALND	Axillary lymph node dissection
DCIS	Ductal carcinoma in situ
IHC	Immunohistochemistry
ITCs	Isolated tumour cells
SLN	Sentinel lymph node
SLNB	Sentinel lymph node biopsy
VAB	Vacuum-assisted biopsy
Vs	Versus

9.1 Introduction

Ductal carcinoma in situ is a preinvasive tumour of the breast originating from the cells that line the mammary ducts. A broad range of diseases is grouped under this term, ranging from low-grade indolent lesions to high-grade aggressive precursor of invasive tumours. From an architectural point of view, several subtypes are described: solid, cribriform, micropapillary or papillary, with or without necrosis (comedocarcinoma), with different behaviours, different potential of local relapse and different association with microinvasive or invasive carcinoma [1]. Its incidence is increasing due to the adoption of screening programmes, though without a decline

M. Ghilli (✉)

Breast Cancer Center, University Hospital of Pisa, Pisa, Italy

e-mail: matteo.ghilli@gmail.com

M. Roncella

Director, Breast Cancer Center, University Hospital of Pisa, Pisa, Italy

e-mail: manuela.roncella@gmail.com

in invasive cancer incidence. In addition, there is a strong consensus that DCIS treatment in most patients has no clear effect on mortality reduction. This suggests an overdiagnosis and an overtreatment particularly of low-grade in situ lesions that amount for a 20% of all DCIS [2].

Historically, survival for these patients is 97–100% with death presumed to be linked to the spread of unrecognized small invasive component: the risk of cancer-related death in DCIS patients is estimated at 1.9% within 10 years [3].

The treatment of the axilla in this pattern of patients represents a strong example of a debated matter and overtreatment.

9.2 From Certainties to Uncertainties

Given that DCIS is characterized by neoplastic cell proliferation within the mammary ductal system, with no evidence of invasion into the surrounding stroma, it has theoretically 0% potentiality for axillary or distant metastases by definition, and consequently there wouldn't be any role for axillary evaluation even in case of high-grade DCIS [4–7].

In fact the preoperative diagnosis of DCIS by core needle is upstaged after the final pathologic report in as many as 10–40% of cases (increasing in relation to the method of biopsy and the number/size of samples done, being more unlikely with the VAB). As a consequence, these patients require to be subsequently submitted to a separate surgical axillary procedure, with the technical difficulties related to the tracer migration and the lower detection rate at a second operation [5, 8–10].

In any case, there is currently no validated method to predict which DCIS-diagnosed women will have invasive cancer at the final pathological report, but this is not sufficient to justify performing SLNB in all DCIS diagnosis at the preoperative biopsy.

One thing is for sure: until the late 1990s, axillary dissection was indicated also in cases of DCIS; later, according to the pioneering experience of Silverstein that questioned the need for routine ALND in DCIS and recommended that it must be abandoned, the standard became SLNB.

Now the issue in these patients is “to do or to avoid sentinel node biopsy?” [11]. The ALND has no more any role in DCIS; moreover, there are precise indicators (e.g. from EUSOMA, the European Society of Breast Units) of good quality of the procedure, among which there is “Proportion of patients with DCIS who do not undergo axillary clearance” [12].

We reached this awareness also thanks to important protocols such as National Surgical Adjuvant Breast and Bowel Project NSABP B17 and B24 (and others) and their subsequent reviews where the risk of axillary recurrence in DCIS was found to be less than 1% [13–17].

Therefore, the real topic should be “how to be sure that the preoperative diagnosis of DCIS will effectively relate with a final diagnosis of pure DCIS?” [18, 19]

The centre of the matter is effectively that the reliability of pure DCIS diagnosis can only be subsequent to surgical excision, as an underestimation of the presence

of microinvasiveness and invasiveness has been described in even up to 42% of patients, when preoperative DCIS diagnosis is performed by core-needle biopsy on an area of microcalcifications [20–23].

At the same time, the rate of sentinel node positivity in DCIS is described as 1–13%; it is also reported that axillary metastases are found in about 1–2% in case of pure DCIS patients treated with axillary dissection. In a meta-analysis of more than 3000 patients, a 7.4% of sentinel node positivity has been found with a 3.7% in patients with a definitive diagnosis of pure DCIS. ASCO reports 0.9% of pN1 and 1.5% of pN1mic for patients proved to have pure DCIS on final resection [24].

For this reason the vast majority of authors traditionally believe that there is a subset of DCIS at high risk for microinvasive or invasive tumour and a little subgroup of pure DCIS anyway with positive axilla, consequently with the indication for sentinel node biopsy.

9.3 High-Risk DCIS: When SLNB Could Be Considered

In the attempt to define the subgroup of DCIS where the SLNB could be done for the high probability of an invasive component at the final diagnosis, the most important and updated guidelines (see “An overview on the main international guidelines”) **indicate SLNB in these subsets of patients:**

1. *Patients planning to undergo breast conserving surgery if there is:*
 - (a) *Palpable mass:* in a study by Jackam et al. [5], underestimation for microinvasive/invasive cancer was 1.9 times greater with masses than microcalcifications [25].
 - (b) *Mass on mammography:* Veronesi et al. studied 1258 clinically occult invasive carcinoma, finding that opacity, distortion or thickening were present in 24.6% of cases [26, 27].
 - (c) *Ultrasound mass* [4].
 - (d) *A high-grade lesion at biopsy* [4].
 - (e) *A large size:* extensive DCIS or more than 25/40 mm are often indications for mastectomy [25, 28, 29].
 - (f) *The presence of comedonecrosis in the core biopsy.*
 - (g) *Patients of young age* (it is reported to be <55 years) [4, 25].
2. *Patients for whom mastectomy is indicated:* after a total mastectomy, the lymphatic drainage pattern will be permanently altered, making it impossible to accurately perform SLNB [30].

The inability to obtain clear margins, multicentric disease, large tumour size and contraindications to radiotherapy are the indications for mastectomy in case of DCIS, but they are also risk factors for the presence of invasive cancer and consequently the presence of a possible metastatic sentinel lymph node. In a series by Tan et al. [31], 33% of patients who underwent mastectomy for DCIS had an occult

form of invasive cancer revealed by final pathology; among these patients, more than 10% were found to be positive at SLNB [31, 32].

Guillot et al. [26] made an interesting research on 241 patients with pure extensive DCIS in preoperative assessment submitted to mastectomy (from 2000 to 2009, treated at Institute Curie in Paris) followed by an axillary staging in 221 cases (109 SLNB, 93 ALND, 19 mixed procedures in the period of learning curve for SLNB). This work revealed:

- Sixty-five percent pure DCIS, 14% DCIS with microinvasion and 21% DCIS with invasive component.
- DCIS component was of high grade in 54%, with necrosis in 84%.
- Invasive component was mainly estrogen receptor positive (71%) and grade 2 (54%) with lympho-vascular invasion in 30% of cases.
- 20 patients (9%) had a metastatic axillary lymph node, and 80% and 15% had invasive and microinvasive component at final pathology, respectively, with only 1 (5%) being a pure DCIS.
- Out of 128 SLNB procedures, 11 were positive: one macro-metastasis, two micrometastasis and eight presenting tumour cells at IHC.
- Out of 50 cases with invasive carcinoma, 17 (33%) showed positive lymph nodes.

The analysis showed that palpable tumours, opacity on mammography and preoperative high-grade DCIS were significant predictors of invasiveness; BMI >25, palpable tumours and opacity on mammography were statistically significant predictors of ALN metastases. In their paper, Guillot et al. furthermore made an overview on microinvasion, invasion and axillary involvement in patients with preoperative diagnosis of pure DCIS, evaluating 11 studies published from 2005 and 2011 for a total of 2319 patients. They found that at the final pathology report, the confirmed pure DCIS were in 1312 cases (75.7%), with 6.6% of DCIS plus microinvasive carcinoma and 22% of DCIS associated with invasive carcinoma (11.3% positive for axillary lymph node metastasis). At this regard, however, we should consider the high impact of SLNB positivity detected by IHC in those works [26].

9.4 The Presence of Cancer Cells in the SLN of DCIS Patients Is a Debated Issue with a Still Unclear Significance

To make everything more complex, most of the SLN metastases of DCIS consist of micro-metastases and ITCs, and sentinel node is the only positive node usually even in case of macro-metastasis [17, 18, 33].

A new era in the management of the axilla was introduced by the revolutionary studies published by A. Giuliano et al. [34] and by V. Galimberti et al. [35]: considering patients with invasive cancer, they stated the omission of axillary clearance in case of micro-metastases or in patients treated with a conservative approach with 1–2 macro-metastatic lymph nodes. Considering this trend towards minimizing

axillary surgery for invasive cancer, trials are ongoing investigating whether a SLND can be avoided at all in clinically node-negative patients with invasive carcinoma [36].

We should therefore question ourselves about the meaning of performing the SLNB in patients with a diagnosis of DCIS.

To date, there are weak evidences in the literature about the significance of SLNB in pure DCIS: it has been shown that even a positive sentinel node in DCIS does not affect survival and is not associated with a high risk of local or distant recurrence [37–39].

Moreover, the presence of cancer cells in the SLN of DCIS patients is a debated issue with a still unclear significance. Some authors mentioned that the cells might represent the result of a mechanical displacement, a sort of micro-embolism of breast cells that have been dislodged by a sampling procedure through the lymphatic system, particularly in case of vacuum-assisted stereotactic biopsy with its multiple sampling [18, 40–42].

9.5 Review of the Main Studies on the Role of SLNB in DCIS

- Murphy et al. [43] described 322 patients with DCIS and microinvasive DCIS, with a 9% positive SLNB, with the majority being ITCs. At a median follow-up of 47.9 months, 13 (4%) had developed local recurrences and 1 distant metastasis (all but one in SLNB-negative cases).
- Lara et al. [33] reported on 102 patients with 13 (13%) with a positive SLN. However, the majority was represented by micrometastasis, and when this group was compared with the group that experienced tumour recurrence, neither shared a common patient [44].
- Seventy-one patients with DCIS and 12 with microinvasion with subsequent axillary sampling of >4 lymph nodes excised were included in a study [40], with the result of 11/83 found with positive nodes by IHC or H&E staining: 8 were ITCs, 1 was micrometastatic and 2 were found macro-metastatic. After 102 months, all patients remained free of disease.
- An Italian study examined 854 pure DCIS submitted to SLNB, finding 4 ITCs, 7 micrometastasis and 5 macro-metastasis. In this experience, 11 ALND were done with no additional positive node. At a median follow-up of 41 months, 2 locoregional recurrences were found and 1 distant recurrence in patients with positive SNBs [17, 44].
- Another paper described 43 (9.1%) positive sentinel nodes in 470 high-risk DCIS patients: 36 were ITCs, 4 micrometastases and 3 macro-metastatic. Twenty-five patients consequently underwent axillary clearance finding only one woman with an additional positive node. No local recurrences were observed, while one patient with ITCs developed metastasis at 27 months follow-up [44, 45].
- The Turkish study conducted by D.E. Boler et al. reviewed the pure DCIS cases treated in a single-institution series to identify patients who may benefit from

SLNB. Of 699 patients operated in the period of 2000–2011, 63 resulted in pure DCIS: 40/63 underwent SLNB, and 2 of them (5%) had a positive SLN (in both cases, only 1 lymph node resulted positive) [18].

Among many retrospective studies, C. Tunon-de-Lara et al. [46] published in 2015 an original paper reporting a prospective multicentric French experience. They examined the relevance of using the SLNB upfront for patients with:

- Extensive microcalcifications on mammography
- Treated by mastectomy
- With a VAB preoperative diagnosis of DCIS

The study was effectively designed for establishing the rate of needless ALND avoided (in the case of a final histology of microinvasive/invasive carcinoma). Other endpoints were the underestimation of invasion by VAB itself, the rates of SLND and the positive sentinel nodes. The results showed:

- One hundred ninety patients enrolled (pure DCIS at vacuum-assisted biopsy) and submitted to SLNB.
- One hundred fourteen patients had confirmed their original diagnosis of pure DCIS: among them, 112 had negative SLNB, while 2 presented a positive lymph node.
- Twenty patients were upstaged to microinvasive carcinoma: among them, 16 had negative SLNB, while 4 presented a positive lymph node.
- Fifty-six patients were upstaged to invasive carcinoma: among them, 35 had negative SLNB, while 21 presented a positive lymph node.
- In effect, 51 patients among microinvasive/invasive cancers had negative sentinel nodes and had an unnecessary ALND avoided (67%)
- Thirty-nine percent of patients with a diagnosis of pure DCIS at VAB were subsequently upgraded with a rate of positive sentinel lymph nodes in this group of 13%.
- The presence of necrosis and the high nuclear grade resulted in an association to microinvasion or invasion.
- For microinvasive/invasive cancer associated to DCIS, the overall rate of positive sentinel nodes was 33% (25% excluding ITCs) that is significantly higher than other reported data [46, 47].

Another original clinical trial by L.M. van Roozendaal [39] in 2016 included 910 DCIS patients treated in the Netherlands between 2004 and 2013, with the following results:

- Nine hundred ten patients enrolled (pure DCIS at vacuum-assisted biopsy) with a final diagnosis confirmed as pure DCIS (group A) in 758 cases (83.3%) and an upstaging to invasive component in 152 cases (16.7%) (group B).
- Group A (pure DCIS): among them, 349 underwent the SLNB (46%). Of these, 330 (94.6%) resulted pN0, 3.4% resulted positive for ITCs, 1.7% resulted pN1mi and 0.3% resulted pN1.

- Group B (invasive component plus DCIS): among them, 122 underwent the SLNB (80.3%). Of these, 97 (79.5%) resulted pN0, 4.9% positive for ITCs, 6.6% resulted pN1mi and 9% pN1.

The authors evaluated the results as consistent with other two recent studies [48, 49] that showed 2.9% pN1mi and 2.4% pN1 with 21% invasive breast cancer and 0%, 0.5% and 30%, respectively [39].

9.6 The Influence of Other Factors: Volume of Procedures and Expertise

Coromilas et al. [50] published in 2015 on JAMA Oncology an interesting retrospective research about the influence of hospital- and surgeon-related factors on performing any kind of axillary lymph node surgery in DCIS. Looking at 35,591 women who were diagnosed with DCIS and consequently had lumpectomy or mastectomy between 2006 and 2012, the authors found:

- 74.7% lumpectomy and 25.3% mastectomy.
- 53.8% women were treated at small hospitals (with fewer than 400 beds) and 18.5% treated at large hospitals (more than 600 beds).
- Looking at hospitals, DCIS surgeries ranged from 1 to 102/year, while DCIS surgeries per surgeon ranged from 1 to 23.8/year.
- The researchers classified hospitals and surgeons in high/medium/low volume considering the procedures per year.
- Among mastectomies:
 - 63% had some type of lymph node surgery:
 - 15.2% axillary lymph node dissection
 - 47.8% SLNB
- Among quadrantectomies:
 - 17.7% had some type of lymph node surgery:
 - 1.0% axillary node dissection
 - 16.7% SLNB
- Fortunately, the rates of axillary node dissection increased, and those of sentinel node surgery decreased during the time period the researchers studied:
 - For women having mastectomy:
 - 20.0% had ALND in 2006 and 10.7% in 2012.
 - 36.5% had SLNB in 2006 and 56.7% in 2012.
 - For women having lumpectomy:
 - 1.2% had ALND in 2006 and 0.3% in 2012.
 - 17.3% had SLNB in 2006 and 15.9% in 2012.
- Coromilas et al. reported that women with DCIS who had lumpectomy were more likely to have some type of lymph node surgery if:
 - They were treated at a non-teaching hospital.
 - They were treated by a low- or medium-volume surgeon.

- The matter of fact is that nearly 18% of the women who had lumpectomy to remove DCIS had some type of lymph node surgery, despite ASCO recommendations against the procedure. About 15% of the women who had mastectomy had axillary node clearance, despite ASCO recommendations that indicate sentinel node biopsy.

9.7 An Overview on the Main International Guidelines

9.7.1 American College of Radiology 2015 [51]

SLNB in DCIS is indicated in case of:

- Mastectomy (>10% risk of occult invasive disease and >10% SLN positivity)
- DCIS with radiographic evidence of extensive disease or diameter >25 mm

9.7.2 ASCO Clinical Practice Guideline Update 2014 [52–53]

SLNB in DCIS is indicated in case of:

- Mastectomy: type, informal consensus; benefits outweigh harms; evidence quality, insufficient; strength of recommendation, weak.
- Not to be performed in case of breast-conserving surgery: type, informal consensus; evidence quality insufficient; strength of recommendation strong.
- Qualifying statements: clinicians may perform SLNB for DCIS diagnosed by core needle biopsy (one, when mastectomy is planned, because this precludes subsequent SLNB at a second operation; two, when physical examination or imaging shows a mass lesion highly suggestive of invasive cancer; or three, the area of DCIS by imaging is large (>5 cm)).

9.7.3 NABON 2012 Version 2.0 (Dutch Breast Cancer Guidelines) [54]

SLNB in DCIS is indicated in case of:

- A sentinel node procedure should be considered for patients with a preoperative diagnosis of DCIS for whom a mastectomy is indicated due to size and patients with a small DCIS who are eligible for BCT, in which there are risk factors for an invasive component: younger than 55 years or solid component on the mammogram or suspicions on the basis of histological biopsies or moderate or poorly differentiated DCIS in biopsies.
- For pure DCIS, diagnosed by excision biopsy, the chance of lymph node metastasis is extremely small.

- In patients in whom DCIS is determined using histological biopsies of lesions greater than 2.5 cm, the presence of lymph node metastasis is at least 7%. The chance of diagnosing invasive ductal carcinoma with DCIS is related to the type of biopsy needle (11G vs 14G), the grade of DCIS (high grade versus low grade), the size of the lesion on the mammogram (>20 mm vs ≤20 mm), the mass on mammography (mass vs microcalcifications only) and if the growth is palpable (palpable vs non-palpable).

9.7.4 NICE 2009 [55]

SLNB in DCIS has these indications:

- Do not perform SLNB routinely in patients with a preoperative diagnosis of DCIS who are having breast-conserving surgery, unless they are considered to be at a high risk of invasive disease.
- Offer SLNB to all patients who are having a mastectomy for DCIS.

It's finally important to mention a further concept pointed in the NCCN 2.2016 version of breast cancer guidelines [56]: “the performance of a sentinel node procedure should be strongly considered if the patient with apparent pure DCIS is to be treated with mastectomy or with excision in an anatomic location compromising the performance of a future SLNB”.

In the experience of a breast surgeon, it refers particularly to retroareolar excisions (e.g. in case of nipple discharge due to DCIS) that are likely to compromise the structure of the lymphatic plexus that is anatomically set behind the nipple-areolar complex. Another similar situation is represented by the major oncoplastic approaches, more and more frequent, where the structure of the entire breast is modified with consequences on the lymphatic drainage.

9.8 Is SLNB Not Associated to Morbidities?

The most common morbidities following ALND are also present in patients receiving SLNB: they are represented by lymphoedema, persistent pain, nerve injury, paraesthesias, numbness, decreased limb use and shoulder dysfunction [34–39G].

If the studies revealed a significant difference from 25% to 70% when comparing SLNB alone to ALND, on the other side, we should consider that up to a year following SLNB, lymphoedema and paraesthesia persisted. Therefore, although SLNB shows benefit over ALND, surgeons must consider the risk and benefits of this procedure in case of minimal disease in relation to the possible side effects.

Coromilas et al. conducted a retrospective cohort study reporting more than 10,000 women affected by DCIS who underwent surgery between 2002 and 2012. 18.3% of those treated with breast-conserving therapy and 69.4% of those treated with mastectomy had an axillary evaluation, in most cases a SLNB. 1 year after

treatment, 8.2% of patients with an axillary evaluation developed lymphoedema, compared to 5.9% of those who did not. The incidence of lymphoedema resulted higher among those who underwent axillary evaluation (HR 1.22). Overall 10-year breast cancer-specific survival was similar between both groups. The authors concluded that women who receive an axillary evaluation have higher rates of lymphoedema, without survival benefits [57].

Moreover, it is important to avoid unnecessary SLNB also for the risks linked to the not so unlikely event of a breast cancer recurrence after a previous lumpectomy plus SLNB: for a long time, it has been thought that in the second surgery it wouldn't be possible to repeat SLNB, with the need of an ALND in any case. However, recent experiences have shown that a second SLNB could be performed in selected cases with acceptable identification rate and false-negative rate, even if the previous surgery could have made it difficult for the drainage of the tracer itself [58–60].

9.9 A New Way of Looking at the Problem

A new vision of DCIS is required to prevent the overtreatment of indolent disease without compromising the achieved very good outcomes. Nowadays we know much more about DCIS than in the recent past, for example, the overexpression of HER2 is linked to higher distant and local recurrence rates, while the expression of p16/p53 is associated to higher local recurrences. In the recent years, molecular markers became available to give us precious information. What is emerging is that molecular characteristics associated with invasiveness are already present in the more aggressive subgroup of DCIS lesions [61–63]. Low-grade hormone receptor-positive DCIS grows very slowly and is the precursor of low-grade invasive breast cancer. A significant proportion of the DCIS lesions will never lead to invasive cancer. But we still don't know which DCIS lesions will progress or not with the result that every DCIS is now treated similarly to the invasive ones. Particularly with regard to the axillary staging, the risk is an overtreatment [61]. With the fear of an underestimation of the invasiveness in the preoperative diagnosis, the result is a trend in performing the SLNB much more frequently than necessary.

Another important element to be considered is the overestimation of the risk of a weak migration of the tracer due to the previous surgery, in cases of a second operation for SLNB. At this regard, in the new era of decreased importance of axillary staging as a determinant of prognosis and adjuvant therapies, we can also imagine that in absence of the tracer migration, it would be possible to leave out the axillary clearance, especially in case of DCIS.

Finally a comment is needed for the growing importance of the quality control on the clinical pathways performed by scientific societies and public institutions through clinical and process indicators. These instruments represent an important tool of improvement for the entire team, being them able to detect the gaps in the clinical pathways, the steps that require improvements and eventually the incorrect habits of the surgeons themselves. At the same time it's desirable that the choice of the indicators is made with particular care, avoiding that they can cause

opportunistic conducts due simply to the fear of not complying to the indicators themselves. With regard to our topic, there are some indicators about the rate of early reoperation: according to that, the surgeons could be wrongly led to perform SLNB very frequently in DCIS patients [12, 64].

The pathological status of lymph nodes is still an important prognostic factor: identification of axillary metastasis indicates a poorer prognosis and often prompts an indication for chemotherapy and radiation therapy. What is clear, however, is that the most important factor to be considered in establishing the prognosis of any breast cancer and the adjuvant treatment today is the tumour biology: luminal, HER-2 or triple negative. An aggressive pattern can explain very well the bad prognosis of a little T1 N0 breast cancer, while a luminal A 25 mm cancer with one or two positive nodes can be associated to a very good behaviour even avoiding chemotherapy.

In this new approach to breast cancer, the significance of the axillary staging for DCIS is surely decreasing, and surgeons should remember it when they are facing the decision-making process.

In summary, at present time, based on currently available data, we can affirm that SLNB is recommended for patients undergoing mastectomy for DCIS; in case of breast-conserving surgery, SLNB should be considered on a case-by-case basis only for DCIS at high risk of association to invasive cancer or for large tumours, avoiding the axillary evaluation in all the other low-risk cases.

References

1. Groen EJ, Elshof LE, Visser LL, Rutgers EJ, Winter-Warnars HA, Lips EH, Wesseling J. Finding the balance between over- and under-treatment of ductal carcinoma in situ (DCIS). *Breast*. 2017;31:274–83. doi:[10.1016/j.breast.2016.09.001](https://doi.org/10.1016/j.breast.2016.09.001).
2. Narod SA, Iqbal J, Giannakeas V, Sopik V, Sun P. Breast cancer mortality after a diagnosis of ductal carcinoma in situ. *JAMA Oncol*. 2015;1(7):888–96. doi:[10.1001/jamaoncol.2015.2510](https://doi.org/10.1001/jamaoncol.2015.2510).
3. Wapnir IL, Dignam JJ, Fisher B, Mamounas EP, Anderson SJ, Julian TB, Land SR, Margolese RG, Swain SM, Costantino JP, Wolmark N. Long-term outcomes of invasive ipsilateral breast tumor recurrences after lumpectomy in NSABP B-17 and B-24 randomized clinical trials for DCIS. *J Natl Cancer Inst*. 2011;103(6):478–88. doi:[10.1093/jnci/djr027](https://doi.org/10.1093/jnci/djr027).
4. Shapiro-Wright HM, Julian TB. Sentinel lymph node biopsy and management of the axilla in ductal carcinoma in situ. *J Natl Cancer Inst Monogr*. 2010;2010(41):145–9. doi:[10.1093/jncimonographs/lgq026](https://doi.org/10.1093/jncimonographs/lgq026). Review
5. Jackman RJ, Nowels KW, Rodriguez-Soto J, et al. Stereotactic, automated, large core needle biopsy of nonpalpable breast lesions: false-negative and histologic underestimation rates after long-term follow-up. *Radiology*. 1999;210(3):799–805.
6. Lee CH, Carter D, Philpotts LS, et al. Ductal carcinoma in situ diagnosed with stereotactic core needle biopsy: can invasion be predicted? *Radiology*. 2000;217(2):466–70.
7. Pandelidis S, Heilman D, Jones D, et al. Accuracy of 11 gauge vacuum-assisted core biopsy of mammographic breast lesions. *Ann Surg Oncol*. 2003;20(1):43–7.
8. Wilkie C, White L, Dupont E, et al. An update of sentinel lymph node mapping in patients with ductal carcinoma in situ. *Am J Surg*. 2005;190(4):563–6.
9. Goyal A, Douglas-Jones A, Monypenny I, et al. Is there a role of sentinel lymph node biopsy in ductal carcinoma in situ? Analysis of 587 cases. *Breast Cancer Res Treat*. 2006;98(3):311–4.

10. Dillon MF, McDermott EW, Quinn CM, et al. Predictors of invasive disease in breast cancer when core needle biopsy demonstrates DCIS only. *J Surg Oncol.* 2006;93(7):559–63.
11. Silverstein MJ, Rosser RJ, Gierson ED, Waisman JR, Gamagami P, Hoffman RS, Fingerhut AG, Lewinsky BS, Colburn W, Handel N. Axillary lymph node dissection for intraductal breast carcinoma--is it indicated? *Cancer.* 1987;59(10):1819–24.
12. Del Turco MR, Ponti A, Bick U, Biganzoli L, Cserni G, Cutuli B, Decker T, Dietel M, Gentilini O, Kuehn T, Mano MP, Mantellini P, Marotti L, Poortmans P, Rank F, Roe H, Scaffidi E, van der Hage JA, Viale G, Wells C, Welnicka-Jaskiewicz M, Wengstöm Y, Cataliotti L. Quality indicators in breast cancer care. *Eur J Cancer.* 2010;46(13):2344–56. doi:[10.1016/j.ejca.2010.06.119](https://doi.org/10.1016/j.ejca.2010.06.119).
13. Fisher B, Dignam J, Wolmark N, Mamounas E, Costantino J, Poller W, Fisher ER, Wickerham DL, Deutsch M, Margolese R, Dimitrov N, Kavanah M. Lumpectomy and radiation therapy for the treatment of intraductal breast cancer: findings from National Surgical Adjuvant Breast and bowel project B-17. *J Clin Oncol.* 1998;16(2):441–52.
14. Winchester DP, Menck HR, Osteen RT, Kraybill W. Treatment trends for ductal carcinoma in situ of the breast. *Ann Surg Oncol.* 1995;2(3):207–13.
15. Silverstein MJ, Waisman JR, Gamagami P, et al. Intraductal carcinoma of the breast (208 cases). Clinical factors influencing treatment choice. *Cancer.* 1990;66(1):102–8.
16. Kinne DW, Perrek JA, Osborne MP, et al. Breast carcinoma in situ. *Arch Surg.* 1989;124(1):33.
17. Intra M, Veronesi P, Mazzaro G, et al. Axillary sentinel lymph node biopsy in patients with pure ductal carcinoma in situ of the breast. *Arch Surg.* 2003;138(3):309.
18. Boler DE, Cabioglu N, Ince U, Esen G, Uras C. Sentinel lymph node biopsy in pure DCIS: is it necessary? *ISRN Surg.* 2012;2012:394095. doi:[10.5402/2012/394095](https://doi.org/10.5402/2012/394095).
19. Silverstein MJ, Skinner KA, Lomis TJ. Predicting axillary nodal positivity in 2282 patients with breast carcinoma. *World J Surg.* 2001;25(6):767–72.
20. Park HS, Park S, Cho J, Park JM, Kim SI, Park BW. Risk predictors of underestimation and the need for sentinel node biopsy in patients diagnosed with ductal carcinoma in situ by preoperative needle biopsy. *J Surg Oncol.* 2013;107(4):388–92. doi:[10.1002/jso.23273](https://doi.org/10.1002/jso.23273).
21. Sakr R, Bezu C, Raoust I, et al. The sentinel lymph node procedure for patients with preoperative diagnosis of ductal carcinoma in situ: risk factors for unsuspected invasive disease and for metastatic sentinel lymph nodes. *Int J Clin Pract.* 2008;62(11):1730–5.
22. Hoorntje LE, Schipper MEI, Peeters PHM, Bellot F, Storm RK, Borel Rinkes IHM. The finding of invasive cancer after a preoperative diagnosis of ductal carcinoma-in-situ: causes of ductal carcinoma-in-situ underestimates with stereotactic 14-gauge needle biopsy. *Ann Surg Oncol.* 2003;10(7):748–53.
23. Dillon MF, Quinn CM, McDermott EW, O'Doherty A, O'Higgins N, Hill ADK. Diagnostic accuracy of core biopsy for ductal carcinoma in situ and its implications for surgical practice. *J Clin Pathol.* 2006;59(7):740–3.
24. Ansari B, Ogston SA, Purdie CA, Adamson DJ, Brown DC, Thompson AM. Meta-analysis of sentinel node biopsy in ductal carcinoma in situ of the breast. *Br J Surg.* 2008;95(5):547–54.
25. Yen TW, Hunt KK, Ross MI, et al. Predictors of invasive breast cancer in patients with an initial diagnosis of ductal carcinoma in situ: a guide to selective use of sentinel lymph node biopsy in management of ductal carcinoma in situ. *J Am Coll Surg.* 2005;200(4):516–26.
26. Guillot E, Vaysse C, Goetgeluck J, Falcou MC, Couturaud B, Fitoussi A, Fourchette V, Laki F, Malhaire C, Sigal-Zafrani B, Sastre-Garau X, Bollet MA, Mosseri V, Rey F. Extensive pure ductal carcinoma in situ of the breast: identification of predictors of associated infiltrating carcinoma and lymph node metastasis before immediate reconstructive surgery. *Breast.* 2014;23(2):97–103. doi:[10.1016/j.breast.2013.12.002](https://doi.org/10.1016/j.breast.2013.12.002).
27. Veronesi U, Luini A, Botteri E, Zurrada S, Monti S, Galimberti V, et al. Nonpalpable breast carcinomas: long-term evaluation of 1,258 cases. *Oncologist.* 2010;15:1248–52.
28. Yi M, Krishnamurthy S, Kuerer HM, Meric-Bernstam F, Bedrosian I, Ross MI, et al. Role of primary tumor characteristics in predicting positive sentinel lymph nodes in patients with ductal carcinoma in situ or microinvasive breast cancer. *Am J Surg.* 2008;196:81–7.
29. Lagios MD, Margolin FR, Westdahl PR, Rose MR. Mammographically detected duct carcinoma in situ. Frequency of local recurrence following tylectomy and prognostic effect of nuclear grade on local recurrence. *Cancer.* 1989;63:618–24.

30. Virnig BA, Tuttle TM, Shamliyan T, Kane RL. Ductal carcinoma in situ of the breast: a systematic review of incidence, treatment, and outcomes. *J Natl Cancer Inst.* 2010;102(3):170–8. doi:[10.1093/jnci/djp482](https://doi.org/10.1093/jnci/djp482). Review
31. Tan JC, McCready DR, Easson AM, et al. Role of sentinel lymph node biopsy in ductal carcinoma-in-situ treated by mastectomy. *Ann Surg Oncol.* 2007;14(2):638–45.
32. Dominguez FJ, Golshan M, Black DM, et al. Sentinel node biopsy is important in mastectomy for ductal carcinoma in situ. *Ann Surg Oncol.* 2007;15(1):268–73.
33. Lara JF, Young SM, Velilla RE, et al. The relevance of occult axillary micrometastasis in ductal carcinoma in situ: a clinicopathologic study with long-term follow up. *Cancer.* 2003;98(10):2105–13.
34. Giuliano AE, McCall L, Beitsch P, Whitworth PW, Blumencranz P, Leitch AM, Saha S, Hunt KK, Morrow M, Ballman K. Locoregional recurrence after sentinel lymph node dissection with or without axillary dissection in patients with sentinel lymph node metastases: the American College of Surgeons Oncology group Z0011 randomized trial. *Ann Surg.* 2010;252(3):426–432., discussion 432–423. doi:[10.1097/SLA.0b013e3181f08f32](https://doi.org/10.1097/SLA.0b013e3181f08f32).
35. Galimberti V, Cole BF, Zurrada S, Viale G, Luini A, Veronesi P, Baratella P, Chifu C, Sargenti M, Intra M, Gentilini O, Mastropasqua MG, Mazzarol G, Massarut S, Garbay JR, Zgajnar J, Galati H, Recalcati A, Littlejohn D, Bamert M, Colleoni M, Price KN, Regan MM, Goldhirsch A, Coates AS, Gelber RD, Veronesi U, International Breast Cancer Study Group Trial 2301 Investigators. Axillary dissection versus no axillary dissection in patients with sentinel-node micrometastases (IBCSG 23-01): a phase 3 randomised controlled trial. *Lancet Oncol.* 2013;14(4):297–305. doi:[10.1016/S1470-2045\(13\)70035-4](https://doi.org/10.1016/S1470-2045(13)70035-4).
36. Gentilini O, Veronesi U. Abandoning sentinel lymph node biopsy in early breast cancer? A new trial in progress at the European Institute of Oncology of Milan (SOUND: sentinel node vs observation after axillary UltraSOUND). *Breast.* 2012;21(5):678–81. doi:[10.1016/j.breast.2012.06.013](https://doi.org/10.1016/j.breast.2012.06.013).
37. Broekhuizen LN, Wijsman JH, Peterse JL, Rutgers EJT. The incidence and significance of micrometastases in lymph nodes of patients with ductal carcinoma in situ and T1a carcinoma of the breast. *Eur J Surg Oncol.* 2006;32:502–6. doi:[10.1016/j.ejso.2006.02.006](https://doi.org/10.1016/j.ejso.2006.02.006).
38. Francis AM, Haugen CE, Grimes LM, Crow JR, Yi M, Mittendorf EA, et al. Is sentinel lymph node dissection warranted for patients with a diagnosis of ductal carcinoma in situ? *Ann Surg Oncol.* 2015;22:4270–9. doi:[10.1245/s10434-015-4547-7](https://doi.org/10.1245/s10434-015-4547-7).
39. van Roozendaal LM, Goorts B, Klinkert M, Keymeulen KBMI, De Vries B, Strobbe LJA, et al. Sentinel lymph node biopsy can be omitted in DCIS patients treated with breast conserving therapy. *Breast Cancer Res Treat.* 2016;156:517–25. doi:[10.1007/s10549-016-3783-2](https://doi.org/10.1007/s10549-016-3783-2).
40. Broekhuizen LN, Wijsman JH, Peterse JL, Rutgers EJ. The incidence and significance of micrometastases in lymph nodes of patients with ductal carcinoma in situ and T1a carcinoma of the breast. *Eur J Surg Oncol.* 2006;32(5):502–6.
41. Bleiweiss IJ, Nagi CS, Jaffer S. Axillary sentinel lymph nodes can be falsely positive due to iatrogenic displacement and transport of benign epithelial cells in patients with breast carcinoma. *J Clin Oncol.* 2006;24(13):2013–8.
42. Carter BA, Jensen RA, Simpson JF, Page DL. Benign transport of breast epithelium into axillary lymph nodes after biopsy. *Am J Clin Pathol.* 2000;113(2):259–65.
43. Murphy CD, Jones JL, Javid SH, et al. Do sentinel node micrometastases predict recurrence risk in ductal carcinoma in situ and ductal carcinoma in situ with microinvasion? *Am J Surg.* 2008;196(4):566–8.
44. Smith BL. Clinical applications of breast pathology: management of in situ breast carcinomas and sentinel node biopsy issues. *Mod Pathol.* 2010;23(Suppl 2):S33–5. doi:[10.1038/mod-pathol.2010.53](https://doi.org/10.1038/mod-pathol.2010.53). Review
45. Moore KH, Sweeney KJ, Wilson ME, et al. Outcomes for women with ductal carcinoma-in-situ and a positive sentinel node: a multi-institutional audit. *Ann Surg Oncol.* 2007;14:2911–7.
46. Tunon-de-Lara C, Chauvet MP, Baranzelli MC, Baron M, Piquenot J, Le-Bouédec G, Penault-Llorca F, Garbay JR, Blanchot J, Mollard J, Maisongrosse V, Mathoulin-Pélissier S, MacGrogan G. The role of sentinel lymph node biopsy and factors associated with invasion in

- extensive DCIS of the breast treated by mastectomy: the Cinnamome prospective multicenter study. *Ann Surg Oncol*. 2015;22(12):3853–60. doi:10.1245/s10434-015-4476-5.
47. Tada K, Ogiya A, Kimura K, et al. Ductal carcinoma in situ and sentinel lymph node metastasis in breast cancer. *World J Surg Oncol*. 2010;8:6. doi:10.1186/1477-7819-8-6.
 48. Han JS, Molberg KH, Sarode V. Predictors of invasion and axillary lymph node metastasis in patients with a core biopsy diagnosis of ductal carcinoma in situ: an analysis of 255 cases. *Breast J*. 2011;17:223–9. doi:10.1111/j.1524-4741.2011.01069.x.
 49. Moran CJ, Kell MR, Flanagan FL, et al. Role of sentinel lymph node biopsy in high-risk ductal carcinoma in situ patients. *Am J Surg*. 2007;194:172–5. doi:10.1016/j.amjsurg.2006.11.027.
 50. Coromilas EJ, Wright JD, Huang Y, Feldman S, Neugut AI, Chen L, Hershman DL. The influence of hospital and surgeon factors on the prevalence of axillary lymph node evaluation in ductal carcinoma in situ. *JAMA Oncol*. 2015;1(3):323–32. doi:10.1001/jamaoncol.2015.0389.
 51. www.cancernetwork.com
 52. Lyman GH, Temin S, Edge SB, Newman LA, Turner RR, Weaver DL, Benson AB III, Bosserman LD, Burstein HJ, Cody H III, Hayman J, Perkins CL, Podoloff DA, Giuliano AE, American Society of Clinical Oncology Clinical Practice. Sentinel lymph node biopsy for patients with early-stage breast cancer: American Society of Clinical Oncology clinical practice guideline update. *J Clin Oncol*. 2014;32(13):1365–83. doi:10.1200/JCO.2013.54.1177.
 53. Lyman GH, Somerfield MR, Giuliano AE. Sentinel lymph node biopsy for patients with early-stage breast cancer: 2016 American Society of Clinical Oncology Clinical Practice Guideline Update Summary. *J Oncol Pract*. 2017;13(3):196–198. doi: 10.1200/JOP.2016.019992. Epub 2017 Jan 24.
 54. <http://www.oncoline.nl/uploaded/docs/mammacarcinoom/Dutch%20Breast%20Cancer%20Guideline%202012.pdf>
 55. <https://www.nice.org.uk/guidance/cg80/chapter/1-guidance#surgery-to-the-axilla>
 56. https://www.nccn.org/professionals/physician_gls/f_guidelines.asp
 57. Coromilas EJ, Wright JD, Huang Y, Feldman S, Neugut AI, Hillyer GC, Chen L, Hershman DL. Axillary evaluation and lymphedema in women with ductal carcinoma in situ. *Breast Cancer Res Treat*. 2016;158(2):373–84. doi:10.1007/s10549-016-3890-0.
 58. Vugts G, Maaskant-Braat AJ, Voogd AC, van Riet YE, Luiten EJ, Rutgers EJ, Rutten HJ, Roumen RM, Nieuwenhuijzen GA. Repeat sentinel node biopsy should be considered in patients with locally recurrent breast cancer. *Breast Cancer Res Treat*. 2015;153(3):549–56. doi:10.1007/s10549-015-3571-4.
 59. Vugts G, Maaskant-Braat AJ, Voogd AC, van Riet YE, Roumen RM, Luiten EJ, Rutgers EJ, Wyndaele D, Rutten HJ, Nieuwenhuijzen GA. Improving the success rate of repeat sentinel node biopsy in recurrent breast cancer. *Ann Surg Oncol*. 2015;22(Suppl 3):S529–35. doi:10.1245/s10434-01-4787-6.
 60. Folli S, Falco G, Mingozzi M, Buggi F, Curcio A, Ferrari G, Taffurelli M, Regolo L, Nanni O. Repeat sentinel lymph node biopsy in patients with ipsilateral recurrent breast cancer after breast-conserving therapy and negative sentinel lymph node biopsy: a prospective study. *Minerva Chir*. 2016;71(2):73–9.
 61. Abba MC, Gong T, Lu Y, Lee J, Zhong Y, Lacunza E, et al. A molecular portrait of high-grade ductal carcinoma in situ. *Cancer Res*. 2015;75:3980–90.
 62. Ma X-J, Salunga R, Tuggle JT, Gaudet J, Enright E, McQuary P, et al. Gene expression profiles of human breast cancer progression. *Proc Natl Acad Sci*. 2003;100:5974–9.
 63. Vincent-Salomon A, Lucchesi C, Gruel N, Raynal V, Pierron G, Goudefroye R, et al. Integrated genomic and transcriptomic analysis of ductal carcinoma in situ of the breast. *Clin Cancer Res*. 2008;14:1956–65.
 64. http://www.senonetwork.it/app/public/files/download/Indicatori%20di%20qualit%C3%A0%20per%20la%20cura%20del%20carcinoma%20mammario%20nelle%20B.U._11.2013_6k3aslhb.pdf

Francesca Cucciarelli

10.1 Introduction

Ductal carcinoma in situ (DCIS) of the breast has rapidly grown in number of cases over the past several decades, due to increases in mammographic screening. It currently represents up to 20% of newly diagnosed breast cancer [1]. DCIS is a biologically heterogeneous group of noninvasive lesions in the breast, characterized by proliferative malignant ductal cells limited to existing ductal units, without invasion through the basement membrane. In the last few years, the increasing occurrence of very small, radiologically detected subclinical lesions has led some authors to consider most DCIS as a possibly indolent disease and consequently propose a less intensive treatment. However, DCIS has a potential for progression to invasive carcinoma, usually within the first 10 years after initial diagnosis, which characterizes DCIS as a preinvasive or precursor lesion and as a continuum along the mammary neoplastic transformation process [2].

Historically mastectomy was considered the therapy of choice, since having only 1–2% of local recurrence and associated with a survival rate of 98% [3, 4], but it is currently considered as overtreatment in many cases, especially in the presence of small, non-palpable lesions. Nowadays, breast conserving therapy, consisting of breast-conserving surgery with adjuvant radiation therapy, is considered the standard of care with regard to local management for eligible patients.

No randomized trials directly comparing mastectomy versus breast-conserving surgery with radiation therapy have been performed in patients with DCIS. Therefore, the efficacy of breast-conserving therapy is often extrapolated from randomized trials in patients with early-stage invasive cancers, which have confirmed that this treatment is not associated with inferior outcomes and provides equivalent survival to mastectomy.

F. Cucciarelli

Radiotherapy Institute, Department of Internal Medicine, Ospedali Riuniti Umberto I, G.M.

Lancisi, G. Salesi, Ancona, Italy

e-mail: francesca.cucciarelli@ospedaliriuniti.marche.it

Four randomized trials investigated the role of the addition of postoperative radiation therapy after breast-conserving surgery and showed a significantly reduced risk for local recurrences when adjuvant radiotherapy was administered. These four randomized trials are the NSABP B-17 trial, the EORTC 10853 trial, the SweDCIS trial, and the UK/ANZ DCIS trial. The NSABP B-17 trial [5] enrolled 818 patients with localized DCIS treated by lumpectomy that achieved tumor-free margins between October 1985 and December 1990. These patients were randomly assigned to the lumpectomy-only group or to the lumpectomy followed by radiotherapy group. Endpoints of this study included invasive ipsilateral breast tumor recurrence, DCIS-breast tumor recurrence, contralateral breast cancers, overall survival, breast cancer-specific survival, and survival after invasive ipsilateral breast tumor recurrence. Median follow-up was 207 months. Radiation therapy reduced invasive ipsilateral breast tumor recurrence by 52% in the lumpectomy followed by radiotherapy group compared to the lumpectomy-only group, with an hazard ratio of risk = 0.48, 95% confidence interval = 0.33–0.69 with $P < 0.001$. The 15-year cumulative incidence of invasive ipsilateral breast tumor recurrence was 19.4% for the lumpectomy-only group and 8.9% for the lumpectomy followed by radiotherapy group. The 15-year cumulative incidence of all contralateral breast cancers was 10.3% for the lumpectomy-only group and 10.2% for the lumpectomy followed by radiotherapy group. The invasive ipsilateral breast tumor recurrence was associated with increased mortality risk (hazard ratio of death = 1.75, 95% confidence interval = 1.45–2.96 with $P < 0.001$), whereas recurrence of DCIS was not. Twenty-two of 39 deaths after invasive ipsilateral breast tumor recurrence were attributed to breast cancer. Among all patients, the 15-year cumulative incidence of breast cancer death was 3.1% for the lumpectomy-only group and 4.7% for the lumpectomy followed by radiotherapy group.

In the EORTC 10853 trial [6], 1010 patients with DCIS treated with breast-conserving surgery were randomly assigned to adjuvant radiotherapy (507 patients) or no further treatment (503 patients).

Twenty-six patients (5%) randomly assigned to the radiotherapy group received a boost. The median follow-up time was 15.8 years. Radiotherapy reduced the risk of any local recurrence by 48%, with a hazard ratio of 0.52 and 95% confidence interval from 0.40 to 0.68, with $P = 0.001$. The 15-year local recurrence-free rate was 69% in the group of patients who underwent a local excision only, compared to 82% in the radiotherapy group, while the 15-year invasive local recurrence-free rate was 84% in the local excision-only group and 90% in the patients assigned to adjuvant radiotherapy, with a hazard ratio of 0.61 and 95% confidence interval from 0.42 to 0.87. An overall salvage mastectomy rate after local recurrence was lower in the radiotherapy group (13%) rather than in the local excision-only group (19%).

Almost one in three nonirradiated women developed a local recurrence after local excision for DCIS, and radiotherapy reduced this risk by a factor of two.

The differences in local recurrence in both arms did not lead to differences in breast cancer-specific survival or overall survival. Patients with invasive local recurrence had a significantly worse breast cancer-specific survival and overall survival compared with those who did not experience recurrence, but the long-term prognosis was good and independent of the given treatment.

In the SweDCIS trial [7], 1067 women in Sweden from 1987 to 1999 were randomly assigned to postoperative radiotherapy or control. The main outcome was new ipsilateral breast cancer events, and distant metastasis-free survival analyzed according to intention to treat. In this study, 64 ipsilateral breast events occurred in the patients who underwent a radiotherapy treatment and 141 in the control group, corresponding to a risk reduction of 16.0 percentage points at 10 years and a relative risk of 0.40. In the radiotherapy group 59.4% and in the control group 45.4% of the ipsilateral events were invasive. The authors showed that radiotherapy reduced the risk of invasive and in situ events similarly. A total of 18 events of metastatic breast disease and breast cancer deaths occurred in the radiotherapy group and a total of 15 in the control group, but there was no statistically significant difference in distant metastasis-free survival. In this study, radiation therapy has proven more effective in women older than 60, compared to women younger than 50. The age effect was not confounded by focality, lesion size, completeness of excision, or detection mode. However the data regarding the effect of age come from a subgroup analysis and should be considered with caution.

In the UK/ANZ DCIS trial [8], 1701 patients, of which 1694 eligible for analysis, were randomized to receive radiotherapy, tamoxifen, or both: 912 patients chose to enter into two by two randomization, to radiotherapy and tamoxifen (242 patients) and to tamoxifen only (224 patients) or to radiotherapy only (220 patients) and to not treatment (226 patients); 782 chose to enter into randomization to one of the treatment; 664 chose radiotherapy and were only randomized to receive tamoxifen or not; and 118 chose tamoxifen and were only randomized to receive radiotherapy or not.

The radiotherapy dose was 50 Gy in 25 fractions over 5 weeks; the boost to the surgical bed was not administered; tamoxifen was prescribed at a dose of 20 mg daily for 5 years. In the patients randomly assigned to tamoxifen, the authors found an absolute 10-year reduction of 3.9% for all ipsilateral events and of 2.3% in all contralateral events, with an absolute 10-year reduction of 6.5% for all new breast events. Patients randomized to radiotherapy had fewer new breast events, with an absolute reduction of 12.6%; radiotherapy significantly reduced all ipsilateral events, whereas no effect was reported in relation to contralateral events. Furthermore there was no significant difference in new breast events between patients randomly assigned to radiotherapy and tamoxifen and those randomized to radiotherapy alone; instead the differences are significant among patients randomized to receive radiotherapy plus tamoxifen compared to those randomized to receive tamoxifen only.

Within the four prospective randomized studies, the greatest benefit was observed in patients with high-grade lesions, with positive margins, and in the elderly (age > 50 years); instead a statistically significant difference did not emerge in the incidence of distant metastases and overall survival. A significant increase in mortality from cardiovascular diseases, in the group of patients undergoing postoperative radiotherapy, was not found, except in the UK/ANZ trial, in which, however, the number of cases was very limited.

Also the results of three meta-analysis showed a greater local control when the conservative surgery was followed by radiotherapy. From the meta-analysis of

Viani et al. [9], it emerged that the addition of radiation therapy to lumpectomy results in approximately 60% reduction in breast cancer recurrence, in the absence of benefit for survival or distant metastases compared to excision alone. Patients with high-grade DCIS lesions and positive margins benefited most from the addition of radiotherapy. In this meta-analysis it was reported higher rates of contralateral breast cancer in the group of patients undergoing a postoperative radiotherapy; in the subsequent two meta-analyses in which the four clinical trials were examined after a longer follow-up period, the differences were minimal and not statistically significant.

The Cochrane Database of Systematic Reviews [10] showed a 50% reduction in local recurrence in DCIS patients with postoperative radiotherapy with similar rates of reduction noted for invasive and noninvasive recurrences.

The Early Breast Cancer Trialists' Collaborative Group (EBCTCG) meta-analysis confirmed the reduction of the rate of ipsilateral breast tumor recurrence compared to surgical resection only (12.9% versus 28.1%), with an absolute reduction in local recurrence at 10 years of 15.2% with the addition of radiotherapy. The impact of postoperative radiation therapy compared to surgery alone was similar in terms of both invasive and in situ local recurrence: 6.9% versus 15.4% and 6.5% versus 14.9%, respectively. The benefit of the radiation therapy was independent of diagnostic modality (clinical or radiological), age, type of surgery (lumpectomy or quadrantectomy), nuclear grade, the presence of comedo necrosis, architectural subtype, tumor size, margin status (free, close or unknown), and tamoxifen administration [11].

10.2 Prognostic Factors

Risk factors for local recurrences can be stratified into three groups: clinical factors, histopathological factors, and treatment-related factors.

The clinical risk factors are represented by the clinical presentation and patient age. Diagnostic modalities and mammographic characteristics are very important because symptomatic DCIS patients, with, for example, skin retraction and sero-hemorrhagic nipple discharge, have a higher local recurrence risk than those for whom the disease was radiologically diagnosed.

In the EORTC 10853 trial [6], the local recurrence relative risk was 1.48 for DCIS detected by clinical examination compared to mammography-detected lesions, after both local excision (27% versus 16%) and local excision followed by postoperative radiation therapy (17% versus 11%). Finally, an accurate analysis of microcalcification subtype in the SweDCIS trial showed that "crushed stone and casting type" were associated with a higher histopathological grade and more extensive disease, and the relative risk of local recurrence for the casting type was 2.1 [7].

The young age, generally considered under 40 or 50 years old, is one of the most important parameters related to the incidence of local recurrence, both in the clinically palpable DCIS cases and in the hidden forms, diagnosed with mammography. This leads some centers to have a more aggressive approach in young women,

including a higher mastectomy rate and a more frequent use of a boost after whole-breast irradiation in order to obtain a better local control.

In the SweDCIS trial, the authors found an interaction by age and effect of radiotherapy that indicated a lower effect of radiotherapy in the young patients. The cumulative incidence in the radiotherapy arm was 20% in the youngest age group, falling to 8% among those age 65 and older. There was thus a modest absolute risk reduction in younger women (6%) and a substantial reduction (18%) in older women [7].

In the NSABP B-17 trial, women younger than 45 years showed a 2.1-fold increased risk of invasive ipsilateral breast tumor recurrence compared with women aged 65 years and older at diagnosis; women aged 45–64 years also showed an increased risk of invasive ipsilateral breast tumor recurrence relative to women aged 65 years and older [5].

The histopathological factors are tumor size, nuclear grade, the state, and the magnitude of the margins.

In the literature, the DCIS size is characterized by a wide variation in assessing, recording, and reporting. In the EORTC 10853 trial [6], only 25% of the lesions were measurable with precision, with clear dimensions expressed in mm. In the survey of Cutuli et al., indeed, the DCIS size was identified in 97% of the patients: lesions <10 mm, 10–20 mm, and >20 mm were found in 41%, 27%, and 32% of the cases, respectively [12].

In general the correlation between DCIS size and local recurrence still remains poorly documented. However, a recent report from Alvarado et al. [13] showed a significant influence of tumor size on local relapse, with 5-year recurrence rates of 5.6% versus 2.2% for lesions over and under 15 mm, respectively.

In a Chinese observational study of tumor subtype, treatment and outcome of breast carcinoma in situ, the authors showed a decreased overall survival only in patients with a tumor size >50 mm [14].

Nuclear grade was analyzed in many cohort of patients, and it is well known that about one third of DCIS appears with complex histologic patterns, including the presence of varying nuclear grades within the same lesion. High nuclear grade has always been correlated with an increased rate of local recurrence.

In the EORTC 10853 trial [6], the 10-year local recurrence rates were 18%, 34%, and 35% for grade low, intermediate, and high, respectively, in the surgery-alone group and 9%, 23%, and 19% in the surgery with the addition of radiation therapy group. Also in the UK/ANZ DCIS trial, the high grade, in addition to large size and young age, was significant predictor to a high recurrence rate [8].

The Van Nuys team reported an increase of a 12-year local recurrence rate correlated with the nuclear grade: 13%, 23%, and 45% for low, intermediate, and high grade DCIS, respectively [15].

Many studies have shown a lower incidence of local recurrence in the presence of histologically negative margins, both after radiation therapy, than in patients treated with conservative surgery alone; however, the optimal margin distance remains a topic of debate. The definition of a negative margin varies widely from one study to another (1, 2, 3, 5, or 10 mm or untouched ink); also many reports on

margin status are retrospective and lack a standardized assessment of margins, in terms of orientating, inking, and specimen sectioning. Furthermore the rate of close or uncertain margins widely varies among the series [2].

In the Dunne et al.'s meta-analysis of 22 studies, both retrospective and prospective randomized, including only patients treated with conservative surgery and radiotherapy, it has been a statistically significant reduction in the risk of local recurrence in the presence of negative margins ≥ 2 mm [16].

In the Wang et al.'s meta-analysis of 21 studies, both retrospective and prospective randomized, including patients treated with only conservative surgery or conservative surgery plus adjuvant radiotherapy, best results were seen with free margins ≥ 10 mm [17].

However, the advantage achieved with margins greater than 2 mm appears to be less pronounced in the subgroup of patients undergoing radiotherapy after conservative surgery. Therefore currently there is a broad consensus that margins ≥ 2 mm are adequate, when conserving surgery followed by radiotherapy.

10.3 Identification of Patients at Low Risk of Recurrence

Many authors have tried to identify a subgroup of patients with a presumably low risk of recurrence for whom radiotherapy could safely be omitted.

In these last years, many retrospective and prospective studies have evaluated outcome of DCIS patients with breast conservative surgery alone, without postoperative radiotherapy.

In a pooled analysis of the French Regional Cancer Center, 705 patients with breast DCIS were treated with excision alone between 1985 and 1995. The ipsilateral breast tumor recurrence in these patients was 32.4% for conserving surgery alone compared to 12.6% with the addition of radiation therapy [18]. Also in a review of Rakovitch et al. emerged a higher rate of local recurrence without radiotherapy: 19% versus 13% in over 3500 patients evaluated [19].

The prospective phase II trial of the Dana-Farber Cancer Institute [20] enrolled 158 patients affected by low-/intermediate-grade DCIS with tumor size ≤ 2.5 cm and surgical margins >1 cm. The use of tamoxifen was not permitted. The study was closed early due to a higher rate of local recurrence, 12% ipsilateral tumor recurrence at 5 years, with a local recurrence rate of 2.4% per patient year. In a subsequent publication, with a further follow-up, the local recurrence rates were 13% and 15.6% after 8 and 10 years, respectively.

The Eastern Cooperative Oncology Group (ECOG) E-5194 trial enrolled 670 patients with low/intermediate DCIS measuring ≤ 2.5 cm or high-grade DCIS with tumor size ≤ 1 cm and ≥ 3 mm or wider surgical margins in all cases. Tamoxifen was administered only in 30% of cases. The results of this trial showed that the rate of ipsilateral breast recurrence was 6.1% for low-/intermediate-grade DCIS and 15.3% for high-grade DCIS at 5 years and 15.4% for low-/intermediate-grade DCIS and 15.1% for high-grade DCIS at 10 years. The risks of developing an ipsilateral breast event and an invasive ipsilateral breast event increased over time through 12 years

of follow-up. The 12-year rates of developing an ipsilateral breast event were 14.4% for cohort 1 and 24.6% for cohort 2, and the 12-year rates of developing an invasive ipsilateral breast event were 7.5% and 13.4%, respectively. No clearly defined plateau was observed for either cohort of patients [21, 22].

Motwani et al. [23] conducted an analysis utilizing the same criteria of the ECOG study and comparing outcomes between patients who received radiotherapy in your institution (single-institution retrospective cohort) and patients treated with excision alone in the ECOG study (ECOG cohort). In all cases radiotherapy reduced the rate of local recurrence by more than 70% in patients with DCIS who met the criteria of ECOG study: the 5-year and 7-year ipsilateral breast tumor recurrence for the low-/intermediate-DCIS cohort in this study was 1.5% and 4.4% compared with 6.1% and 10.5% in ECOG study, respectively. The 5-year and 7-year ipsilateral breast tumor recurrence for the high-grade DCIS cohort was 2.0% and 2.0% in this study compared with 15.3% and 18% in ECOG study, respectively.

Also one randomized trial has been conducted to evaluate the efficacy of omitting adjuvant radiotherapy after breast conservative surgery in low-risk patients, who are still very much selected. The RTOG 9804 trial [24] was a prospective randomized phase III study in which patients with mammographically detected low- or intermediate-grade DCIS, measuring less than 2.5 cm and surgical margins ≥ 3 mm, were randomized to receive conserving surgery alone (observational arm) or conserving surgery with the addition of adjuvant whole-breast irradiation (radiotherapy arm). Also in this good-risk subset of patients, radiotherapy was associated with a significant reduction in the rate of ipsilateral breast tumor recurrence: at 7 years the ipsilateral local failure was 0.9% in the radiotherapy arm compared to 6.7% in the observational arm. Furthermore two third of recurrences in the observation arm were true recurrence, occurred in the same quadrant as the initial tumor, whereas none of the recurrences in the radiotherapy arm were true recurrences.

Therefore it can be concluded that randomized trials and analyses have failed so far to identify a low-risk subset of patients that did not benefit from postoperative radiation therapy with respect to local control, partly because there exists no standardized or universally accepted pathologic definition of low risk as it pertains to the omission of radiotherapy for DCIS patients. Currently neither the National Comprehensive Cancer Network DCIS guidelines nor the American College of Radiology specifies a set of criteria to identify low-risk patients suitable for observation alone following breast conservative surgery, which has been confirmed by a recently updated DEGRO practical guidelines [25–27].

The NSABP B-17 trial [5], evaluating patterns of failure, found that some tumor characteristics, such as comedo necrosis, solid tumor-type DCIS, moderate/marked lymphoid infiltrate, and multifocality, were associated with ipsilateral breast tumor recurrence, with a trend for uncertain/involved margins.

In order to optimize treatment (mastectomy or breast-conserving surgery followed by radiation therapy or not), depending on the risk of local recurrence, Silverstein et al. have formulated the Van Nuys Prognostic Scoring Index (VNPI).

In this system, the following were considered: tumor's size, tumor's grading, the presence of necrosis, margin status, and age of the patient, and at each parameter was assigned a score.

In the initial analysis of the University of Southern California, 333 patients were submitted to breast conservative surgery with or without the addition of radiation therapy and were assigned VNPI scores to three and nine based on tumor size, margin, and histologic classification. Low-risk patients with VNPI scores of 3–4 did not significantly benefit from radiotherapy, whereas for intermediate risk patients with VNPI scores of 5–7, a 17% benefit in local control was observed with the addition of radiotherapy. High-risk patients with VNPI scores of 8–9 had large benefits with radiotherapy but had high recurrence rates despite radiotherapy, possibly making them candidates for mastectomy. A subsequent update of these results with the addition of patient age to the VNPI obtained the same results for low-, intermediate-, and high-risk DCIS patients, suggesting that VNPI could be used to stratify patients according to their recurrence risk to guide treatment decision [28–30].

However, the VNPI has not been successfully validated, and its external reproducibility and applicability remain controversial.

Many authors have investigated the role of histopathologic factors in this patient population. Altintas et al., even if in a retrospective study of only 88 patients, showed that the genomic grade index, a 97-gene signature, might improve the accuracy of the VNPI in identifying high-risk patients [31]. Kerlikowske et al. in a controlled study of 324 patients found that the risk of invasive ipsilateral breast tumor recurrence was linked to the presence of a p16, COX-2, and Ki-67 triple-positive immunophenotype, while the risk of noninvasive ipsilateral breast tumor recurrence was increased in patients with either ER-, HER-2+, and Ki-67+ or p16+, COX-2-, and Ki-67+ status [32].

A recent Chinese observational study evaluated the clinical presentation, treatment, and outcome of DCIS patients, with special attention on the role of tumor subtype. The primary endpoint of this study was overall survival and breast cancer-specific mortality. The patients were divided into four subgroups based on the hormonal status and expression of HER 2: HoR+/HER-, HoR+/HER+, HoR-/HER+, and triple negative (TN). Patients with triple-negative breast cancer were more likely to have tumors that were higher in grade and larger and with ductal and comedo histology, with a greater chance of having a worse prognosis than other subtypes. Breast-conserving surgery plus radiotherapy was the preferable option and resulted in this study in survival rates better than those achieved with mastectomy [14].

Another risk-stratification model comes from a nomogram of Memorial Sloan Kettering Cancer Center, which includes age, clinical presentation, tumor grade, necrosis, margin status, radiotherapy treatment or not, family history, taking hormone therapy, and year of treatment into a composite score between 0 and 500. In this nomogram, each factor is weighted based on its impact on rates of breast tumor recurrence with key factors represented by radiation and endocrine therapy [33].

At present, with the data available, it can be concluded that the postoperative radiation therapy significantly reduces the incidence of local recurrence in all

categories of patients and is very difficult to identify a category of truly low-risk patients. There is no scientific level I evidence that identifies a subset of limited-risk patients, such as not benefit from postoperative radiotherapy. Therefore, the omission of radiotherapy after conservative surgery should be reserved only for a some cases, carefully selected, and after adequate discussion with the patient.

NCCN Guidelines [25] suggest that if the patients and the physician view the individual risk as low, some patients may be treated by excision alone (category 2B of evidence).

It required a careful selection of the patients at the time of surgery, in order to identify patients who do not undergo postoperative radiotherapy and who may be candidates for mastectomy.

Genetic assays and biomarkers are the prognostic tools of the future but require further study and validation before widespread clinical use.

Future research will need to examine not only local control but also evaluate overall survival, late toxicity of the treatments, and the balance between survival outcome and quality of life following treatment [34, 35].

10.4 Volumes, Doses, and Fractionation

After conservative surgery, the irradiation of whole breast is indicated. The recommended dose is 50–50.4 Gy with conventional fractionation (1.8–2 Gy/fraction). Many authors have evaluated the role of a boost to the lumpectomy cavity in addition to whole-breast irradiation in patients with DCIS, especially those of young age or with another adverse prognostic factors, such as close or positive margins and high-grade DCIS, with a total dose of 10–20 Gy in several publications [36–39]. The administration of a boost resulted in improved local control, particularly in younger patients (<45 years).

A recent meta-analysis of observational studies investigated the role of boost and hypofractionation as adjuvant radiotherapy in patients with DCIS. Thirteen trials were considered eligible for the analysis. No difference in the risk of local recurrence was observed between the patients that received boost compared to patients that do not received boost, in the general cohort of patients (12 retrospective studies, 6943 patients analyzed). However if only the patients with positive margins were included, there was a significant benefit (six studies, 811 patients). The authors also performed subgroup analyses according to patient age (<50 and <45 years), but no significant relationship was found [40].

Currently, there are two prospective randomized trials addressing the role of boost irradiation in DCIS that have completed patient accrual. The TROG 07.01 trial is a randomized phase III study of radiation doses and fractionation schedules in non-low-risk DCIS of the breast. The study has four arms and studies both hypofractionation compared to standard fractionation and boost versus no boost. Standard fractionation is 50 Gy in 25 fractions with or without boost to the tumor bed of 10 Gy in 5 fractions; instead hypofractionation is 42.5 Gy in 16 fractions with or without boost to the tumor bed of 10 Gy in 4 fractions (2.5 Gy daily fractions).

Patient characteristics are age < 50 years or age \geq 50 years with at least one of the following: symptomatic presentation, palpable tumor, multifocal disease, microscopic tumor size \geq 1.5 cm in maximum dimension, intermediate or high nuclear grade, central necrosis, comedo histology, and radial surgical resection margin <10 mm. The primary endpoint is the time to local recurrence, measured from the date of randomization to the date of first evidence of local recurrence; secondary endpoints are overall survival, time to disease recurrence, cosmetic outcome, radiation toxicity, and quality of life.

The French Bonbis trial is a phase III randomized French multicentric study to evaluate the impact of a localized 16 Gy boost after conservative surgery and a 50 Gy whole-breast irradiation in breast DCIS. The primary endpoint is local relapse-free survival; secondary endpoints are relapse-free survival, overall survival, acute and late toxicities, cosmetic results, and quality of life [35].

In the last few years, there has been a considerable interest for the hypofractionated radiotherapy in the treatment of invasive cancer, both in the whole-breast irradiation and in the partial-breast irradiation. The effectiveness of hypofractionated whole-breast irradiation was confirmed by retrospective studies and some randomized trials. With regard to DCIS, no prospective phase III study has been published so far; in the year 2007 the multicenter international trial TROG 07.01 started, the results of which will be available in a few years. Some phase I/II prospective studies and retrospective studies [38, 41–46] on hypofractionated radiotherapy, including case studies of pure DCIS or invasive and ductal carcinoma in situ, show promising results, both in terms of local control and in terms of toxicity.

In the recent meta-analysis of Nilsson et al., there was no significant difference between conventional and hypofractionated radiotherapy for DCIS; however a trend for lower recurrence with hypofractionation was observed [40].

In summary, hypofractionation seems to be a safe alternative for patients with DCIS undergoing breast-conserving surgery. However, data should be validated by further prospective trials.

The role of partial-breast irradiation (PBI) in the treatment of DCIS is controversial, on the basis of the histopathological knowledge of spread modality of cancer, within the complex duct-lobular breast system. The studies that have evaluated PBI in DCIS patients are few and nonrandomized. According to the ASTRO (American Society for Radiation Oncology) and GEC-ESTRO (Groupe Européen de Curiethérapie – European Society for Radiotherapy and Oncology) criteria, PBI should be evaluated with caution when the lesion diameter is \leq 3 mm and is not indicated when is >3 mm [47, 48]. In any case PBI is not a standard therapy for DCIS and must not be offered outside of study protocols.

Various irradiation techniques are available today for the treatment of breast DCIS patients.

The choice of a 3D conformal radiotherapy (3D CRT) or a intensity-modulated radiotherapy (IMRT) with static or rotational techniques and the choice of geometries, energies, and weights is influenced by the shape of the PTV, by the consequent distribution of the dose, and by the need of organ at risk sparing.

References

1. Bleicher RJ. Duct carcinoma in situ. *Surg Clin N Am.* 2013;93:393–410.
2. Cutuli B, Bernier J, Poortmans P. Radiotherapy in DCIS, an underestimated benefit? *Radiother Oncol.* 2014;112:1–8.
3. American College of Radiology. Practice guideline for the management of ductal carcinoma in-situ of the breast (DCIS). *J Am Coll Surg.* 2007;205:145–61.
4. Boughey JC, Gonzales RJ, Bonner E, et al. Current treatment and clinical trial developments for ductal carcinoma in situ of the breast. *Oncologist.* 2007;12:1276–87.
5. Wapnir IL, Dignam JJ, Fisher B, et al. Long-term outcomes of invasive ipsilateral breast tumor recurrences after lumpectomy in NSABP B-17 and B-24 randomized clinical trials for DCIS. *J Natl Cancer Inst.* 2011;103:478–88.
6. Donker M, Litiere S, Werutski G, et al. Breast-conserving treatment with or without radiotherapy in duct carcinoma in situ: 15-year recurrence rates and outcomes after recurrence, from the EORTC 10853 randomized phase III trial. *J Clin Oncol.* 2013;31:4054–9.
7. Holmberg L, Garmo H, Granstrand B, et al. Absolute risk reductions for local recurrence after postoperative radiotherapy after sector resection for ductal carcinoma in situ of the breast. *J Clin Oncol.* 2008;28:1247–52.
8. Cuzick J, Sestak I, Pinder SE, et al. Effect of tamoxifen and radiotherapy in women with locally excised ductal carcinoma in situ: long-term results from the UK/ANZ DCIS trial. *Lancet Oncol.* 2011;12:21–9.
9. Viani GA, Stefano EJ, Alfonso SL, et al. Breast-conserving surgery with or without radiotherapy in women with ductal carcinoma in situ: a meta-analysis of randomized trials. *Radiat Oncol.* 2007;2:28–40.
10. Goodwin A, Parker S, Ghersi D, et al. Post-operative radiotherapy for ductal carcinoma in situ of the breast (Review). *Cochrane Database Syst Rev.* 2009;4:CD000563.
11. Early Breast Cancer Trialists' Collaborative Group (EBCTCG). Overview of the randomized trials of radiotherapy in ductal carcinoma in situ of the breast. *J Natl Cancer Inst Monogr.* 2010;41:162–77.
12. Cutuli B, Lemanski C, Fourquet A, et al. Breast conserving surgery with or without radiotherapy versus mastectomy for duct carcinoma in situ. French survey experience. *Br J Cancer.* 2009;100:1048–54.
13. Alvarado R, Lari SA, Roses RE, et al. Biology treatment and outcome in very young and older women with DCIS. *Ann Surg Oncol.* 2012;19:3777–84.
14. Wu Q, Li J, Sun S, et al. Breast carcinoma in situ: an observational study of tumor subtype, treatment and outcome. *Oncotarget.* 2017;8(2):2361–71.
15. Silverstein MJ. The Van Nuys/USC experience by treatment. In: Silverstein MJ, Recht A, Lagios M, editors. *Duct carcinoma in situ of the breast.* Philadelphia: Lippincott William and Wilkins; 2002. p. 337–42.
16. Dunne C, Burke JP, Morrow M, et al. Effects of margin status on local recurrence after breast conservation and radiation therapy for ductal carcinoma in situ. *J Clin Oncol.* 2009;27:1615–20.
17. Wang SY, Chu H, Shamliyan T, et al. Network meta-analysis of margin threshold for women with ductal carcinoma in situ. *J Natl Cancer Inst.* 2012;104:507–16.
18. Cutuli B, Cohen-Solal-le Nir C, de Lafontan B, et al. Breast-conserving therapy for ductal carcinoma in situ of the breast: the French Cancer Centers' experience. *Int J Radiat Oncol Biol Phys.* 2002;53:868–79.
19. Rakovitch E, Nofech-Mozes S, Narod SA, et al. Can we select individuals with low risk ductal carcinoma in situ (DCIS)? A population-based outcomes analysis. *Breast Cancer Res Treat.* 2013;138:581–90.
20. Wong JS, Chen YH, Gadd MA, et al. Eight-year update of a prospective study of wide excision alone for small low- or intermediate-grade ductal carcinoma in situ of the breast. *Breast Cancer Res Treat.* 2014;143:343–50.

21. Hughes LL, Wang M, Page DL, et al. Local excision alone without irradiation for ductal carcinoma in situ of the breast: a trial of the Eastern Cooperative Oncology Group. *J Clin Oncol.* 2009;27:5319–24.
22. Solin LJ, Gray R, Hughes LL, et al. Surgical excision without radiation for ductal carcinoma in situ of the breast: 12-year results from the ECOG-ACRIN E5194 study. *J Clin Oncol.* 2015;33:3938–44.
23. Motwani SB, Goyal S, Moran S, et al. Ductal carcinoma in situ treated with breast-conserving surgery and radiotherapy: a comparison with ECOG study 5194. *Cancer.* 2011;117:1156–62.
24. McCormick B, Winter K, Hudis C, et al. RTOG 9804: a prospective randomized trial for good-risk ductal carcinoma in situ comparing radiotherapy with observation. *J Clin Oncol.* 2015;33:709–15.
25. National Comprehensive Cancer Network Guidelines: breast cancer. Available at: https://www.nccn.org/professionals/physician_gls/pdf/breast.pdf. Accessed 2 2016.
26. Moran MS, Bai HX, Harris EE, et al. ACR appropriateness criteria ductal carcinoma in situ. *Breast J.* 2012;18:8–15.
27. Souchon R, Sautter-Bihl ML, Sedlmayer F, et al. DEGRO practical guidelines: radiotherapy of breast cancer II: radiotherapy of noninvasive neoplasia of the breast. *Strahlenther Onkol.* 2014;190:8–16.
28. Silverstein MJ, Lagios MD, Craig PH, et al. A prognostic index for ductal carcinoma in situ of the breast. *Cancer.* 1996;77:2267–74.
29. Silverstein MJ. The University of Southern California/Van Nuys prognostic index for ductal carcinoma in situ of the breast. *Am J Surg.* 2003;186:337–43.
30. Silverstein MJ, Lagios MD. Choosing treatment for patients with ductal carcinoma in situ: fine tuning of the University of California/Van Nuys prognostic index. *J Natl Cancer Inst Monogr.* 2010;2010:193–6.
31. Altintas S, Toussaint J, Durbecq V, et al. Fine tuning of the Van Nuys prognostic index (VNPI) 2003 by integrating the genomic grade index (GGI): new tools for ductal carcinoma in situ (DCIS). *Breast J.* 2011;17:343–51.
32. Kerlikowske K, Molinaro AM, Gauthier MI, et al. Biomarker expression and risk of subsequent tumours after initial ductal carcinoma in situ diagnosis. *J Natl Cancer Inst.* 2010;102:627–37.
33. Rudloff U, Jacks LM, Goldberg JJ, et al. Nomogram for predicting the risk of local recurrence after breast-conserving surgery for ductal carcinoma in situ. *J Clin Oncol.* 2010;28:3762–9.
34. Shah C, Vicini FA, Berry S, et al. Ductal carcinoma in situ of the breast. Evaluating the role of radiation therapy in the management and attempts to identify low-risk patients. *Am J Clin Oncol.* 2015;38:526–33.
35. Krug D, Souchon R. Radiotherapy of ductal carcinoma in situ. *Breast Care.* 2015;10:259–64.
36. Omlin A, Amichetti M, Azria D, et al. Boost radiotherapy in young women with ductal carcinoma in situ: a multicentre, retrospective study of the Rare Cancer Network. *Lancet Oncol.* 2006;7:652–6.
37. Riou O, Lemanski C, Guillaumon V, et al. Role of the radiotherapy boost on local control in ductal carcinoma in situ. *Int J Surg Oncol.* 2012;2012:748196.
38. Wong P, Lambert C, Agnihotram RV, et al. Ductal carcinoma in situ—the influence of the radiotherapy boost on local control. *Int J Radiat Oncol Biol Phys.* 2012;82:e153–8.
39. Meattini I, Livi L, Franceschini D, et al. Role of radiotherapy boost in women with ductal carcinoma in situ: a single-center experience in a series of 389 patients. *Eur J Surg Oncol.* 2013;39:613–8.
40. Nilsson C, Valachis A. The role of boost and hypofractionation as adjuvant radiotherapy in patients with DCIS: a meta-analysis of observational studies. *Radiother Oncol.* 2015;114:50–5.
41. Freedman GM, Anderson PR, Goldstein LJ, et al. Four-week course of radiation for breast cancer using hypofractionated intensity modulated radiation therapy with an incorporated boost. *Int J Radiat Oncol Biol Phys.* 2007;68:347–53.
42. Constantine C, Parhar P, Lymberis S, et al. Feasibility of accelerated whole-breast radiation in the treatment of patients with ductal carcinoma in situ of the breast. *Clin Breast Cancer.* 2008;8:269–74.

43. Livi L, Stefanacci M, Scoccianti S, et al. Adjuvant hypofractionated radiation therapy for breast cancer after conserving surgery. *Clin Oncol (R Coll Radiol)*. 2007;19:120–4.
44. Williamson D, Dinniwell R, Fung S, et al. Local control with conventional and hypofractionated adjuvant radiotherapy after breast-conserving surgery for ductal carcinoma in-situ. *Radiother Oncol*. 2010;95:317–20.
45. Wai ES, Lesperance ML, Alexander CS, et al. Effect of radiotherapy boost and hypofractionation on outcomes in ductal carcinoma in situ. *Cancer*. 2011;117:54–62.
46. Ciervide R, Dhage S, Guth A, et al. Five year outcome of 145 patients with ductal carcinoma in situ (DCIS) after accelerated breast radiotherapy. *Int J Radiat Oncol Biol Phys*. 2012;83:e159–64.
47. Smith BD, Arthur DW, Buchholz TA, et al. Accelerated partial breast irradiation. Consensus statement from the American Society for Radiation Oncology (ASTRO). *Int J Radiat Oncol Biol Phys*. 2009;74:987–1001.
48. Polgár C, Van Limbergen E, Pötter R, et al. Patient selection for accelerated partial-breast irradiation (APBI) after breast-conserving surgery: recommendations of the Groupe Européen de Curiethérapie-European Society for Therapeutic Radiology and Oncology (GEC-ESTRO) breast cancer working group based on clinical evidence (2009). *Radiother Oncol*. 2010;94:264–73.

Mirco Pistelli and Rossana Berardi

Once the diagnosis of DCIS is certain, clear communication between surgeon, oncologist, and patient regarding the risks of recurrence and death is crucial, since patients with DCIS tend to overestimate the risk of death from breast cancer. Surgical excision of DCIS remains the cornerstone of treatment with an excellent outcome. Medical therapy following surgery can be offered with the aim of preventing potential recurrence of breast cancer in situ and reducing the risk of developing invasive breast tumor (IDC).

Currently, there is no evidence to support the use of chemotherapy and biological targeted therapies in the treatment of DCIS. Conversely, two randomized phase III trials support the use of tamoxifen following surgery. Tamoxifen (TMX) is a selective estrogen receptor modulator (SERM) that blocks the hormone estrogen receptors, which binds the female hormones (estrogen hormones) stimulating cancer cells' growing. Nowadays, TMX is the only effective systemic therapy to prevent DCIS. The benefits of endocrine therapy (ET) with TMX in DCIS are much less consistent than in invasive ductal cancer. The decision about whether or not to offer the adjuvant treatment with tamoxifen should be therefore carefully individualized patient-by-patient, based on the relationship between potential benefits and expected side effects.

The NSABP (National Surgical Adjuvant Breast and Bowel Project) B-24 was the first study published on the use of TMX in DCIS, enrolling 1804 women diagnosed with DCIS randomized to conservative surgery, complementary radiotherapy (RT), and TMX 20 mg/daily for 5 years vs. conservative surgery + RT + placebo. Primary end point of the study was to evaluate the incidence of in situ and/or invasive breast cancer recurrence, either in the breast that underwent surgery or in

M. Pistelli

Medical Oncology Unit, Università Politecnica delle Marche—Azienda Ospedaliero-Universitaria Ospedali Riuniti Umberto I—GM Lancisi—G Salesi di Ancona,
Via Conca 71, Ancona 60126, Italy
e-mail: r.berardi@univpm.it

R. Berardi (✉)

Medical Oncology Unit, Azienda Ospedaliero-Universitaria Ospedali Riuniti, Ancona, Italy

the contralateral breast, in the two treatment arms. The study showed a statistically significant reduction in the total number of events at 5 years related to TMX vs. placebo (8.2% vs. 13.4%; $p = 0.0009$). This benefit has been seen in terms of risk reduction of both invasive tumor recurrence in the ipsilateral gland and in contralateral breast cancer.

The cumulative incidence of all invasive breast cancer in the TMX group was 4.1% over 5 years: ipsilateral breast in 2.1% cases, contralateral in 1.8%, and locoregional/distant in 0.2%. The most updated study analysis, at a median follow-up of 163 months, showed a recurrence rate reduction of ipsilateral invasive cancer in the group of patients treated with conservative surgery + RT + TMX (8.5%) compared to the group of women treated with conservative surgery + RT + placebo (10%), with 32% of reduction in the risk of recurrence (HR = 0.68; 95% CI = 0.49–0.95; $p = 0.025$). In terms of noninvasive recurrence, the addition of TMX to locoregional treatment resulted in a nonsignificant events' risk reduction: 7.5% vs. 8.3% (HR = 0.84; 95% CI = 0.60–1.19; $p = 0.33$).

In the NSABP B-24 study, the cumulative incidence at 15 years of contralateral breast cancer, either as first event or as contralateral recurrence, was 7.3% among patients treated with TMX and 10.8% among patients who received placebo, and tamoxifen showed a 32% risk reduction of contralateral breast cancer (HR = 0.68; 95% CI = 0.48–0.95; $p = 0.023$).

The NSABP-B24 study enrolled patients either with breast cancer ER-positive or with breast cancer ER-negative. A following retrospective analysis on 41% of the original population of the study only partially centralized and assessed the relationship between the ER expression and the benefit from TMX. In ER-positive breast cancer (76% of cases), the treatment with TMX vs. placebo significantly reduced the risk of subsequent breast cancer (as a definitive event) at 10 years (HR = 0.49; $p < 0.001$) and at 14.5 years (HR = 0.60; $p = 0.003$), even after multivariate analysis (HR = 0.64; $p = 0.003$). Similar results, although less significant, were obtained from the analysis of separate events: ipsilateral and contralateral carcinomas and invasive and noninvasive carcinomas. No benefit was observed from the use of TMX in patients with DCIS and in the absence of ER expression (Fig. 11.1) [1, 2].

A recent joint analysis from the NSABP B-24 and the NSABP B-17 studies evaluating 818 patients in total with DCIS who had conservative surgery, randomized to RT alone or complementary follow-up, documented a significant increase of the risk of death in cases of recurrent ipsilateral invasive cancer and found no association between DCIS recurrence and mortality. In addition, there was no difference in survival (global and breast cancer-related) among the different treatment groups: surgery, surgery + RT, and surgery + RT + TMX [3].

In 2011 an update of the results of a second study of UK/ANZ DCIS stage (the UK, Australia, and New Zealand ductal carcinoma in situ) was published, evaluating the role of RT and/or TMX in patients treated with conservative surgery for DCIS. The study enrolled 1701 patients, with the aim of analyzing the following therapeutic approaches: surgery alone, surgery followed by RT, surgery followed by RT and TMX (20 mg/daily for 5 years), and surgery followed

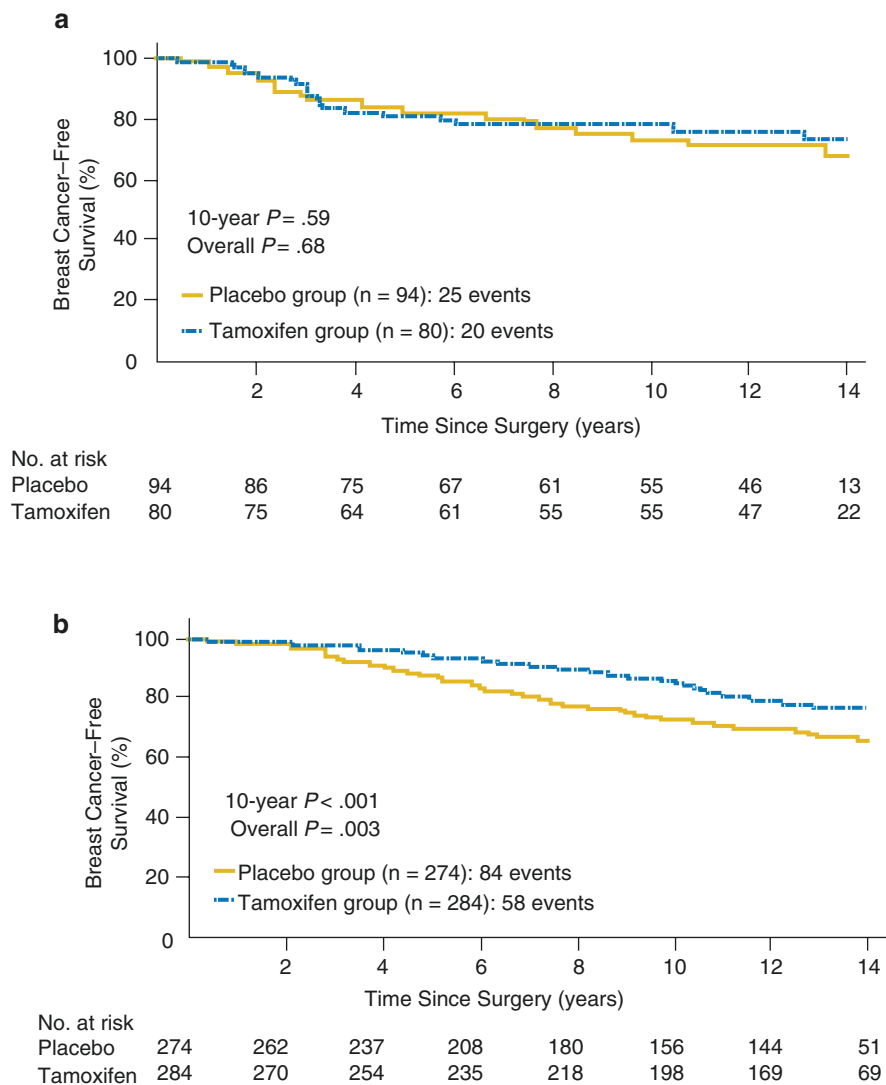


Fig. 11.1 Kaplan-Meier curves showing probability of any subsequent breast cancer in patients with estrogen receptor (ER)-negative (a) and ER-positive DCIS (b) treated with adjuvant placebo vs. tamoxifen. Tamoxifen benefit was restricted to ER-positive DCIS

by TMX (20 mg/daily for 5 years). In the arms treated with TMX, over a median of 12.7 years of follow-up, a significant reduction of all breast events (HR = 0.71; 95% CI 0.58–0.88; $p = 0.002$. Figure 11.2), of the risk of ipsilateral DCIS (HR = 0.70; 95% CI 0.51–0.86; $p = 0.03$), and of contralateral tumors (HR = 0.44, 95% CI 0.25 to 0.77; $p = 0.005$) was showed [4].

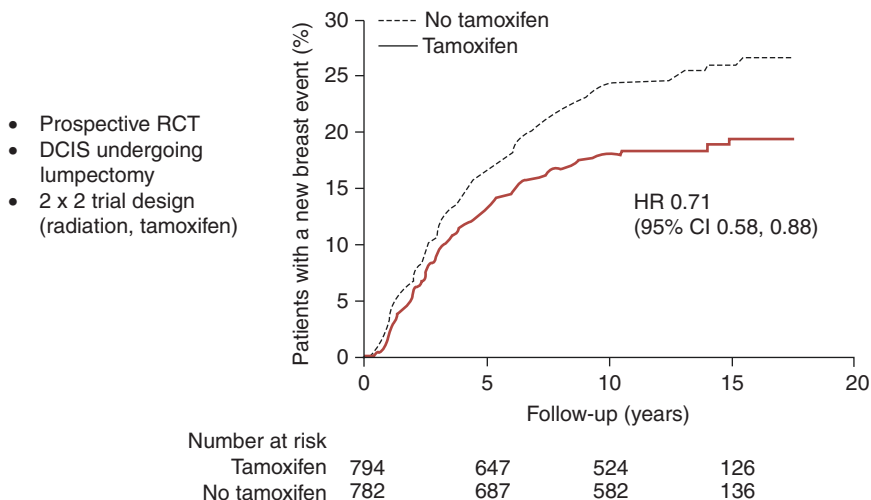


Fig. 11.2 UK/ANZ study showed a significant reduction of all breast events in the arms treated with tamoxifen, over a median of 12.7 years of follow-up

However, no difference in the incidence of ipsilateral invasive relapse in the various treatment groups was highlighted. Moreover, the subgroup analysis showed some benefit related to TMX in patients' group treated with surgery alone but not in the other subgroups, including the arm combining surgery with RT + TMX (Fig. 11.3).

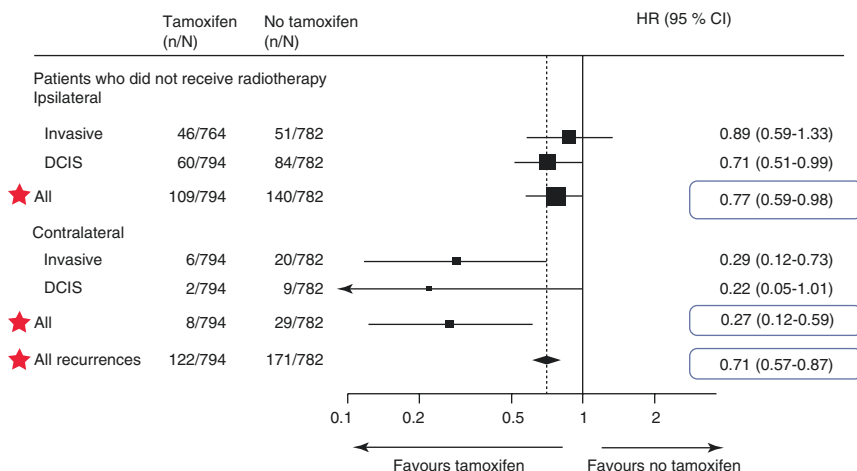
A recent combined analysis of NSABP-B24 trial and UK/ANZ19 concluded that TMX after breast-conserving surgery and radiation therapy led to a risk reduction of invasive ipsilateral breast cancer (pooled RR = 0.61; 95% CI 0.41–0.92) and contralateral DCIS (RR = 0.4; 95% CI 0.16–0.96), independently from the age; moreover, tamoxifen had no impact on overall survival or on breast cancer-related mortality [5].

In conclusion, whether or not to offer TMX in DCIS treatment should be based on an individual analysis between benefits and expected side effects. TMX may be considered for treatment of hormone receptor-positive DCIS either in the premenopausal or in the postmenopausal setting. Standard treatment lasts 5 years.

Currently there are several ongoing clinical trials aimed to assess the efficacy of endocrine therapy in DCIS. Nowadays, the treatment with aromatase inhibitors remains approved only in invasive breast cancer setting. In fact, there is still a lack of data regarding the use of aromatase inhibitors in the treatment of DCIS.

At the ASCO (American Society for Clinical Oncology) Meeting in 2015, results from the phase III study NSABP B-35 were presented. 3104 postmenopausal patients diagnosed with hormone receptor-positive DCIS treated with breast-conserving surgery plus radiation therapy were randomized to receive TMX 20 mg/daily or anastrozole 1 mg/daily, over 5 years in total (Fig. 11.4).

UK/ANZ Trial: New breast events
No radiation arms; median follow up 12.7 years



UK/ANZ Trial: New breast events
Adjuvant RT arms; median follow up 12.7 years

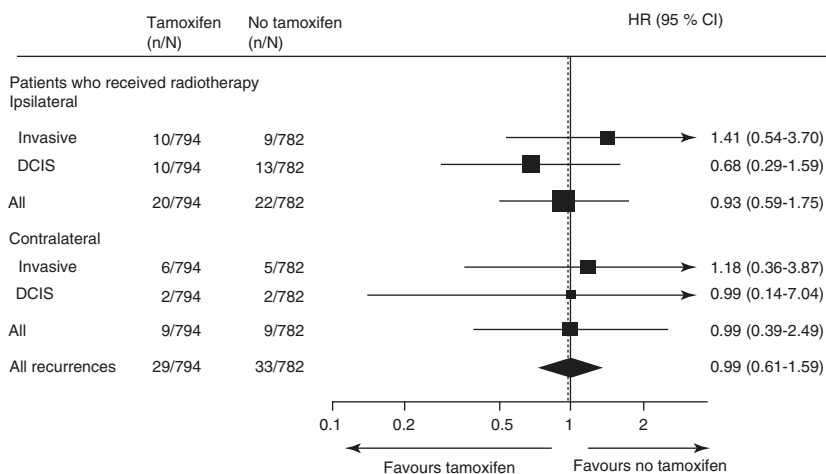
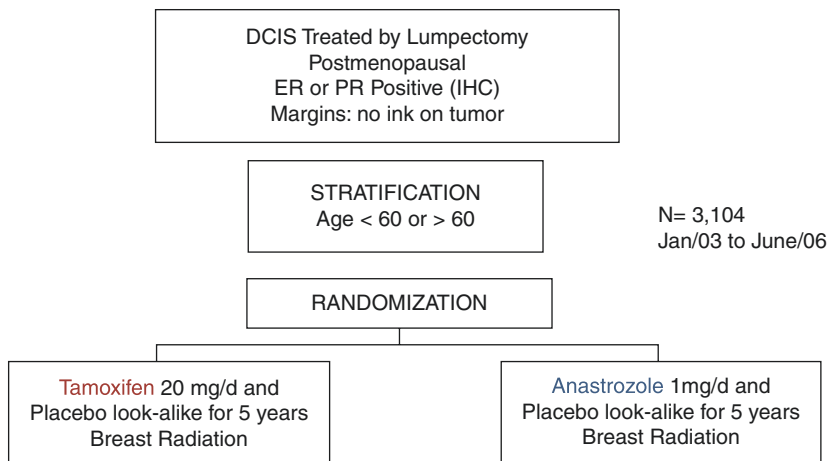


Fig. 11.3 The subgroup analysis of UK/ANZ trial showed some benefits related to tamoxifen in patients' group treated with surgery alone but not in the arm which combines surgery, radiotherapy, and endocrine therapy



Primary endpoint: BC free interval–any BC event
 Secondary endpoints: DFS, OS, IBTR, CBC, fractures, QOL

Fig. 11.4 The diagram summarizing the random assignment of patients in the clinical trial NSABP B-35

At a median follow-up of 9 years, anastrozole significantly improved breast cancer-free interval (HR 0.73; $p = 0.02$), which was the primary end point of the study; stratified according to the age, the advantage for anastrozole remained in patients <60 years ($p = 0.003$) [6].

A double-blind placebo-controlled randomized study (NCIC CTG MAP.3) evaluated the role of exemestane 25 mg/daily in 4560 postmenopausal women with high risk of breast cancer (age > 60 years, risk calculated according to Gail greater than 1.66%, previous diagnosis of ductal/lobular atypical hyperplasia, ADH and ALH, respectively, lobular carcinoma in situ, DCIS treated with mastectomy) [7].

At a median follow-up of 35 months, 11 invasive breast cancers were reported in the exemestane group vs. 32 in the placebo group, with a benefit in terms of relative reduction of the annual risk of invasive breast cancer of 65% (0.19% vs. 0.55%; HR = 0.35; 95% CI 0.18–0.7; $p = 0.002$). This advantage was confirmed also in women with a prior diagnosis of DCIS (5% of the study population). However, the short follow-up and the smallness of the subgroup with DCIS do not allow to transfer the results into clinical practice.

A recent meta-analysis evaluated data from nine trials about chemoprevention (including 83,399 women at increased risk of disease), treated with selective estrogen receptor modulators (SERMs, tamoxifen, raloxifene, arzoxifene, and lasofoxifene) [8]. At a median follow-up of 65 months, the use of SERMs led to a reduction of 38% (hazard ratio [HR] = 0.62, 95% CI from 0.56 to 0.69) in the incidence of invasive and in situ ductal carcinoma (42 women were to be treated to prevent an event over the first 10 years of follow-up). The reduction was greater in the first 5 years of follow-up than the subsequent five ones (42%, HR = 0.58, 95% CI

0.51–0.66; $p < 0.0001$ vs. 25%, HR = 0.75, 95% CI 0.61–0.93; $p = 0.007$). The use of SERMs was related to a significantly increased incidence of thromboembolic events (odds ratio = 1.73, 95% CI 1.47–2.05; $p < 0.0001$), associated with a significant reduction (34%) of vertebral fractures (0.66, 0.59–0.73) and a small effect on non-vertebral fractures (0.93, 0.87–0.99).

References

1. Dignam J, Wolmark N, et al. Tamoxifen in treatment of intraductal breast cancer: national surgical adjuvant breast and bowel project B-24 randomised controlled trial. *Lancet*. 1999;353:1993–2000.
2. Allred DC, Anderson SJ, Paik S, et al. Adjuvant tamoxifen reduces subsequent breast cancer in women with estrogen receptor-positive ductal carcinoma in situ: a study based on nsabp protocol B-24. *J Clin Oncol*. 2012;30:1268–73.
3. Wapnir IL, Dignam JJ, Fisher B, et al. Long-term outcomes of invasive ipsilateral breast tumor recurrences after lumpectomy in NSABP B-17 and B-24 randomized clinical trials for DCIS. *J Natl Cancer Inst*. 2011;103:478–88.
4. Cuzick J, Sestak I, Pinder SE, et al. Effect of tamoxifen and radiotherapy in women with locally excised ductal carcinoma in situ: long-term results from the UK/ANZ DCIS trial. *Lancet Oncol*. 2011;12:21–9.
5. Petrelli F, Barni S. Tamoxifen added to radiotherapy and surgery for the treatment of ductal carcinoma in situ of the breast: a meta-analysis of 2 randomized trials. *Radiother Oncol*. 2011;100:195–9.
6. Anastrozole versus tamoxifen in post-menopausal women with ductal carcinoma in situ undergoing lumpectomy plus radiotherapy (NSABP B-35): A randomized, double blind, Phase 3 Clinical trial, *Cancer*. 2016;387:849–856.
7. Goss PE, Ingle JN, Alés-Martínez JE, et al. Exemestane for breast-cancer prevention in post-menopausal women. *N Engl J Med*. 2011;364:2381–91.
8. Cuzick J, Sestak I, Bonanni B, et al. Selective oestrogen receptor modulators in prevention of breast cancer: an updated meta-analysis of individual participant data. *Lancet*. 2013;381:1827–34.

Federico Buggi, Annalisa Curcio, Matteo Mingozzi,
Daniele Vecchio, Francesco Marongiu, Dario Lelli,
and Secondo Folli

The term “ductal carcinoma in situ” (DCIS) of the breast represents a heterogeneous group of neoplastic lesions histologically confined to the breast ducts.

While DCIS made up roughly 3% of breast cancers detected prior to the advent of screening, the diagnosis of DCIS increased dramatically following its introduction and now comprises approximately 20% of all mammographically diagnosed breast cancers [1]. Pathologically, DCIS refers to the proliferation of neoplastic epithelial cells within the tubulo-lobular system of the breast; these abnormal epithelial cells have the morphological features of invasive carcinoma of the breast but, critically, differ from invasive carcinoma by being confined by the myoepithelial cells and basement membrane of the ducts, with no invasion of the stroma or of lymphatic or blood vessels [2].

The traditional vision of DCIS has been comprehensively summarized by Silverstein as such:

DCIS of the breast is a proliferation of presumably malignant epithelial cells within the ducto-lobular system of the breast without evidence by light microscopy of invasion through the basement membrane into the surrounding stroma. I say ‘presumably,’ because not every untreated DCIS lesion will go on to become an invasive breast cancer. Although we consider DCIS to be cancer, it lacks two components of the fully expressed malignant phenotype, i.e., invasion and metastasis. It is these defects, along with its distribution, generally within a single ductal system, that makes DCIS a surgical disease [3]; preventing local recurrence is important because about one half of such recurrences are invasive cancers with the potential to metastasize [4].

Accordingly, the present management of DCIS is focused on the prevention of local recurrence and therapeutic approaches parallel the treatment for invasive

F. Buggi • A. Curcio • M. Mingozzi • D. Vecchio • F. Marongiu • D. Lelli
U.O.C. Senologia, Ospedale Morgagni-Pierantoni, Forlì (FC), Italy

S. Folli (✉)

S.C. Chirurgia Senologica, Istituto Nazionale Tumori, Milan, Italy

e-mail: s.folli@ausl.fo.it

breast cancer (with exclusion of chemotherapy) including surgery, radiation therapy, and adjuvant endocrine treatments. A thorough discussion of the treatments for DCIS is articulated in other chapters of this book, but, in summary, patients with DCIS undergo local treatment with mastectomy or breast-conserving therapy (BCT); BCT consists of lumpectomy (also called breast-conserving surgery, wide excision, or partial mastectomy) followed in most cases by adjuvant radiation, even though radiation therapy may be reasonably omitted in a selected population of patients with low-risk disease. A sentinel lymph node biopsy can be avoided in most women, but it should be obtained in women with high-risk features for whom resection may compromise the ability to perform a future sentinel lymph node biopsy. Then, following local treatment, the decision to administer endocrine therapy to reduce the risk of subsequent cancers depends upon the choice of local therapy and the tumor hormone receptor status.

However, while Silverstein's description of the "DCIS issue" holds true as a whole, gray areas exist in the treatment decision-making process, for several reasons.

First, although mastectomy achieves an excellent long-term survival and results curative for over 98% of patients with DCIS [5–9], with a local recurrence rate on the order of 1% [10–13], it provides an overly aggressive treatment for many women. Similarly, while BCT has less morbidity, it is associated with a higher risk of local recurrence, roughly threefold [1]; thus, the most suitable surgical option at the specific-patient level is not always straightforward. In fact, the progression rate varies widely according to specific DCIS subtypes. It is calculated that, overall, 14–53% of untreated DCIS will progress to invasive cancer [14, 15], but, in particular, it was estimated that the rate of progression from DCIS to invasive cancer across a 10-year period is 16% for low-grade DCIS (for patients older than 45 years with lesions larger than 2.5 cm) and 60% for high-grade DCIS (for patients younger than 45 years with lesions larger than 1 cm), which means that a nearly fourfold risk is implied by a different combination of clinical features.

Moreover, some observational data are in contrast with the assumed completely malignant-lacking phenotype of DCIS and should further motivate the ongoing quest for a deeper understanding of its biology.

It is noteworthy that among patients receiving a treatment for DCIS, even mastectomies resulted associated with a nonzero breast cancer-specific mortality [1]. Besides, women with in situ breast cancer, even after treatment, are at increased risk of subsequent invasive breast cancer compared to women in the general population [16]. In particular, such increased risk of developing a recurrence (either in situ or invasive) affects both the ipsilateral and contralateral breast, and, in a study from the National Comprehensive Cancer Network Outcomes Database [17], developing an ipsilateral second breast cancer resulted not significantly more likely than developing a contralateral recurrence (55% vs. 45%), as well as developing an invasive second breast cancer (ipsilateral or contralateral) was not significantly more likely than developing a noninvasive one (49% vs. 51%). These findings confirmed former observations that suggested a clonal relation between index DCIS and second ipsilateral DCIS events [18] and extended the relation also to DCIS and contralateral recurrence, raising the intriguing possibility that both DCIS characteristics and

patient traits influence the type of breast cancer that may subsequently develop in either breast, particularly in terms of grading and estrogen receptors expression; the awareness that women with DCIS may be at risk of developing a recurrence of a similar phenotype may have the potential to inform clinical decision-making at the time of the index DCIS diagnosis.

Finally, from a biological perspective, some authors were able to demonstrate the presence of disseminated tumor cells in the bone marrow of patients (21.1%) with pathology-proven pure DCIS [19], albeit in a small case series.

From a clinical standpoint, despite the presumption that early treatment for DCIS would reduce cancer incidence and mortality [20], a small proportion of patients with DCIS ultimately die of breast cancer [21]; while some patients experience an in-breast invasive recurrence prior to death, some women die of breast cancer without first receiving a diagnosis of local invasive disease [22–24]. Therefore, it is unclear to what extent mortality from breast cancer after DCIS is the direct consequence of an invasive recurrence or whether fatal cases of DCIS have high malignant potential from the outset. In particular, it has not been shown that preventing invasive recurrences by means of radiotherapy or extensive breast surgery (mastectomy) reduces the risk of breast cancer-specific mortality, as long-term epidemiology studies have demonstrated that the removal of 50,000–60,000 lesions annually has not been accompanied by a reduction in the incidence of invasive breast cancers, and this is in contrast to the experience with colonic polyps or intraepithelial lesions of the cervix, for instance [20].

As stated above, an observational study [1] of women who received a diagnosis of DCIS from 1988 to 2011 in the Surveillance, Epidemiology, and End Results (SEER) database reported a 20-year breast cancer-specific mortality rate after a diagnosis of DCIS of 3.3%, meaning an increase by 1.8 times compared with the general population in the USA. Of interest, mortality rates appeared to be actually lower than rates reported in the past and reasonably due to a more precise diagnosis; it is unlikely that the decline in mortality was due to more effective treatments because mortality rates did not vary with specific treatment. Apart from lower mortality, many known basic epidemiologic data were confirmed in the abovementioned study, as women with DCIS who developed an ipsilateral invasive in-breast recurrence were 18.1 times more likely to die of breast cancer than women who did not; the use of radiotherapy confirmed to reduce to the half the risk of developing an ipsilateral invasive recurrence (from 5 to 2.5%) but did not reduce breast cancer-specific mortality at 10 years. Similarly, patients who underwent unilateral mastectomy had a lower risk of ipsilateral invasive recurrence at 10 years than patients who underwent lumpectomy but had a higher breast cancer-specific mortality which, however, did not result significant after adjustment for tumor size, grade, and other tumor-related factors.

Surprisingly, other much less straightforward findings emerged from the same study and can be added to earlier data depicting as incomplete the current understanding of DCIS: the majority (54.1%) of women with DCIS in the cohort who died of breast cancer did not experience an invasive in-breast recurrence (ipsilateral or contralateral) prior to death.

Formerly, in the Early Breast Cancer Trialists' Collaborative Group overview [25], there were 54 patients with DCIS (1.4% of all patients) who were reported to have experienced a distant or regional recurrence without any prior ipsilateral or contralateral in-breast cancer. In another study of more than 2000 women with DCIS who were treated at the University of Texas MD Anderson Cancer Center, 25 women developed distant metastases after a median follow-up of 4.5 years, of whom 16 had an intervening invasive recurrence but 9 did not [26].

Taken together, these data seem to suggest that cases of DCIS have more in common with small invasive cancers than previously thought and that considering DCIS as a preinvasive neoplastic lesion that is not lethal in itself should be revisited.

However, as death from breast cancer after DCIS is too rare to be used as an end point in randomized clinical trials, information on the lethality of DCIS must be indirectly derived from the features of its potential recurrence. Notably, for the vast majority of cases, a unilateral or contralateral recurrence of DCIS has no impact on mortality while an invasive cancer does (18-fold for unilateral and 13-fold for contralateral), leading to the accepted conclusion that nearly all risk depends on whether an invasive disease presents [20].

Fortunately, the absolute risk of dying from breast cancer is low, and the 3.3% mortality observed in the study by Narod [1] is not very different from the 2.69% risk of dying from breast cancer that an average woman faces during her lifetime according to the American Cancer Society [27]. So, the current conundrum in the management of DCIS patients actually comes down to the issue of whether to recommend adjuvant treatment to patients in addition to surgery, because it must be taken into consideration that there is a trade-off between treatments: aggressive treatment usually decreases the possibility of recurrence, but has difficult side effects, ranging from those caused by radiation and/or hormone therapy to the disfigurement caused by mastectomy.

The one-size-fits-all approach of adjuvant treatment for all patients with DCIS seems counterintuitive due to both the molecular heterogeneity of DCIS and the increasing trend toward individualized cancer treatment; so to aid in the decision-making, a number of factors are taken into account, including patient age and tumor margins, grade, and size, but the evidence to support these and other potential features as prognostic is variable.

In a meta-analysis based on 12 studies including more than 10,000 patients [28], Wang et al. evaluated the effects of several important characteristics such as biomarkers, focality, and method of detection as predictors for DCIS recurrence. Their findings suggest that women whose features of DCIS include positive margin, comedonecrosis, higher tumor grade, large tumor size, or multifocality or who are diagnosed due to a palpable mass or nipple discharge are associated with a higher risk of ipsilateral breast tumor recurrence. Also, although some features are statistically insignificant, patients whose DCIS is ER-negative, PR-negative, or HER2/neu-receptor-positive have a higher probability of ipsilateral breast tumor recurrence than those who do not present these features.

Margin status is the only feature that can be proactively managed by therapists, and it is a known prognostic parameter in DCIS, although the definition of a clear or

adequate excision margin varies; in fact, although margin status is undoubtedly important, the width of the margin required is not certain, perhaps because the estimation of margin width is highly variable, depending on the pathologist and other uncontrollable factors such as sampling and block orientation.

Data from a large meta-analysis [29] of DCIS treated with lumpectomy and RT showed that the presence of tumor cells at the excision margin or within 1 mm was associated with an increased risk of recurrence compared with wider margins, while excision margins of 2 mm were found to confer a lower risk of recurrence compared with 1 mm margins and were not associated with a significant difference in recurrence risk compared with larger margins; despite differences among studies, this meta-analysis clearly indicated that there is no rationale for the routine use of margins of 1 cm or more in patients treated with excision and RT, in particular, taking into consideration that large resections may be associated with a worsening of cosmetic outcome.

Beyond pure figures, it is accepted that conventional pathology specimen analysis is unable to determine the completeness of excision of DCIS; if it could, radiation would have no benefit in breast conservative treatment. Rather, the value of margin status and width is to represent an estimate of likelihood of residual DCIS in the breast. As an association exists between volume of disease near the margin and ipsilateral breast tumor recurrence (IBTR), the clinical importance of volume of disease at the closest margin may serve as an easily measurable variable on routine pathology review to assist in treatment selection in order to estimate the benefit of RT treatment after breast-conserving surgery [30].

A comprehensive assessment of DCIS margins significance is offered by a recent guideline developed from a consensus panel process based on the best available evidence that was recently published [29]: a 2 mm margin minimizes the risk of IBTR compared with smaller negative margins, while more widely clear margins do not significantly further decrease IBTR. Therefore, a 2 mm margin may currently be seen as the standard for an adequate margin in DCIS treated with lumpectomy and RT since it is associated with low rates of IBTR and has the potential to decrease re-excision rates, improve cosmetic outcome, and decrease healthcare costs. On the contrary, clinical judgment should be used in determining the need for further surgery in patients with negative margins less than 2 mm, because other factors known to impact rates of IBTR should be considered in estimating the need for re-excision.

Margin status as a proxy of potential residual disease after surgery results as a basis to make informed decisions about the risk of suffering a potentially life-threatening invasive recurrence by the omission of RT versus the potential risks associated with the use of RT; however, it must still be acknowledged that the magnitude of benefit is greatest in the subgroups with highest risk and, so far, such an individual clear-cut risk estimate is not yet available. While novel molecular markers which capture the large heterogeneity of DCIS and predict the progression from DCIS to invasive breast cancer are developed and translated into clinically applicable predictive biomarkers, the physician and the patient are left with the task of extracting information from an amount of clinical and pathologic variables known to influence risk of IBTR.

Beyond margin status and volume of disease at closest margin, these include, but are not limited to, age, clinical presentation, family history, multifocality, size, and histopathologic features like nuclear grade, presence of necrosis, or architectural pattern.

In order to aid decision-making, in 1995 the Van Nuys Prognostic Index (VNPI) was developed, combining such clinical and pathologic factors, and was later revised including also additional factors, but the unique pathologic processing of the DCIS specimens performed by the authors, as well as the lack of external validation, has hampered vast acceptance of the VNPI into clinical practice.

More recently, a comprehensive nomogram which estimates individual probability of IBTR by incorporating all of the abovementioned factors and their interdependent relationships was developed by Rudloff et al. [30].

The authors combined ten parameters to produce a prediction model that can create an individualized estimate of the risk of local recurrence for women with DCIS treated with breast-conserving surgery; the 5- and 10-year probability of IBTR as predicted by the nomogram showed a high correlation with the observed probability of IBTR as estimated by the Kaplan-Meier method, so the nomogram was pinned down as a tool that can assist clinicians and patients in their decision-making regarding surgical options and adjuvant therapy. Of note, this software included in its development and validation the impact of treatments shift that took place as a consequence of the clinical practice-changing landmark studies that were published in late 1990s [4, 31, 32].

Of course, as always when working with a risk-estimation model, care and clinical acumen must be used in its applications. Still, within this frame, nomograms have been shown in several malignancies to be superior to conventional staging or scoring systems or expert opinion, so, while the true molecular heterogeneity of noninvasive breast cancer is waiting to be fully elucidated, it is our opinion that nomograms may constitute a handy and helpful tool to complement the irreplaceable clinical judgment.

In summary, as far as the problem of recurrence is concerned, evidence-based shared decision-making is to date impossible due to a lack of knowledge about the risk that invasive cancer will develop, and uncertainties actually also extend to other more general aspects of DCIS management such as the likelihood that a DCIS will grow to preclude breast-conserving surgery and the best modality of imaging and time schedule for follow-up.

So far, in routine clinical practice, both clinical and histopathological features of DCIS are commonly used to aid the decision-making process, but with variable evidence to support the relative value of each one.

Young age (<40), high mammographic density, the outset as a symptomatic disease, and the presentation as a large or multifocal disease are clinical features that were associated with an increased risk of DCIS recurrence in the literature. Histopathologically, the same role can be ascribed to the presence of comedonecrosis, high grading, and involved (or less than 2 mm) surgical margins.

In order to gain relevant clinical insight, nomograms may constitute a helpful tool to estimate an individual recurrence risk deriving from the patient-specific combination of the abovementioned features.

Future developments will probably lead to shed some light on the role played by the expression of proteins, such as estrogen receptor, HER2, and cell-cycle markers (Ki-67, p16, p21, p53, COX-2), that have shown promise as prognostic markers in DCIS but still lack a validation in large cohorts and a standardization in methods for their assessment [2].

Also, understanding the role of gene expression profiles, genomic alteration, and epigenetic changes (such as DNA methylation) is the cutting edge of ongoing studies aimed at elucidating the complex biology of DCIS; so far, promising results were obtained from the analysis of the expression of some gene panels (Oncotype DX and MammaPrint) at mRNA level, which was validated in some cohorts [33] as a recurrence predictor but is still under evaluation in order to allow for a more general adoption.

While benefit of complete surgical excision, adjuvant radiotherapy, and tamoxifen in preventing recurrence and invasive progression has been demonstrated in DCIS, spotting the specific disease behavior in order to achieve the best treatment allocation is still challenging. In fact, several difficulties exist because the combination of DCIS prevalence and early detection offers small amounts of fresh tissue available for molecular and nucleic acid yields; in addition, very long follow-up is required as recurrences are infrequent events and may take place more than 10 years after the diagnosis.

As a result of these factors, biomarker studies in DCIS are often only able to investigate a limited number of cases using a small panel of targets and have difficulty achieving sufficient statistical power, so it has been difficult to identify biomarkers in DCIS with better predictive value than traditional clinicopathological features.

Possibly, alternative concepts in DCIS biology will be able to yield more useful prognostic markers in the future; in addition, a more extensive knowledge of both tumor microenvironment and intratumoral genomic heterogeneity [2] will allow to derive meaningful clinical information from laboratory findings.

References

1. Narod SA, Iqbal J, Giannakeas V, Sopik V, Sun P. Breast cancer mortality after a diagnosis of ductal carcinoma in situ. *JAMA Oncol.* 2015;1:888.
2. Pang JMB, Gorringer KL, Fox SB. Ductal carcinoma in situ—update on risk assessment and management. *Histopathology.* 2016;68:96–109.
3. Silverstein MJ. Ductal carcinoma in situ of the breast: a surgeon's disease. *Ann Surg Oncol.* 1999;6(8):802–10.
4. Silverstein MJ, Lagios MD, Groshen S, et al. The influence of margin width on local control of ductal carcinoma in situ of the breast. *N Engl J Med.* 1999;340:1455.
5. Rosner D, Bedwani RN, Vana J, et al. Noninvasive breast carcinoma: results of a national survey by the American College of Surgeons. *Ann Surg.* 1980;192:139.

6. von Rueden DG, Wilson RE. Intraductal carcinoma of the breast. *Surg Gynecol Obstet.* 1984;158:105.
7. Sunshine JA, Moseley HS, Fletcher WS, Krippaehne WW. Breast carcinoma in situ. A retrospective review of 112 cases with a minimum 10 year follow-up. *Am J Surg.* 1985;150:44.
8. Kinne DW, Petrek JA, Osborne MP, et al. Breast carcinoma in situ. *Arch Surg.* 1989;124:33.
9. Silverstein MJ. An argument against routine use of radiotherapy for ductal carcinoma in situ. *Oncology (Williston Park).* 2003;17:1511.
10. Fisher B, Land S, Mamounas E, et al. Prevention of invasive breast cancer in women with ductal carcinoma in situ: an update of the National Surgical Adjuvant Breast and Bowel Project experience. *Semin Oncol.* 2001;28:400.
11. Gao X, Fisher SG, Emami B. Risk of second primary cancer in the contralateral breast in women treated for early-stage breast cancer: a population-based study. *Int J Radiat Oncol Biol Phys.* 2003;56:1038.
12. Tuttle TM, Jarosek S, Habermann EB, et al. Increasing rates of contralateral prophylactic mastectomy among patients with ductal carcinoma in situ. *J Clin Oncol.* 2009;27:1362.
13. Hwang ES. The impact of surgery on ductal carcinoma in situ outcomes: the use of mastectomy. *J Natl Cancer Inst Monogr.* 2010;2010:197.
14. Erbas B, Provenzan E, Armes J, et al. The natural history of ductal carcinoma in situ of the breast: a review. *Breast Cancer Res Treat.* 2006;97(2):135–44.
15. Ozanne EM, Shieh Y, Barnes J, et al. Characterizing the impact of 25 years of DCIS treatment. *Breast Cancer Res Treat.* 2011;129(1):165–73.
16. Sackey H, Hui M, Czene K, Verkooijen H, Edgren G, Frisell J, Hartman M. *Breast Cancer Res.* 2016;18:105.
17. Arvold ND, Punglia RS, Hughes ME, Jiang W, Edge SB, Javid SH, Laronga C, Niland JC, Theriault RL, Weeks JC, Wong YN, Lee SJ, Hassett MJ. Pathologic characteristics of second breast cancers after breast conservation for ductal carcinoma in situ. *Cancer.* 2012;118(24):6022–30.
18. Waldman FM, DeVries S, Chew KL, et al. Chromosomal alterations in ductal carcinoma in situ and their in situ recurrences. *J Natl Cancer Inst.* 2000;92:313–20.
19. Sanger N, Effenberger KE, Riethdorf S, Van Haasteren V, Gauwerky J, Wiegratz I, Strebhardt K, Kaufmann M, Pantel K. Disseminated tumor cells in the bone marrow of patients with ductal carcinoma in situ. *Int J Cancer.* 2011;129:2522–6.
20. Esserman L, Yau C. Rethinking the standard for ductal carcinoma in situ treatment. *JAMA Oncol.* 2015;1(7):881–3.
21. Ernster VL, Barclay J, Kerlikowske K, Wilkie H, Ballard-Barbash R. Mortality among women with ductal carcinoma in situ of the breast in the population-based surveillance, epidemiology and end results program. *Arch Intern Med.* 2000;160(7):953–8.
22. Donker M, Litiere S, Werutsky G, et al. Breast-conserving treatment with or without radiotherapy in ductal carcinoma in situ: 15-year recurrence rates and outcome after a recurrence, from the EORTC 10853 randomized phase III trial. *J Clin Oncol.* 2013;31(32):4054–9.
23. Warnberg F, Bergh J, Zack M, Holmberg L. Risk factors for subsequent invasive breast cancer and breast cancer death after ductal carcinoma in situ: a population-based case-control study in Sweden. *Cancer Epidemiol Biomark Prev.* 2001;10(5):495–9.
24. Warnberg F, Garmo H, Emdin S, et al. Effect of radiotherapy after breast-conserving surgery for ductal carcinoma in situ: 20 years follow-up in the randomized SweDCIS trial. *J Clin Oncol.* 2014;32(32):3613–8.
25. Correa C, McGale P, Taylor C, et al. Earlybreast Cancer Trialists' Collaborative Group (EBCTCG). Overview of the randomized trials of radiotherapy in ductal carcinoma in situ of the breast. *J Natl Cancer Inst Monogr.* 2010;2010(41):162–77.
26. Roses RE, Arun BK, Lari SA, et al. Ductal carcinoma-in-situ of the breast with subsequent distant metastasis and death. *Ann Surg Oncol.* 2011;18(10):2873–8.
27. American Cancer Society. Lifetime risk of developing or dying from cancer. Last revised: 23 March 2016. <http://www.cancer.org/cancer/cancerbasics/lifetime-probability-of-developing-or-dying-from-cancer>. Accessed 15 Nov 2016.

28. Wang SY, Shamliyan T, Virnig BA, Kane R. Tumor characteristics as predictors of local recurrence after treatment of ductal carcinoma in situ: a meta-analysis. *Breast Cancer Res Treat.* 2011;127:1–14.
29. Dunne C, Burke JP, Morrow M, Kell MR. Effect of margin status on local recurrence after breast conservation and radiation therapy for ductal carcinoma in situ. *J Clin Oncol.* 2009;27:1615–20.
30. Rudloff U, Jacks LM, Goldberg JI, Wynveen CA, Brogi E, Patil S, Van Zee KJ. Nomogram for predicting the risk of local recurrence after breast-conserving surgery for ductal carcinoma in situ. *J Clin Oncol.* 2010;28:3762–9.
31. Fisher B, Dignam J, Wolmark N, et al. Tamoxifen in treatment of intraductal breast cancer: National Surgical Adjuvant Breast and Bowel Project B-24 randomised controlled trial. *Lancet.* 1999;353:1993–2000.
32. Fisher B, Dignam J, Wolmark N, et al. Lumpectomy and radiation therapy for the treatment of intraductal breast cancer: findings from National Surgical Adjuvant Breast and Bowel Project B-17. *J Clin Oncol.* 1998;16:441–52.
33. Solin LJ, Gray R, Baehner FL, et al. A multigene expression assay to predict local recurrence risk for ductal carcinoma in situ of the breast. *J Natl Cancer Inst.* 2013;105:701–10.

Alfonso M. Pluchinotta and Xenia Raspanti

Clinical Points

- Multivariate aspects of diagnosis and treatment of DCIS may cause in the woman confounding thoughts about its nature and conflicting decisions about the right treatment.
- Given the complexity of DCIS, the first communicative approach should be, namely, educational.
- In the diagnostic assessment, the lack of certainty and the need of additional investigation could cause the first failure of any effective communication.
- Where delay may arise, in order to reduce anxiety, a definite timetable should be set for each step of the process in terms of working days.
- Communication is only as good as the message received. Misinformation is as damaging to the psyche as no information at all.

13.1 Overview

For a woman with DCIS, the search for the *right* treatment may be a difficult journey through the medical system as regards the multivariate elements of the diagnosis as well of the treatment. In 1991 Melvin Silverstein, one of the greater researchers of DCIS, wrote these—still valid today—lines:

Her agony came from the fact that mastectomy would be curative and it was hard to turn that down. A lesser procedure, while preserving her breast and her femininity, offered her somewhat less chance for a complete cure—but exactly how much less was unknown.

A.M. Pluchinotta (✉)
Breast Surgery, Policlinic of Abano Terme, Padova, Italy
e-mail: pluchinotta.alfonso@gmail.com

X. Raspanti
Department of Radiology, Policlinic of Abano Terme, Padova, Italy

Perhaps only a small amount less. It didn't seem worth losing her breast for a few percentage points. Yet, maybe it was. It was the most difficult decision of her life. But medicine had failed her. The data upon which to base her judgment was weak, and we had shifted the burden of that judgment to her. [1]

Today we know a great deal more about DCIS, but it is still questionable whether the decision-making process is some easier. In the meanwhile a number of *right* treatments are flawed in some way with the result, even today, of confounding her thoughts and making her decision more difficult.

Is DCIS really a cancer? It is never easy to tell a patient that she has BC, and a number of questionable topics should be taken into account. A common understanding has been reached on the following statements.

- From a biologic point of view, DCIS is definitely a cancer.
- From a prognostic point of view, DCIS has, as a whole, a favorable but uncertain attitude.
- Surgical approach of DCIS is not commensurate with its gravity but with its extension.
- Radiotherapy is strongly recommended, though it may not always be necessary.

How DCIS can be perceived? A diagnosis of DCIS can provoke substantial psychological distress, partly because of the apparent ambiguity of having no manifest tumor but possibly having a very early form of BC that needs treatment. Generally perceptions about the risks of recurrence, metastasis, and death are the same as those of woman with early invasive BC. Moreover, also in case of very favorable DCIS, these perceptions are stronger in patients who believe they are at high risk due to familiarity. Even lack of full scientific certainty becomes a medical weakness in the management or control of the disease or nothing more than a way to concealing the truth.

Can the word cancer be replaced? In the population, the word *cancer* evokes the spectre of an inexorably lethal process. However, cancers are heterogeneous and include also indolent disease that causes no harm during the patient's lifetime, and better biology alone can explain better outcomes. Therefore, some clinicians suggested the use of the term *cancer* only for describing lesions with a reasonable likelihood of lethal progression if left untreated, while for some conditions like DCIS, the word *cancer* should not be in the name of diagnosis. However, the above implementation has many obstacles.

- Suggested changes may be a prescription for nosological confusion.
- Cancer is not a singular entity, it is not binary as suggested, and its aspects are highly heterogeneous and dynamic, reflecting a *continuum* of characteristic biological features that may change over time.
- The psychological consequences of changing the diagnosis for millions of people who already see themselves as cancer survivors are uncontainable. For better or worse, cancer is no longer just a diagnosis; it is an identity.

- Moreover, telling a woman who underwent surgery and years of hormone therapy for DCIS endured these treatments not for cancer but for an indolent lesion of epithelial origin may invalidate her experience.

It can be expected that even legal, insurance, psychological concerns will fail to correct this problem in the future. Just in case of molecular diagnostic tools that identify indolent or low-risk lesions were adopted and validated, it may be possible to reclassify such cancers as IDLE (InDolent Lesions of Epithelial origin) and to remove the word cancer.

The first approach should be educational. Even if the patient does not think of *breast cancer* as an inexorable disease, clinicians need (Fig. 13.1):

- To educate her that the term cancer encompasses a multitude of lesions of varying degrees of aggressiveness and lethal potential, but that is certainly not the case with DCIS, even if DCIS too has multivariate aspects.
- To emphasize to the patient that she has a *preinvasive* cancerous lesion, which at this time is not a threat to her life.
- To deal with the fear that the cancer has spread, having the ability to assure patient with DCIS that if no invasion was seen microscopically, the likelihood of systemic spread is essentially zero.
- The likelihood of local recurrence is more unpredictable but it may be kept under control.

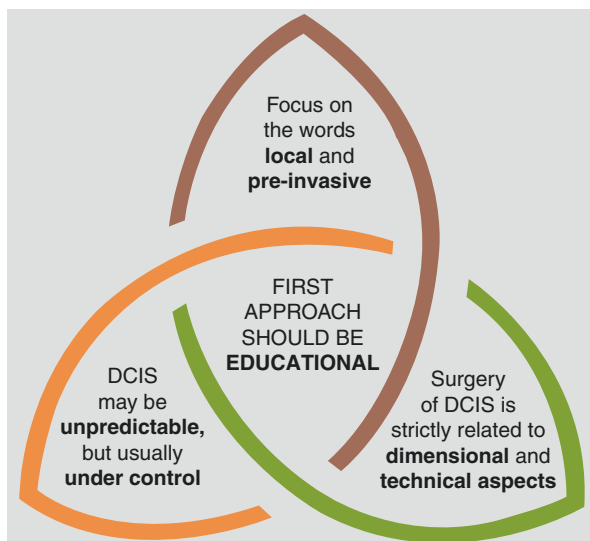


Fig. 13.1 Educational approach to DCIS

13.2 A Radiological Finding

The suspicion of a DCIS is mainly radiological, and much of it depends on the fulfillment of the diagnostic process before the counseling. Two types of stress may be noticeable. The first is the failure to reach at once a definitive diagnosis due to the need of additional investigations. The second stress is related to the length of an unavoidable delay.

13.2.1 The Need of Additional Investigations

Patients who have an equivocal result or require repeats should have a face-to-face consultation to clearly discuss the need for further tests and possible outcomes and a simple care plan put together. Believe it or not, the need of additional investigation is the first and most common cause of the failure of efficient communication between the diagnostic team and the woman. The forces encountered here are the unexpected present and the unpredictable future. Factors to be taken into consideration are predictability and prudence.

Predictability. In most cases, clinicians should not postpone counseling to the definitive results but prepare woman to the most likely outcome, within a reasonable range of lesions. On the other hand, it is well known they are able to intuitively consider all factors at all times, even while they are seeing the patient and formulating diagnostic hypothesis. This “reflection during action” is the process the doctor uses when dealing with specific, unique, uncertain, and complex situations. These are situations where knowledge is the major requisite, but also skills and attitudes, which make of medicine an art.

Prudence should have a big part in the above process. It refers mainly to subjective “physician-centered” knowledge and experience to make a medical diagnosis and devise a treatment plan. However, another component should be “patient-centered” and define the factors related to patient’s psychology and sociology. For someone, this component is better called humanity but more simply is a professional duty.

13.2.2 The Length of Delay

At the slightest suspect of cancer, some women live the doubt as if the diagnosis were certain, and delays at any stage of the diagnostic process may result in anxiety for the woman, which sometimes may be considerable.

Where delay may arise, a definite timetable should be set for each step of the process in terms of working days (w.d.). According to Eusoma [2], quality assurance in the diagnosis of breast disease is guaranteed by the realization of the following indicators:

- Minimum standard for delay between mammography and result: 5 w.d. or less.
- Delay between result of imaging and offered assessment minimum standard: 5 w.d. or less.

- Delay between assessment and issuing of results minimum standard: 5 w.d. or less.
- Delay between decision to operate and date offered for surgery minimum standard: 15 w.d. or less, ideally 7–10 w.d.
- Moreover, 95% of women should receive full and adequate assessment in three appointments or less.
- Ninety percent of women with symptoms and signs strongly suggesting the presence of any kind of cancer should be seen within 2 weeks of referral, and agreed protocols should be in place to facilitate this.

Besides time frames, the radiologist should be present in the clinic at the time when a woman has her mammogram so that any necessary further investigation (e.g., magnification or spot compression views, ultrasound examination) can be performed without delay. As far as possible, the woman should be informed of the result of her examination before she leaves the clinic and of the need for any necessary further investigation to be performed.

For patients who undergo needle biopsy, both written and verbal information should be provided. All patients who undergo needle biopsy should be provided with a definite appointment or other agreed arrangement for communication of the biopsy result, within 5 working days, so they can arrange to be accompanied by family/friend if they wish.

The failure of the assessment process to make a definitive diagnosis of either a benign or a malignant condition is an undesirable outcome of assessment and further increases anxiety. For this reason, the use of early recall for a repeat examination at a time shorter than that normally specified for a routine follow-up is to be avoided.

Women must be informed of time limit to expect results and should be provided with written information at appropriate stages in the diagnostic procedure. However, information regarding the likelihood of malignancy being present should not be given via telephone or letter. Such information should be given verbally to the woman, preferably in the presence of a relative or a nurse counselor.

Many feel that radiologist should provide the woman diagnostic details of the assessment. Obviously information, upon which the following decisions are based, should have consistent evidence shared by other members of the team. It is just information, while definitive conclusions should be postponed to the final stage and drawn by the multidisciplinary team (MDT).

13.3 A Proven Diagnosis of DCIS

Communication has been defined an extraordinary opportunity, a key clinician skill, a basic need, and a fundamental aspect of care. Moreover, for the clinicians communication opportunities and skills are associated with less burnout and work-related stress. Despite these mutual advantages, most physicians have little training in communication and little interest to improve it. Just because communication in

DCIS is multifaceted, it is therefore more rewarding. Clinicians may also maintain their doubts but have a chance to demonstrate how to move inside them. Ultimately, in oncological cases, the aspects of communication most valued by patients are those that help patients and their families feel guided, build trust, and support hope.

Communicating the diagnosis takes time, and it should be ensured that sufficient time and support is provided for this. Moreover, the patient should be given their results possibly in the presence of a breast care nurse and any relative/carer/friend that they wish to have at the consultation.

Lines of behavior toward woman with histologically proven diagnosis of DCIS are:

- Assure that she has a minimal less common lesion, not comparable with nodular ones.
- Point out that the kind of surgery, thought limited, is related to technical matters.
- Inform that she is likely going to need some additional treatment, which may include surgery, radiation therapy, hormonal tablets, or some combination.
- Reassure that treatments do not include chemotherapy, that her hair will not fall out, and that it is highly unlikely that she will die from this lesion.
- Point out that a careful clinical follow-up will be required.

As in any medical counseling essentials are: treat the patient as a unique person; address her formally; make eye contact with him/her. It is important to show respect but also to tighten a therapeutic alliance founded on transparency, empathy, trust, and kindness. Sometimes conflicting or undesirable results need to be given by an appropriately trained senior clinician who has experience and training in breaking bad news.

It is worthwhile to remember that communication, even if real, has a strong individual component since it is 20% what the doctor knows and 80% how they feel about what they know. Moreover, communication is very little based on words; tone of voice and body language account for much more. The communication of the distinctive features of the DCIS is very difficult, and it is not always about being proper but it is about being effective. Finally, effective communication is only as good as the message received (Fig. 13.2).

Different people have different needs for information, and these may change with the many facets of DCIS. Some women find that gathering information helps them cope with their diagnosis and treatment. Much information is now available to patients, and many resources are directed at trying to prevent or ameliorate psychological stress. Guiding patients to well-established websites (to select previously) and information resource centers might ameliorate anxiety. However, this may entail a significant hazard in case of misinformation, as damaging to the psyche as no information at all.

Communication should be developed in order for the patient to comprehend and agree. Sometimes words can be as hard as stones, and each caregiver should therefore calibrate their speech to avoid confusion, anxiety, fear, or depression.

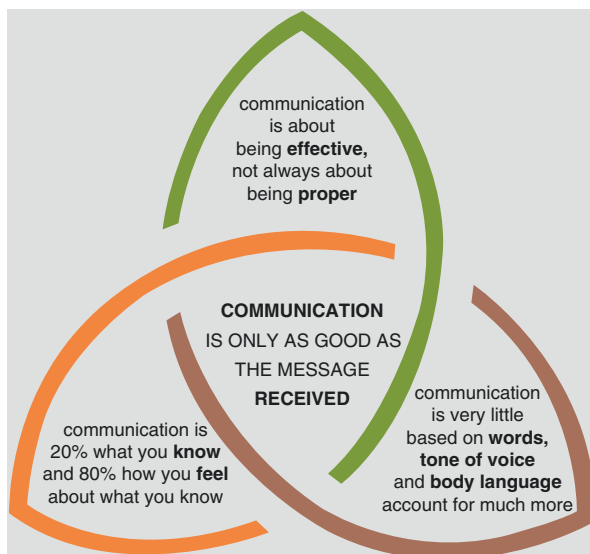


Fig. 13.2 Some facts about effective communication [3]

For this reason, communication should also take account of a large number of verbal faux pas that some women are not willing to tolerate. Among the several behaviors to avoid include blocking, lecturing, collusion, and premature imprudent reassurance [4].

- *Blocking* occurs when a patient raises a concern but the physician either fails to respond or redirects the conversation. For example, a woman with BC might ask, “How long do you think I have?” To which the doctor responds, “Don’t worry about that.” It is important to recognize the mechanisms related to blocking because they are the reasons why the physician typically fails to elicit the range of patient concerns and consequently is unable to address the most important ones.
- *Lecturing* occurs when a physician delivers a large chunk of information without giving the patient a chance to respond or ask questions.
- *Collusion* occurs when patient hesitates to bring up difficult topics and the physician does not ask her directly—a *don’t ask, don’t tell* situation.
- *Premature (imprudent) reassurance* occurs when physician responds to patient concern with reassurance before exploring and understanding the concern.

On the contrary, virtuous behaviors to cultivate are also a number. Some of these:

- *Ask-tell-ask*. Always ask about the patient’s understanding of the issue. *How do you see your health?* Tell the patient in straightforward language what you need to communicate—the bad news, treatment options, or other information. Stop short of giving a long lecture or huge amounts of detail. Information should be

provided in short, digestible chunks. A useful rule of thumb is not to give more than three pieces of information at a time. Do not use medical jargon. Ask the patient if she understood what was said. In few cases and without any pressure, consider asking the patient to restate what was said in her own words.

- *Tell me more.* Ask the patient if they need more information or if all their questions are being answered. Ask about how they feel about what has emerged and its meaning.
- *Respond to emotions.* Approaching the person with kindness is key to helping. However, in cases of problematic relationships, covering emotional responses involves naming, understanding, respecting, supporting, and exploring the emotional response and consequently the need for nursing or psychological support.

Some women are more demanding. In the belief they are at high risk of invasive BC, they may continue to feel distressed also following a diagnosis of very favorable DCIS. It is important to precisely, and sometimes again and again, address these (mis) perceptions at the initial consultation. On the contrary, some women do not ask for clarifications for many reasons: are afraid or ashamed of their ignorance; are fearful of being pushy, ill-timed; are afraid for wasting health workers' time; and wish to remain in denial because the reality is painful to face. *Good doctors have to try to hear the silent ones*, according to one line by Paul Celan. Everyone praises the silent ones for their reserve, but their inscrutability may conceal deep thinking, a seal of superiority, and even a psychological block. Every woman is a person who is fighting a battle you too know little about. Do not make believe to know the unknown, and be respectful and kind is mandatory.

References

1. Silverstein MJ. Intraductal breast carcinoma. Two decades of progress? *Am J Clin Oncol.* 1991;14:534–7.
2. Perry NM. Quality assurance in the diagnosis of breast disease. EUSOMA Working Party. *Eur J Cancer.* 2001;37:159–72.
3. Macellari G, Pluchinotta AM. Breast clinic. In: Pluchinotta AM, editor. *The outpatient breast clinic: aiming at best practice.* Springer: Heidelberg; 2015. p. 1–29.
4. Singletary SE. Mentoring surgeons for the 21st century. *Ann Surg Oncol.* 2005;12:848–60.

Index

A

- ABBI cannula, 67, 68
- Acellular dermal matrix, 147, 149
- Adjuvant systemic therapy
 - anastrozole, 190
 - aromatase inhibitors, 188
 - endocrine therapy, 185, 188
 - exemestane, 190
 - radiation therapy, 186
 - SERM, 190, 191
 - tamoxifen
 - in arms, 187, 188
 - contralateral recurrence, 186
 - ER expression, 186, 187
 - invasive ipsilateral breast, 188
 - invasive tumor recurrence, 185, 186
 - mortality, 186
 - recurrence rate reduction, 186
 - surgery alone, 188, 189
- American College of Radiology 2015, 164
- American Society for Clinical Oncology (ASCO), 164, 188
- American Society for Radiation Oncology (ASTRO), 180
- Anamnesis, 108, 109
- Anastrozole, 190
- Areola-sparing mastectomy, 131
- Atypical ductal hyperplasia (ADH), 15, 18, 62, 81, 83, 84, 190
- Atypical hyperplasia, 4, 5, 18, 19
- Augmentation mastoplasty, 152
- Axillary lymph node dissection (ALND), 158, 160–163, 165, 166

B

- Batwing mastopexy, 121, 123
- Benelli's operation, 126–127
- Biological time, 1, 3, 4, 19

- Biomarkers, 72
- Body mass index (BMI), 30
- Boissonnat's technique, 13
- Breast imaging reporting and data system (BIRADS), 47–50, 62–64, 71
- Breast and prostate cancer cohort consortium (BPC3), 28
- Breast cancer surveillance consortium, 25
- Breast conservation surgery (BCS), 27, 107, 130, 133
- Breast irradiation
 - age factor, 175
 - boost irradiation, 179
 - clinical risk factors, 174
 - EORTC 10853 trial, 172
 - four randomized trials, 172
 - histopathological risk factors
 - margins, 175, 176
 - nuclear grade, 175
 - tumor size, 175
 - hypofractionation, 179, 180
 - IMRT, 180
 - low risk of recurrence identification, 176–179
 - postoperative radiotherapy, 174
 - radiotherapy, 172
 - recommended dose, 179
 - SweDCIS trial, 173
 - tamoxifen and, 173
 - 3D CRT, 180
 - UK/ANZ DCIS trial, 173
- Breast reconstruction
 - autologous tissue reconstruction
 - LDM flap, 149, 150
 - myocutaneous flap, 149
 - TRAM flap, 150, 151
 - breast remodeling, 144
 - contralateral breast management, 152, 153
 - free dermal fat graft, 144, 145

- immediate vs. delayed reconstruction, 154, 155
 implant based
 contraindications, 146
 nipple-sparing mastectomy, 146, 147
 skin-sparing mastectomy, 146
 tissue expanders, 146–148
 two-stage approach, 148
 lipofilling, 153, 154
 nipple-areola complex reconstruction, 149, 151, 152
 radiation therapy and, 154
 Breast-conserving therapy (BCT), 109, 164, 194
- C**
- Cancer Registry of Norway, 25
 Circadian rhythm disruption, 3
 Classical microscopy, 2
 Clips, on tumor beds, 121
 Cochrane Database of Systematic Reviews, 174
 Comedo-necrosis, 77, 81, 82
 Comparative effectiveness of MR imaging in breast cancer (COMICE), 46
 Contralateral breast management, 152, 153
 Cooper's text, 12, 14
 Core needle biopsy, 40, 53, 62, 159, 164
 Counseling woman, DCIS
 communication
 ask-tell-ask, 209
 blocking, 209
 collusion, 209
 effective, 208, 209
 essentials of, 208
 lecturing, 209
 lines of behavior, 208
 responding to emotions, 210
 tell me more, 210
 educational approach, 205
 implementation, 204, 205
 perception, 204
 radiological finding
 delay length, 206, 207
 predictability, 206
 prudence, 206
 understanding DCIS, 204
 Cribriform growth pattern, 76, 82
 Crushed stone and casting type, 174
- D**
- Dana-Farber Cancer Institute, 176
 DCIS Score, 83, 84
 Deep inferior epigastric perforator (DIEP), 151
 DEGRO practical guidelines, 177
 Delayed breast reconstruction, 155
 Diffuse DCIS, 16, 17
 Digital mammography, 65
 Ductal intraepithelial neoplasia (DIN), 81
 Ducts and glandules, 11, 12
- E**
- Early Breast Cancer Trialists' Collaborative Group (EBCTCG), 174, 196
 Eastern Cooperative Oncology Group (ECOG), 31, 176, 177
 E-cadherin, 78, 84
 Effective communication, 208, 209
 EMI-batwing mastopexy, 121, 124
 Endocrine therapy (ET), 185, 188
 EORTC 10853 trial, 172, 174, 175
 Epidemiology
 diagnosis, 25, 27
 incidence, 24
 mammography screening, 25, 26
 race, ethnicity and age, 25
 Exemestane, 190
 Extracellular matrix (ECM), 3–6
- F**
- Free dermal fat graft, 144, 145
 French Bonbis trial, 180
 French Regional Cancer Center, 176
 Further prospectives, 84
- G**
- Galactograms, 13
 Genetically abnormal tissue, 3
 Genomic technology, 84
 Grisotti flap, 128
 Grisotti's flap, 126
 Groupe Européen de Curiothérapie–European Society for Radiotherapy and Oncology (GEC-ESTRO), 180
- H**
- Hereditary breast and ovarian cancer syndrome, 109
 High-grade DCIS, 6, 17, 25, 26, 28, 49, 50, 78, 81–84, 158, 160, 174, 176, 177, 179, 194

Histological classification, 75, 76
 Horizontal Mammoplasty. *See* Batwing mastopexy
 Hormone replacement therapy (HRT), 24, 30
 Hypofractionation, 179, 180

I

Imaging
 magnetic resonance
 kinetic patterns, 49
 morphologic features, 46–48
 sensitivity, 45, 46
 mamographic screening, 40–44
 ultrasonographic features
 calcified DCIS, 50–51
 diagnosis at MR imaging, 53
 noncalcified DCIS, 51–53
 Immediate breast reconstruction, 154
 InDolent Lesions of Epithelial origin (IDLE), 205
 Inferior pedicle mammoplasty (IPM), 117, 118
 Intensity-modulated radiotherapy (IMRT), 180
 Interventional diagnosis, 58, 61
 applications, 57
 FNAC (*see* Percutaneous cytology)
 PB (*see* Percutaneous biopsy (PB))
 Intraoperative margin definition, 111
 Intraoperative ultrasound (IOUS), 99, 100
 Invasive cancer, 25, 27, 28
 Ipsilateral breast tumor recurrence (IBTR), 197, 198

J

J-mammoplasty, 121, 122

K

Kaplan-Meier method, 187, 198
 Ki67, 28, 72, 83
 Kijima technique, 144, 145

L

Large-scale anatomy, 2
 Lateral mammoplasty, 121, 125, (*see* Racquet technique)
 Latissimus dorsi myocutaneous (LDM) flap, 149, 150
 Lipofilling, 153, 154
 Low-grade DCIS, 6, 78
 Lumpectomy, 114, 172, 174, 194

M

Magnetic resonance (MR)-guided breast biopsy, 70, 71
 Malignant progenitor cells, 5
 MAMMOTOME system, 67
 Margin status, 196–198
 MarginProbe®, 112
 Mastopexy, 153
 Matrix metalloproteinase 2 (MMP2), 81
 Memorial Sloan Kettering Cancer Center, 178
 MicroRNA (miRNA), 84
 Million Women Study, 28
 Molecular assessment, 84
 Molecular markers, 166
 Multicentric DCIS, 16, 17
 Multifocal DCIS, 16, 17
 Multigene reverse transcriptase (RT)-PCR assay, 83
 Myocutaneous flaps, 149
 Myoepithelial cells, 4–6

N

NABON 2012 Version 2.0, 164, 165
 National Comprehensive Cancer Network (NCCN), 82
 National Comprehensive Cancer Network Outcomes Database, 194
 National Health Service Breast Screening Program (NHSBSP), 23
 National Surgical Adjuvant Breast and Bowel Project (NSABP), 82, 158, 185, 186, 190
 Natural history
 animal models, 10
 autopsy studies, 9
 DCIS misdiagnosed as benign, 9
 mathematical models, 10
 recurrence of DCIS, 9
 Needle biopsy, 207
 Next-generation sequencing (NGS) modalities, 84–85
 NHS breast screening programme, 72
 NICE 2009, 165
 Nipple-areola complex reconstruction, 149, 151, 152
 Nipple-sparing mastectomy (NSM), 146, 147
 breast innervation, 132
 breast surgical anatomy, 131, 132
 breast vascular anatomy, 132
 complications, 137, 138
 demolition time, 134, 135
 indications and contraindications, 133
 planning for surgery, 133, 134

- skin incision, 134, 135
 - subareolar biopsy, 136, 137
 - Nomogram, 198, 199
 - Non-palpable lesion localization
 - ROLL technique
 - indications, 96
 - intratumoral injection under US, 95, 96
 - ultrasound-guided surgery, 99
 - WGL
 - indications, 92
 - procedure, 92
 - surgical procedure, 93–95
 - North American Association of Central Cancer Registries (NAACCR), 24, 26
 - NSABP B-17 trial, 172, 175, 177
- O**
- Oncoplastic surgery (OPS)
 - Batwing mastopexy, 121, 123
 - Clough classification, 116, 117
 - EMI-Batwing mastopexy, 121, 124
 - Grisotti flap, 126, 128
 - IPM, 117, 118
 - J-mammoplasty, 121, 122
 - lateral mammoplasty, 121, 125
 - round-block technique, 126
 - superior pedicle mammoplasty, 117, 119
 - V-mammoplasty, 117, 120
 - White classification, 116
 - Yang's classification, 114, 116
 - Oncotype DX breast cancer assay, 83
 - Outcomes, DCIS lesion
 - with prolonged intraductal phase, 7, 8
 - regressive DCIS, 8
 - with short intraductal phase, 7, 8
- P**
- Partial-breast irradiation (PBI), 180
 - Pathological definition, 75, 193
 - Percutaneous biopsy (PB), 65–68, 70
 - assessment, 62
 - limitations, 62
 - medical reporting, 72
 - MR-guided breast biopsy, 70, 71
 - primary evaluation, 63
 - procedure, 61, 65
 - sample handling for pathologist, 71
 - stereotactic breast biopsy
 - ABBI system, 67, 68
 - gauges and, 67, 70
 - MAMMOTOME system, 67
 - procedure, 65
 - stereotactic table, 65–67
 - types, 61
 - US breast biopsy, 63, 64
 - Percutaneous cytology
 - collection technique, 59, 60
 - complications, 59
 - diagnostic conclusions, 60
 - false negatives, 58
 - indications, 60, 61
 - positive cytology, 58
 - stereotactic imaging, 58
 - Pluripotent malignant progenitor cell, 6
 - Pneumothorax, 59
 - Post-lactational settlement, 8
 - Primary systemic therapy (PST), 71
 - Progenitor cells, 5
 - Prognostic markers, 81–84
 - Progression, of DCIS, 78
- R**
- Radical mastectomies, 131
 - Radioactive seed localization (RSL), 98, 99
 - Recurrence, DCIS
 - BCT, 194
 - biomarker studies, 199
 - contralateral, 194
 - early treatment, 195
 - gene expression, 199
 - IBTR, 197, 198
 - invasive cancer, 194–199
 - ipsilateral invasive, 194, 195
 - margin status, 196–198
 - mastectomy, 194–196
 - mortality, 195
 - protein expression, 199
 - tumor cells in bone marrow, 195
 - Reduction mastoplasty, 153
 - Regressive DCIS, 8
 - Risk factors
 - age, 28
 - breast tissue density, 31
 - dietary factors, 30, 31
 - drugs, 31
 - ethnicity, 29
 - family history, 27
 - genetic risk assessment, 28
 - HRT, 30
 - metabolic factors, 30
 - reproductive factors, 30
 - subsequent breast cancer, 31
 - ROLL technique
 - indications, 96
 - intratumoral injection under US, 95, 96

- surgical procedure, 96–98
 - vs. WGL, 101
 - Round-block technique, 126, 129
 - Routine diagnostic approach, 16
 - RTOG 9804 trial, 177
- S**
- Segmental-peripheral-lobar-multilobar, 16
 - Selective estrogen receptor modulator (SERM), 185, 190, 191
 - Semiautomatic needle, 63
 - Sentinel lymph node biopsy (SLNB), 194
 - vs. ALND, 165, 166
 - American College of Radiology 2015, 164
 - ASCO Clinical Practice Guideline Update 2014, 164
 - high-risk DCIS, 159–160
 - lumpectomy, 163
 - mastectomy, 163
 - NABON 2012 Version 2.0, 164, 165
 - NICE 2009, 165
 - quadrantectomy, 163
 - role in DCIS, 161–163
 - significance of, 161
 - tracer migration, 166
 - Sick lobe theory (SLT), 1, 3, 4, 14–16
 - Skin-reducing mastectomy (SRM), 138, 140
 - Skin-sparing mastectomy, 145, 146
 - Skin-sparing mastectomy (SSM), 138, 139
 - Snap needle, 63
 - Sojourn time, 3
 - Stem cells, 7
 - Stereotactic breast biopsy, 111
 - ABBI system, 67
 - gauges and, 67, 70
 - MAMMOTOME system, 67
 - procedure, 65
 - stereotactic table, 65–67
 - Stromal environment, 3
 - Superior pedicle mammoplasty, 117, 119
 - Surgical treatment evolution
 - anamnesis, 108, 109
 - conservative surgery, 114
 - BCS, 130
 - lumpectomy, 114
 - OPS (*see* Oncoplastic surgery (OPS))
 - traditional quadrantectomy, 114, 115
 - core biopsy, 111
 - intraoperative margin definition, 111
 - macroscopic examination, 112
 - microscopic examination, 111
 - optical properties, 112
 - radiofrequency, 112
 - X-ray, 112
 - non-palpable lesion localization, 111
 - NSM
 - breast innervation, 132
 - breast surgical anatomy, 131, 132
 - breast vascular anatomy, 132
 - complications, 137, 138
 - demolition time, 134, 135
 - indications and contraindications, 133
 - planning for surgery, 133, 134
 - skin incision, 134, 135
 - subareolar biopsy, 135–137
 - physical examination
 - breast ptosis, 109
 - breast volume, 109
 - radical mastectomies, 131
 - radiology
 - mammography, 110
 - nuclear magnetic resonance, 110
 - ultrasound, 110
 - SRM, 138, 140
 - SSM, 138, 139
 - Surrogate molecular subtypes, 83
 - Surveillance, epidemiology, and end results (SEER), 23, 195
 - SweDCIS trial, 172, 173, 175
- T**
- Tamoxifen (TMX), 185–190
 - Terminal ductal-lobular unit (TDLU), 11
 - 3D anatomy, 2
 - 3D conformal radiotherapy (3D CRT), 180
 - Time sensitivity, 3, 4
 - Timing
 - asynchronous multicentricity, 19
 - asynchronous multifocality, 19
 - progression of benign lesions, 18
 - synchronous multicentricity, 19
 - synchronous multifocality, 19
 - Tissue expander, 146–148, 154
 - TP53 mutation, 83
 - Traditional definition, DCIS, 193
 - Traditional quadrantectomy, 114, 115
 - Transverse rectus abdominis myocutaneous (TRAM) flap, 150, 151
 - Tru-cut needle, 63, 64
- U**
- UK/ANZ DCIS trial, 172, 173, 186
 - Unifocal DCIS, 16, 17
 - Unifocal-multifocal-diffuse-multicentric patterns, 16

V

Vacuum-assisted biopsy (VAB), 62, 64, 158, 162

Van Nuys prognostic scoring index (VNPI), 177, 178

V-mammoplasty, 117, 120

indications, 92

procedure, 92

vs. ROLL technique, 101

surgical procedure

incision placement, 94

radiograph of specimen, 94, 95

Women's health initiative (WHI), 30

W

Wire-guided localization (WGL), 94, 95
disadvantages, 92