



# Management of Nipple Discharge

NIPPLE ASPIRATE FLUID IN THE  
NONLACTATING BREAST  
ABNORMAL DISCHARGE OF THE  
NIPPLE  
Endocrine Causes of Nipple  
Discharge  
Breast Conditions Causing  
Nipple Discharge

CLINICAL EVALUATION OF THE  
PATIENT WITH NIPPLE  
DISCHARGE  
Ductal Lavage and Ductoscopy  
DUCT EXCISION

## Management of Nipple Discharge: Key Points

- Understand the differences between normal and abnormal discharges from the nipple.
- Describe the features of nipple discharge that raise concern for malignancy.
- Describe the thorough history and examination of the woman with nipple discharge.
- Develop an algorithm for the diagnostic workup of the woman with abnormal nipple discharge.
- Describe how a duct excision is performed and when it is indicated.



After breast pain and a breast mass, nipple discharge is the third most common complaint related to the breast for which women seek medical attention. Approximately 5% to 7% of women referred to breast clinics have symptomatic nipple discharge. Although this may be a highly concerning symptom for women, it is very rarely a sign of malignancy. More than

half of women in their reproductive years are able to express some fluid from the nipple. The overwhelming majority of women with symptomatic nipple discharge have underlying benign disease. Only a very small percentage of women with nipple discharge are found to have an underlying malignancy. Nipple discharge is present in roughly 10% to 15% of women with

benign breast disease. It is very rare for cancer to present only as nipple discharge (less than 1% to 2% of cancers). If nipple discharge is associated with cancer, there is most often an associated mass on physical examination or mammography. The dilemma of the clinician is to determine which patients with nipple discharge can be safely observed, and which require further evaluation and what that evaluation should consist of.

### *Nipple Aspirate Fluid in the Nonlactating Breast*

As stated, most women in the reproductive years can express some fluid from their nipples and this is normal. The breast is a modified apocrine gland whose ultimate function is lactation. However, the nonlactating breast does have secretory activity. This is not clinically appreciated by patients because the lactiferous sinuses are often plugged by keratotic material. However, if the plugs are removed and the nipples aspirated, fluid can be obtained in a large majority of women. Some investigators have thought that this nipple aspirate fluid (NAF) could potentially be used to diagnose breast cancer at an early stage or to assess an individual woman's risk of breast cancer.

NAF varies in color and consistency depending on its composition. The color can range from clear to black, with descriptions of yellow, dark yellow, tan, brown, or green discharge being common. Nipple discharge can also be red or maroon if blood is present, or white if the discharge is milk or infectious. NAF is a secretion of both endogenous and exogenous substances (Box 5-1). In comparing the serum levels of these exogenous substances to the levels in NAF, it is evident that the breast is a true secretory organ. It is possible that the increased concentrations of these agents in NAF may contribute to breast cancer development. Also within the fluid are exfoliated epithelial cells and hematogenous cells.

The cellular components of NAF may be reflective of benign or malignant disease within the breast. For this reason, there has been considerable interest in the evaluation of NAF as a screening or diagnostic test. Some have compared this to a "Pap smear for the breast." This has been limited, however, by difficulties in not only obtaining adequate volumes of NAF to evaluate, but also in the cellularity of the fluid. The cytologic appearance of cells in the NAF can be characterized by a

#### **BOX 5-1** COMPOSITION OF NIPPLE ASPIRATE FLUID

##### ENDOGENOUS COMPONENTS

Lactose  
 $\beta$ -lactalbumin  
 Immunoglobulin  
 Cholesterol  
 Fatty acids

##### EXOGENOUS COMPONENTS THAT CAN BE FOUND

Nicotine  
 Caffeine  
 Pesticides  
 Technetium  
 Barbiturate

##### CELLULAR COMPONENTS

Benign ductal epithelial cells  
 Squamous epithelial cells (rare)  
 Transitional cells (rare)  
 Apocrine metaplastic cells (very rare)  
 Foam cells  
 Neutrophils  
 Lymphocytes  
 Histiocytes

system similar to that of ductal changes seen on biopsy (Table 5-1). Differences in the cytology of NAF between "normal" women and women with benign disease can be seen. This includes both benign disease that is not associated with an increased risk of cancer (e.g., fibrocystic disease, apocrine metaplasia, duct ectasia, fibroadenomas, and mild hyperplasia) and those diseases that are associated with an increased risk (atypical hyperplasia). These changes include increased cellularity and a

**TABLE 5-1 • Terminology for Cytologic Classification of Nipple Aspirate Fluid**

Benign, nonproliferative	Ductal epithelial cells or apocrine metaplastic cells within normal limits
Mild hyperplasia	Minimal cellular changes, slight cellular and nuclear enlargement, papillary or apocrine metaplastic changes
Moderate hyperplasia	Moderate cellular changes, increased cell and nuclear size and increased nuclear-to-cell-size ratio, chromatin granularity
Atypical hyperplasia	Marked cellular changes but not frank malignancy
Malignant cells	Unequivocal nuclear features of malignancy

greater prevalence of duct epithelial cells and duct cells in groups. Apocrine metaplastic cells are more common while fewer foam cells are seen. Only rarely does the cytology of NAF from women with benign breast disease correlate with a specific lesion, with the possible exception of a papilloma. However, the cytologic analysis of NAF can often reveal the presence of cells exhibiting signs of moderate or marked hyperplasia. This can possibly be used to assess risk (see Chapter 8).

## Abnormal Discharge of the Nipple

### Endocrine Causes of Nipple Discharge

Abnormal nipple discharge may be a response to elevated levels of prolactin. In this case, the discharge is commonly bilateral, spontaneous, and white (galactorrhea). Prolactin is significantly elevated during pregnancy and particularly in the postpartum/nursing period. Milk production can continue for up to 1 year following weaning. However, it can also be mildly elevated during sleep and during the later follicular and luteal phase of the menstrual cycle. Prolactin can also be mildly elevated with

### BOX 5-2 MEDICATIONS THAT CAN CAUSE NIPPLE DISCHARGE

- Oral contraceptives, estrogen, progestin, danazol
- Tricyclic antidepressants (amitriptyline, desipramine, doxepin, imipramine, nortriptyline)
- Anti-hypertensives (reserpine, methyldopa, verapamil, calcium channel blockers)
- Phenothiazines (acetophenazine, chlorpromazine, ruphenazine, perphenazine, prochlorperazine, promethazine, thioridazine, trifluoperazine, triflupromazine)
- Butyrophenones (droperidol, haloperidol)
- Antiemetics (metoclopramide, sulpiride)
- Opiates, codeine, heroin, marijuana
- Cimetidine
- L-arginine
- Digitalis
- Amphetamines

### BOX 5-3 MEDICAL CONDITIONS ASSOCIATED WITH ELEVATED PROLACTIN LEVELS

- Chronic renal failure
- Hypothyroidism
- Herpes zoster (shingles)
- Hypernephroma

exercise, stress, as a response to high-protein meals, and with either excessive breast stimulation or orgasm. However, a variety of hormones and neurotransmitters act to inhibit prolactin production (primarily dopaminergic) and maintain normal levels.

If this balance is thrown off, either by excessive prolactin production or diminished inhibition, the end result is galactorrhea. Because the breast lacks the ability to provide efferent feedback to the pituitary, even a small transient elevation in prolactin can lead to galactorrhea. Overproduction may come from a pituitary adenoma (prolactinomas) or ectopic production from other tumors. Because high levels of prolactin can also result in oligomenorrhea or anovulation by suppressing gonadotropin-releasing hormone, patients with a history of galactorrhea and oligomenorrhea should be considered highly likely to have a prolactinoma.

Hypothyroidism results in elevated levels of thyrotropin-releasing hormone, which can result in pituitary lactotroph stimulation and decreased clearance of prolactin. Oral contraceptives have a similar effect. Other drugs that have an antidopaminergic effect can also result in increased prolactin release (Box 5-2). Several medical conditions can lead to increased prolactin levels (Box 5-3). Finally, chronic breast stimulation can cause increased levels of prolactin. These include manipulation by the woman or her partner, contact with clothing, or chest trauma, including burns and herpes zoster.

### Breast Conditions Causing Nipple Discharge

As opposed to external stimuli, which usually results in bilateral nipple discharge, a variety of intrinsic breast conditions can cause nipple discharge, which is more commonly unilateral. The three most common lesions are duct ectasia, intraductal papillomas, and fibrocystic changes; however, nipple discharge can be secondary to intraductal or invasive (usually papillary) carcinoma.

Fibrocystic changes, both proliferative and nonproliferative, can result in nipple discharge. This is typically multiductal and more often expressed than spontaneous. The discharge is typically serous or light green. Many of these patients have other symptoms of fibrocystic changes, including dense, “lumpy” breast tissue and cyclic mastalgia.

Duct ectasia is a dilation of the duct wall associated with a loss of elastin within the walls and the presence of inflammatory cells (primarily a plasma cell infiltrate) and fibrosis around the walls. It is found in about 15% to 20% of women with symptomatic nipple discharge. The cause is unknown (see Chapter 6). The peak incidence is in women older than 50 years although it is not uncommon in premenopausal women. The discharge can be white, dark green or black, but can be bloody or purulent. Duct ectasia is a completely benign lesion that has no connection to cancer. Although changes may sometimes be seen on imaging, typically duct ectasia is radiographically occult.

Papillomas are benign lesions of the epithelium, growing within the ducts. Most often these are solitary, growing within the major ducts near the nipple, most located within 1 to 2 cm of the areolar edge within the major ducts. Grossly, this lesion appears as a small, fragile, finger-like growth within the lumen of the duct. The discharge is most commonly spontaneous and easily reproducible. Intraductal papillomas are the most common cause of bloody nipple discharge.

### *Clinical Evaluation of the Patient with Nipple Discharge*

In addition to the standard information regarding breast cancer risk, the history should cover the details of the discharge, including whether it is unilateral or bilateral, whether it is spontaneous or elicited, and the nature of the discharge (Box 5-4). Whether the discharge is spontaneous or not is a crucial question. As the popularity of self breast examination increases, more women will present with discharge that they express themselves. Because nonspontaneous expression of nonbloody nipple discharge is not associated with breast cancer, these patients can be reassured that this is a normal physiologic finding. Whether there is itching or burning pain of the nipple in association with the discharge is important, because this might be associated with infection or duct ectasia, or with a skin

#### **BOX 5-4** HISTORY IN THE PATIENT WITH NIPPLE DISCHARGE

- How frequent is the discharge?
- Is it spontaneous or do you elicit it?
- What color is it (white, green, yellow, brown, red, maroon)?
- What consistency is it (serous, watery, serosanguinous)?
- Is there blood in it?
- Is it unilateral or bilateral?
- Does it come from just one duct or multiple ducts?
- Has there been recent trauma or infection?
- Breast cancer risk factors (age of menarche, menopause, childbearing, estrogen use, family history)
- Thorough past medical history
- Signs and symptoms of thyroid disease (weight gain/loss, cold/heat intolerance, tachycardia)
- Visual field defects (pituitary tumor?)
- Infertility, oligomenorrhea, amenorrhea, acne, facial hair (hyperandrogenism or hyperprolactinemia)
- Polyuria, polydipsia
- Complete list of medications (including over-the-counter and “natural” medications)
- Possibility the patient may be pregnant

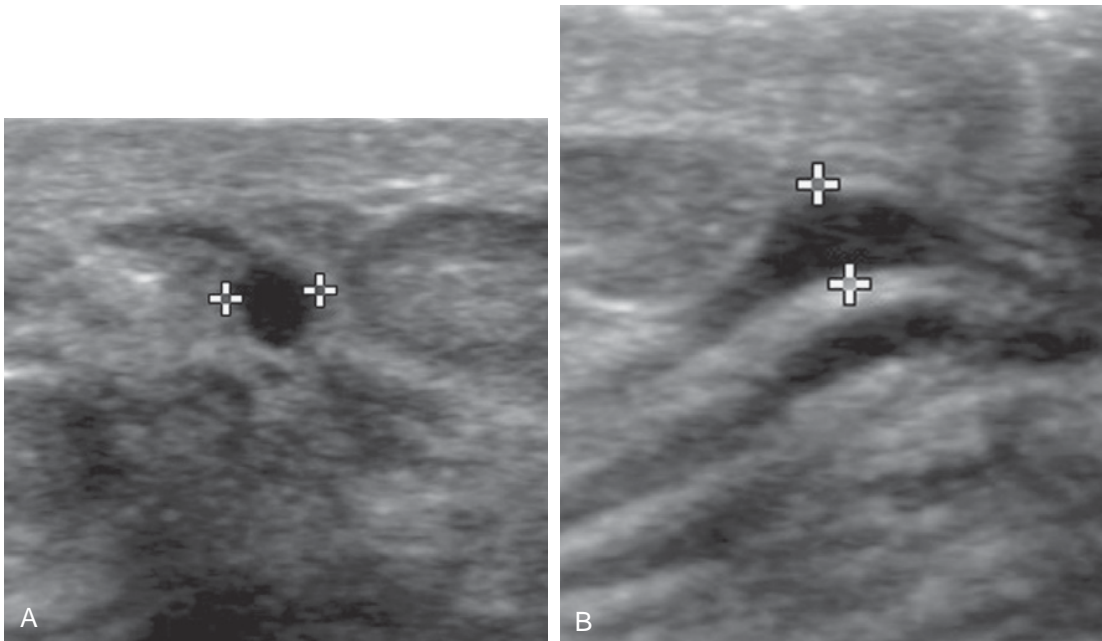
process involving the nipple. In regard to the discharge itself, the patient should describe the color (white, green, yellow, brown, red) and consistency (serous, watery, serosanguinous). A complete reproductive and endocrine review of systems and list of current medications should be obtained. The patient should be queried about recent trauma, possible stimulation, and drug use. Other symptoms that may be suggestive of an endocrine source should be elicited on the review of symptoms, including double vision, headaches, polyuria, polydipsia, fatigue, heat/cold intolerance, nervousness or restlessness, weight loss/gain, change in appetite, decreased libido, infertility, amenorrhea, and the likelihood of pregnancy.

Physical examination should begin with examination of the nipples. Sometimes a nipple discharge is actually an exudate related to skin irritation from inverted nipples, eczematoid lesions, trauma, or herpes simplex infections. Even though these are not associated with

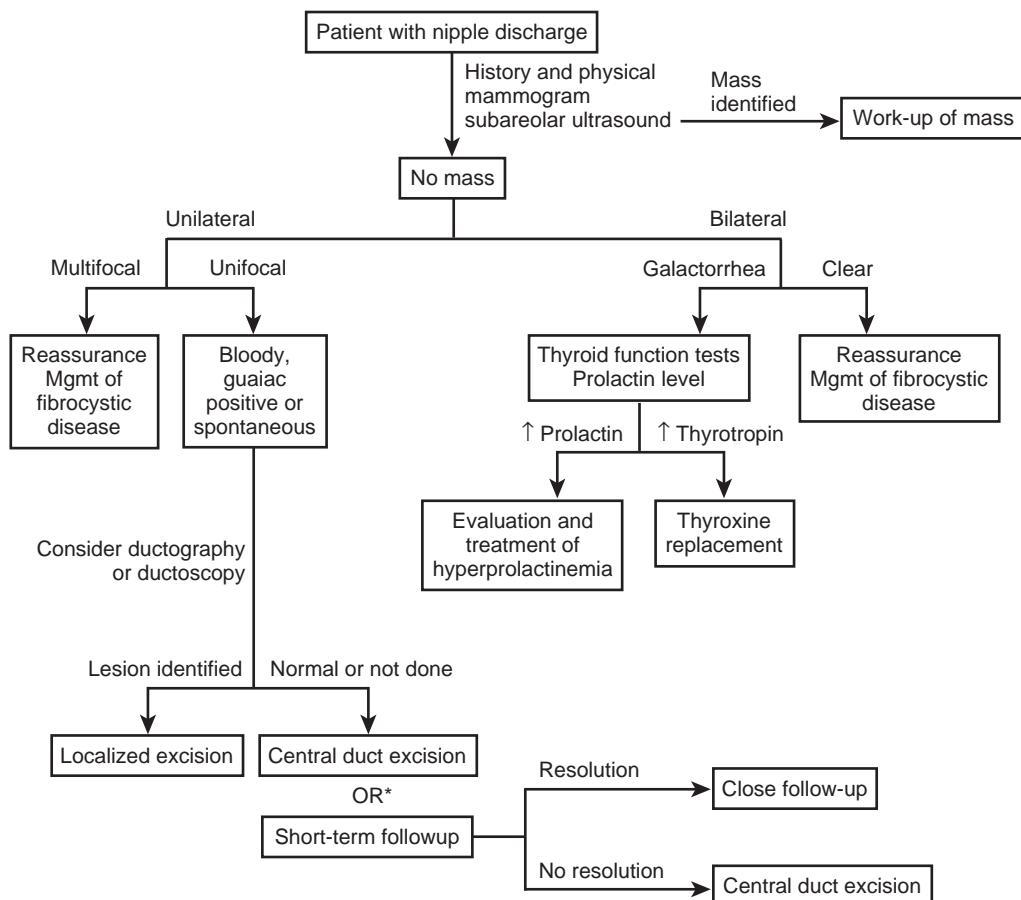
cancer, it is also important to rule out Paget disease as a source of a nipple exudate (see Chapter 11). Tubular swellings called “varicocele lesions” of the breast may be palpable below the nipple-areolar complex, and are often associated with duct ectasia. The next step is to determine which duct (or ducts) is producing the discharge. Bilateral discharge or discharge from multiple ducts within one breast are very rarely malignant, whereas discharge from a single duct is more worrisome. Single duct discharge can usually be expressed when pressure is applied to a trigger point. With the patient supine and the arm over the head, apply pressure at various points around the areola until discharge is expressed. You should carefully document this point because this may be important in planning subsequent surgery. The discharge can easily be tested for the presence of heme by laboratory test sticks (Hemocult). In some cases, the discharge can also be easily collected on a glass slide for cytology. The slide is held at the opening of the duct and while applying pressure to cause discharge, the slide is moved across the surface of the nipple to make a thin spread. It can be immediately fixed. If more discharge can be expressed, several smears should be prepared because the last few drops are usually more cellular. The remainder of the breast should be carefully examined for the presence of a mass or other signs of malignancy.

The next step is typically mammography and ultrasound, particularly in age-appropriate patients. Mammogram is indicated in all women with a unilateral, spontaneous nipple discharge, including women younger than 35 years. Ultrasound is recommended in addition to mammogram. However, both studies are usually negative. Ultrasonography may or may not reveal dilated ducts with an intraluminal lesion (Fig. 5-1). The utility of magnetic resonance imaging (MRI) for the patient with a nipple discharge of high suspicion has been suggested, but data are limited on its utility in this situation. It may be a consideration in the high-risk woman presenting with nipple discharge or when the cytology is positive and the remainder of the workup is negative.

The remainder of the workup depends on the findings on history and physical examination (Fig. 5-2). A mass identified on examination or mammography should be biopsied. Patients who likely have discharge associated with fibrocystic changes can be reassured and managed conservatively. These include patients with bilateral or unilateral mult ductal discharge that is serous or light green, especially if they have other symptoms of fibrocystic changes on examination (e.g., nodularity, premenstrual lumpiness, and discomfort). Patients with discharge that is multifocal, sticky, and



**Figure 5-1.** Radial and antiradial images demonstrate a mildly dilated duct in axial and longitudinal projections. (Images courtesy of Dr. Alexis Nees, Department of Radiology, University of Michigan.)



**Figure 5-2.** Approach to the patient with nipple discharge. Bilateral discharge is rarely malignant and may represent fibrocystic disease or galactorrhea. For the latter, thyroid function tests and a prolactin level should be obtained. Unilateral, single duct discharge is concerning if it is bloody or spontaneous. Whereas cytology, ductography, or ductoscopy may be helpful, duct excision may ultimately be necessary to rule out cancer. Recent studies suggest that if the mammogram and ultrasound are negative, the likelihood of malignancy may be low enough to warrant short-term follow-up rather than proceeding to central duct excision.

multicolored (including dark green or black, but heme-negative) most likely have duct ectasia and can also be safely observed. Surgery in these cases is reserved for palliation because continued discharge can be distressing and inconvenient to many patients. If there is obvious blood in the discharge or if the Hemocult is positive, patients will require further evaluation and ultimately surgery.

Patients with bilateral white discharge consistent with galactorrhea should have a workup for the source of hyperprolactinemia. Both prolactin levels and thyroid function tests should be obtained. If the patient is taking a medication known to increase prolactin, it should be discontinued if possible. Because transient elevations of prolactin can be seen with trauma or stimulation, the patient may be advised to avoid these to determine whether there is

resolution of the discharge. If hyperprolactinemia is persistent, an MRI of the brain should be obtained to rule out a prolactinoma.

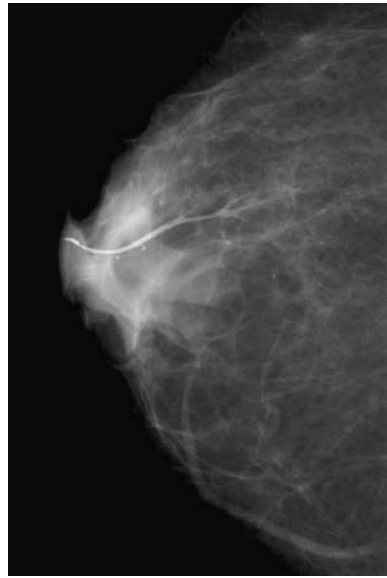
Finally, there is the patient with unilateral, uniductal spontaneous discharge. This is otherwise known as pathologic discharge. It may or may not contain blood. A unilateral, spontaneous clear discharge from one duct is still suspicious, even if no blood is present. However, women with pathologic nipple discharge are still highly likely to have benign disease, with half having an intraductal papilloma, 15% to 20% having duct ectasia, and only about 10% having carcinoma. Although there are many modalities available to evaluate this condition further, most do not have the sensitivity or specificity to completely rule out malignancy, so almost all of these patients ultimately require a duct excision for diagnosis.

Testing the nipple discharge for the presence of occult blood by means of Hemoccult is inexpensive, so it is hard to argue against performing it during physical examination. Any patient with occult blood requires duct excision for definitive diagnosis, although most cases of bloody nipple discharge are secondary to intraductal papillomas and not malignancy. The results of Hemoccult evaluation are useful to rule out occult blood with the dark, multifocal discharge associated with duct ectasia. In this case, a negative result may allow the patient to avoid a duct excision. However, with unifocal, spontaneous discharge, the sensitivity of Hemoccult is not high enough for a negative result to preclude the need for surgery. Cytologic examination of the discharge, as described, may be useful if the fluid shows cancer, but this is rare and the high false-negative rate precludes using cytology to exclude cancer. Thus, cytology may be useful but does not preclude a biopsy if negative.

Ductography is often the next test obtained in the woman with pathologic nipple discharge. This procedure involves anesthetizing the breast (using topical agents such as EMLA cream [2.5% lidocaine and 2.5% prilocaine] or injectable agents) followed by duct cannulation with a small nylon catheter or needle. A water-soluble contrast agent is then injected into the duct and mammograms are obtained immediately (Fig. 5-3). Several studies have shown that an abnormal ductogram does not preclude the presence of cancer, however. Therefore a woman with a suspicious nipple discharge and a normal ductogram still requires biopsy to rule out cancer. One advantage to obtaining a ductogram may be the combination of wire localization and ductography to localize a lesion seen on ductogram. Ductography can also sometimes be used to estimate the extent of a lesion seen on imaging.

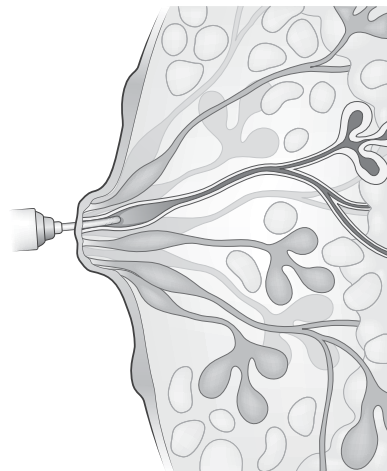
### Ductal Lavage and Ductoscopy

Newer modalities are playing an emerging role in the evaluation of nipple discharge. Ductal lavage is a procedure that involves eliciting cells from one or more ducts using catheterization and irrigation of the duct followed by cytopathologic evaluation (Fig. 5-4). This technique is currently being evaluated as a screening test for asymptomatic women, and there are minimal data on its sensitivity and specificity in women with pathologic nipple discharge.

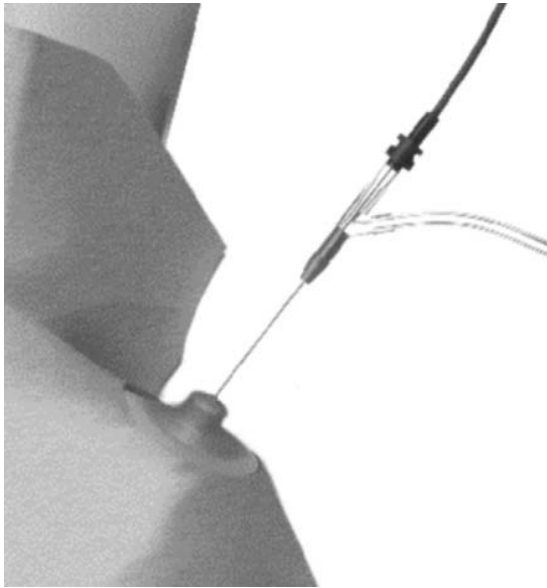


**Figure 5-3.** Craniocaudal view from normal ductogram. (Image courtesy of Dr. Alexis Nees, Department of Radiology, University of Michigan.)

A more promising technology is that of ductoscopy. Mammary ductoscopy involves the insertion of a microendoscope into the duct to directly visualize the ductal lining of the breast (Fig. 5-5). This also allows for the retrieval of epithelial cells by lavage. Albeit relatively new in the United States, this has been used in Europe and Japan for several years. The newest generation of microendoscope, the ViaDuct mammary ductoscope (Acueity, Larkspur, CA)



**Figure 5-4.** Ductal lavage. A small catheter is inserted into one or more ducts, allowing the irrigation of the duct. The retrieved fluid is then sent for cytopathologic evaluation.



**Figure 5-5.** The ductoscope is inserted into the duct for both direct visualization and lavage. (Images courtesy of Acueity, Inc.)

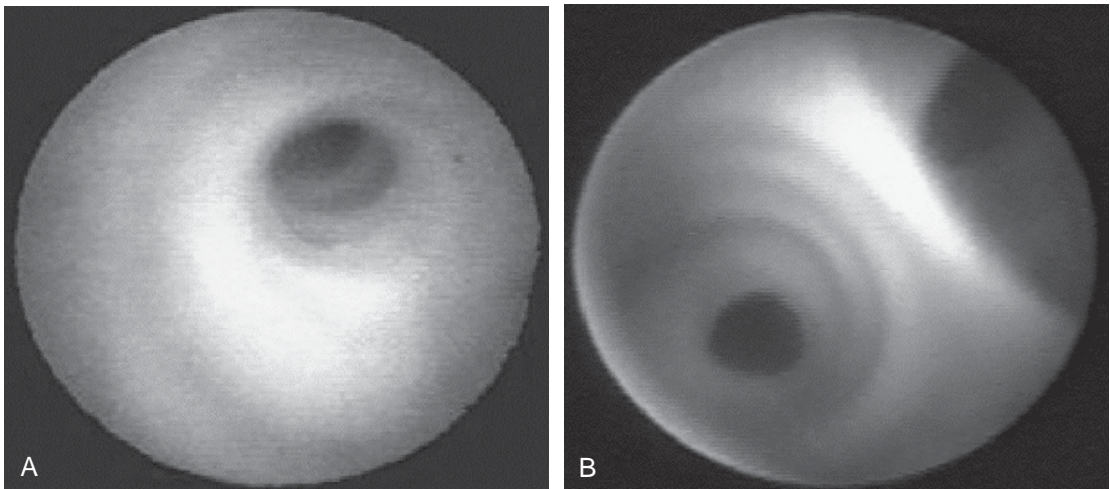
is now approved by the Food and Drug Administration for human use. It has a slim diameter (0.9 mm) consisting of an outer sheath for insufflation and aspiration surrounding a fiberoptic core, which connects to a video system. The procedure can be performed in an office setting with minimal discomfort after performing a nipple block with topical EMLA cream for 30 minutes and either an intradermal injection of lidocaine around the nipple-areola complex or intraductal lidocaine. In the case of ductoscopy for nipple discharge, it may be

advisable to do the procedure in the operating room so that it may be combined with an excision of any pathology identified. After expressing the nipple discharge so that the ductal orifice can be identified, the opening is dilated and the ductoscope advanced under direct visualization (Fig. 5-6). Ductal washings are obtained by aspirating fluid. If any pathology is identified, these can be marked for immediate excision or future image-guided biopsy.

Although ductoscopy has been promoted for use in patients with known cancer undergoing lumpectomy or as a screening test in high-risk individuals, the largest experience has been in the evaluation of pathologic nipple discharge. The ductal dilation associated with pathologic nipple discharge makes it easier to introduce the ductoscope and many of the patients have an intraductal papilloma that is easily localized and excised (Fig. 5-7). If a point of interest is seen, the light can be seen in the skin of the breast (if the room is dark) and can be marked to guide a subsequent excision.

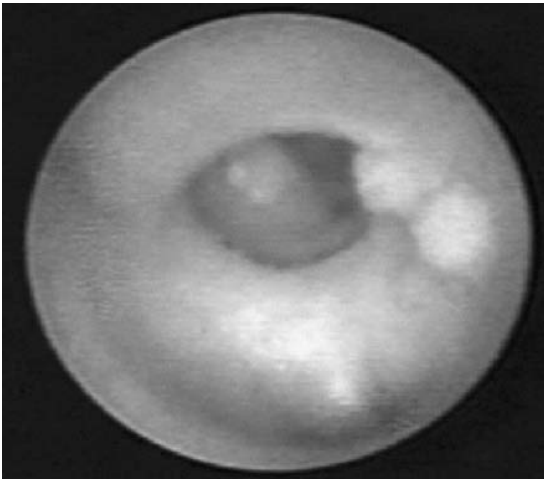
### *Duct Excision*

If a lesion is noted on physical examination, mammogram, ductography, or ductoscopy, it should be the target of a biopsy. However, this still leaves many women with a suspicious discharge and no specific area of abnormality. In a patient with a worrisome discharge, duct excision has been considered the gold standard and is generally recommended. This procedure is both diagnostic and therapeutic. This



**Figure 5-6.** Ductoscopic images of normal ducts. (Images courtesy of Acueity, Inc.)





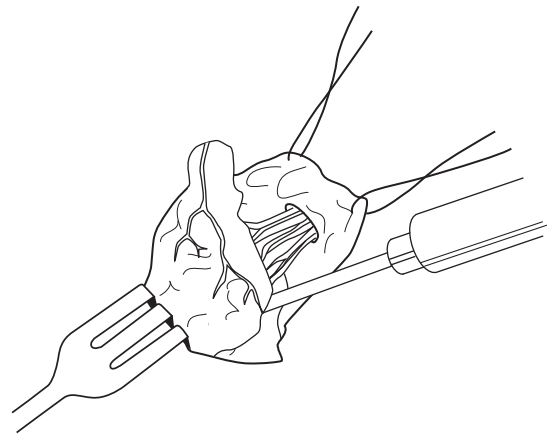
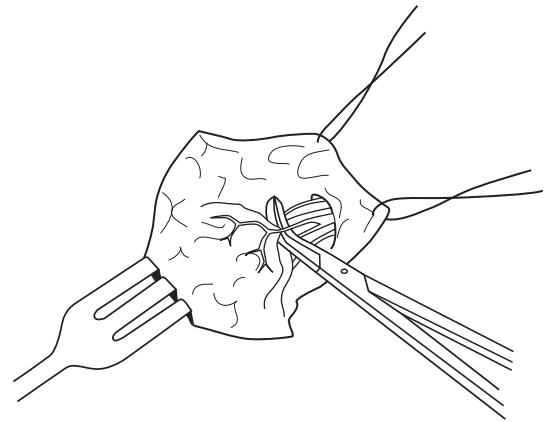
**Figure 5-7.** Ductoscopic image of an intraductal papilloma. (Images courtesy of Acueity, Inc.)

recommendation is based on the 3% to 10% incidence of finding occult cancer in patients with worrisome discharge. However, much of these data were collected when breast imaging was not as sensitive. With improved mammography and the use of subareolar ultrasound, more recent studies suggest that patients with single duct, spontaneous discharge or guaiac-positive discharge have a very low risk of malignancy when all imaging studies are negative. Close observation with short-term follow-up to determine whether the discharge resolves may be reasonable. However, if the discharge fails to resolve, duct excision should be performed. The procedure may also be considered for palliative reasons, even if malignancy is not suspected.

A circumareolar incision is marked to encompass one-third to one-half the circumference of the areola. When more than 50% is included, one risks devascularization. Placing the incision in the inferior aspect of the areola minimizes the risk of decreasing nipple sensation. Lidocaine is infiltrated into the skin at the site of the incision and underneath the areola. After making the incision, the skin of the areola is elevated with a skin hook so that dissection can be carried out under gentle tension. Dissection with blunt tenotomy scissors elevates the areola to the area directly behind the nipple.

Every attempt should be made to identify the involved duct. A large dilated duct can often be identified during dissection behind the nipple. If not, a small lacrimal duct probe can be placed through the involved duct via the skin opening. If this fails to work, methylene blue can be injected into the duct; this is

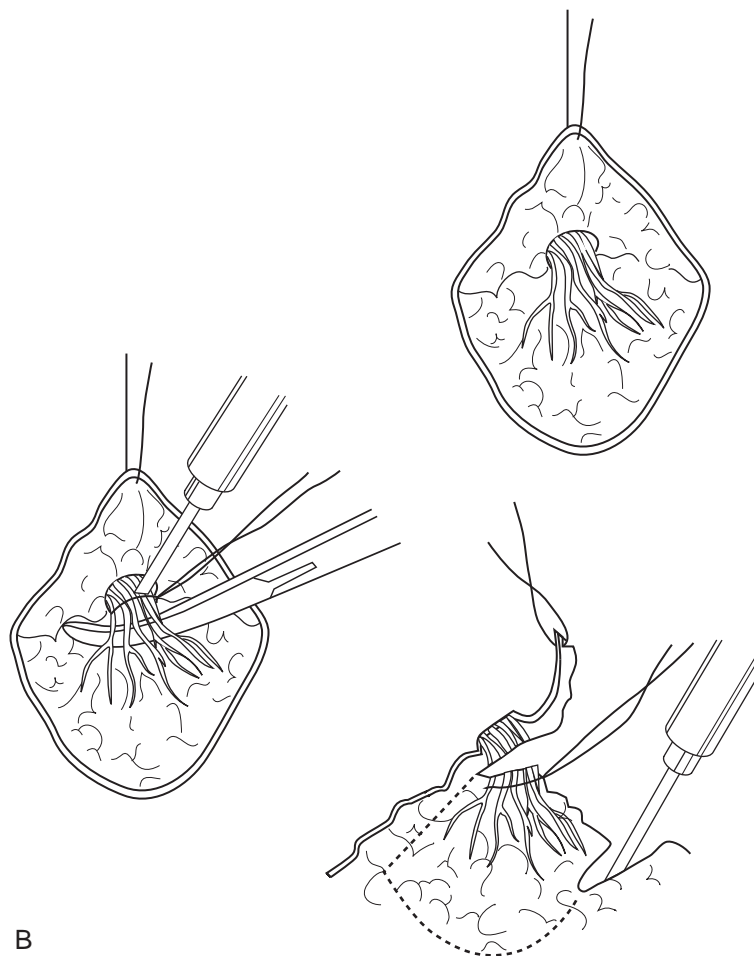
preferably done before making the skin incision. Once identified, the duct should be dissected free and divided between clamps. This should be done close to the nipple if possible because small papillomas can occur in this location. The duct should then be traced deeper into the breast with a small cone of surrounding tissue, getting slightly wider as the dissection continues. Approximately 3 cm of duct and surrounding breast tissue should be excised. Once the duct is excised, the surgeon should apply pressure to the trigger point and around the areola to confirm that there is no continued discharge. This can also be done from within the wound by milking the other ducts toward the nipple. If the involved duct cannot be identified, a complete duct excision can be performed by encircling all of the major ducts (Fig. 5-8). Approximately 2 to 3 cm of the deep breast tissue should be excised with the ducts. If needed, a purse-string suture can be placed below the nipple to avoid nipple



A

**Figure 5-8. A,** Technique for single duct excision.

(Continued)



B

**Figure 5-8—cont'd B**, Technique for central duct excision.

inversion. Once it is assured that there is no further discharge and hemostasis has been achieved, the skin can be reapproximated with small, interrupted absorbable sutures.

### *Suggested Readings*

1. Carty NJ, Mudan SS, Ravichandran D, et al. Prospective study of outcome in women presenting with nipple discharge. *Ann R Coll Surg Engl* 1994;76:387.
2. Escobar PF, Crowe JP, Matsunaga T, Mokbel K. The clinical applications of mammary ductoscopy. *Am J Surg* 2006;191(2):211–215.
3. Gray RJ, Pockaj BA, Karstaedt PJ. Navigating murky waters: A modern treatment algorithm for nipple discharge. *Am J Surg* 2007;194(6):850–855.
4. Hussain AN, Policarpio C, Vincent MT. Evaluating nipple discharge. *Obstet Gynecol Surv* 2006; 61(4):278–283.
5. Nelson RS, Hoehn JL. Twenty-year outcome following central duct resection for bloody nipple discharge. *Ann Surg* 2006;243:522.
6. Richards T, Hunt A, Courtney S, Umeh H. Nipple discharge: A sign of breast cancer? *Ann R Coll Surg Engl* 2007;89(2):124–126.
7. Sakorafas GH. Nipple discharge: Current diagnostic and therapeutic approaches. *Cancer Treat Rev* 2001;27(5):275–282.
8. Santen RJ, Mansel R. Benign breast disorders. *N Engl J Med* 2005;353:275.
9. Simmons R, Amadovich T, Brennan M, et al. Non-surgical evaluation of pathologic nipple discharge. *Ann Surg Oncol* 2003;10:113–116.
10. Vargas HI, Vargas MP, Eldrageely K, et al. Outcomes of clinical and surgical assessment of women with pathological nipple discharge. *Am Surg* 2006; 72(2):124–128.