

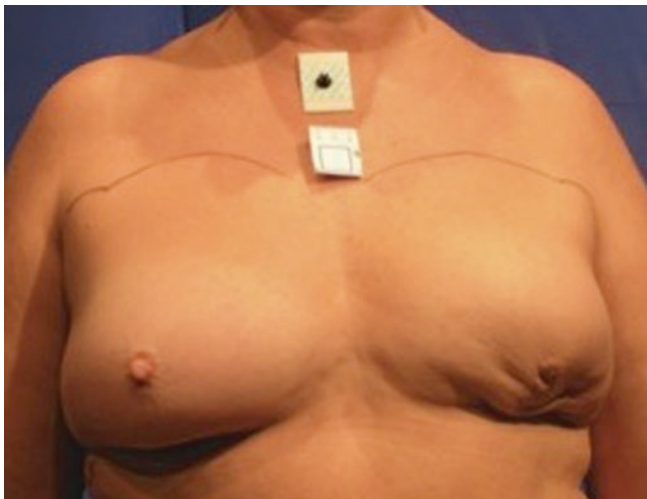
# Oncoplastic Breast-Conserving Therapy

*Elias E. Sanidas and Florian Fitzal*

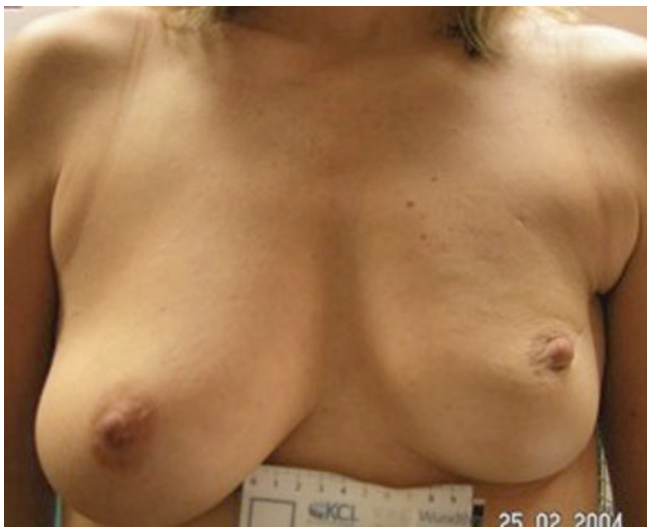- 19.1 Introduction – 230**
- 19.2 Indications for Oncoplastic Surgery – 230**
  - 19.2.1 Oncological Safety of Oncoplastic Techniques – 231
- 19.3 Achieving Clear Resection Margins in Oncoplastic Surgery – 231**
- 19.4 Specimen Marking – 232**
- 19.5 Cavity Marking – 232**
- 19.6 Oncoplastic Techniques: Classification – 232**
  - 19.6.1 Volume Replacement, Volume Displacement, Level 1 and 2 – 232
  - 19.6.2 Volume Displacement – 233
  - 19.6.3 Technical Atlas of Level 1 Techniques – 233
  - 19.6.4 The Batwing Mastopexy – 233
  - 19.6.5 Doughnut Mastopexy – 236
  - 19.6.6 Round Block Mastopexy – 236
- 19.7 Technical Atlas of Level 2 Techniques – 236**
- 19.8 Relative Contraindications for Oncoplastic Surgery – 241**
  - 19.8.1 Contraindications – 241
- 19.9 Cosmetic Outcomes – 242**
- References – 243**

## 19.1 Introduction

When the word oncoplastic was first introduced in the early 1990s, the rationale was clear. Breast conservation rates were progressively increasing with rates as high as 90% in some series; however, in some cases, this was at the expense of poor cosmetic outcomes (■ Figs. 19.1 and 19.2). The aim was to improve long-term cosmetic outcomes after breast conservation and radiotherapy, facilitating conservation surgery where more than the traditional relative volume (usually up to 20%) needed to be excised or where the location of the tumour was adverse (superior/medial/inferior). It was realised that breast volume, shape and symmetry could be maintained or even, in some cases, enhanced whilst resecting up to 50% of breast volume without loss of oncological safety. Since then, there has been a massive expansion in the num-



■ Fig. 19.1 Poor cosmetic outcome from conservation surgery for an inferiorly placed cancer resulting in a typical bird's beak deformity



■ Fig. 19.2 Poor cosmetic outcome from conservation surgery for a superiorly placed tumour resulting in size and volume asymmetry and nipple malposition

ber of techniques available, a greater understanding of the oncological implications of such surgery and a progressive increase in the training of the breast workforce in these often complex techniques. The techniques are broadly divided into two groups: volume displacement (often also termed therapeutic mammoplasty techniques) and volume replacement which may be subdivided into lipofilling and flap-based techniques. More detailed discussion of lipomodelling is given in ► Chap. 20 and flap-based techniques in ► Chap. 31, and these techniques will not be addressed in this chapter which will focus on mammoplasty techniques.

There has been a rapid growth in the use of and interest in these techniques and a proliferation of methods available [1]. Complex atlases of procedures based on the site and size of the tumour are available to aid the surgeon in selecting the optimal technique [2]. The techniques are complex and require skill and training both in understanding their indication and contraindications and in their optimal performance surgically to get good results. In some centres, these procedures are performed jointly between breast oncology surgeons and plastic surgeons. In some centres, fully oncoplastic trained surgeons perform both the ablative and restorative components of surgery. Training in oncoplastic surgery is now more widely available, and good quality training programmes and guidelines are being developed globally to make these techniques more widely available and enhance quality [3–5].

## 19.2 Indications for Oncoplastic Surgery

### 1. Adverse tumour volume to breast volume ratio.

Resection of more than 15–20% of breast volume is likely to result in asymmetry and adverse cosmetic outcomes (■ Figs. 19.1 and 19.2) as was elegantly shown by the Nottingham group [6] with patient satisfaction rates of over 90% if only 5% or less of breast volume was excised to only 25% satisfied once 20% of breast volume is lost. Whilst this may be addressed by the use of neoadjuvant systemic therapy in some cases, in others, the use of oncoplastic techniques will permit higher percentage volume loss with good cosmesis and better patient satisfaction by reshaping the breast to minimise indentation and deformity.

### 2. Adverse tumour location (superomedial, central/subareolar, inferior).

Some areas of the breast are more difficult to resect tissue from than others whilst maintaining good cosmesis. Areas of concern are medially located tumours where the scar or indentation may lie in the cleavage area and where there is less breast parenchymal volume and superiorly sited tumours for the same reason. Both sites may also result in nipple malposition due to scar retraction. Resection of inferiorly sited tumours may cause nipple malposition or a bird's beak deformity. Centrally located tumours may necessitate loss of the nipple and, if resected as an ellipse, cause a flattened off breast

shape. Oncoplastic techniques allow better cosmesis following resections in these areas. A disc of nipple skin may be imported to create a base for a nipple reconstruction for centrally located tumours.

### 3. *Redo conservation surgery.*

This is a more controversial indication for oncoplastic surgery [7]. There is little good quality evidence at present in support of this, but for some women who have a strong preference for a conservative approach, oncoplastic operations may contribute to acceptable cosmetic results. Caution is needed in undertaking these procedures as these women will have had breast radiotherapy and may be at higher risk of wound healing problems and pedicle hypovascularity. The oncological safety of these procedures is also not supported by high-level evidence.

### 4. *Multifocal and multicentric disease.*

There is emerging evidence that BCT in multifocal (MF) disease is oncologically safe [8] but may result in a slightly inferior outcome compared with BCT in unifocal breast cancer. Patients in the MF group had higher 10-year LRR however (0.6% vs. 6.1%,  $p < 0.001$ ). Oncoplastic surgery may be used to perform segmentectomy in MF disease confined to one segment with subsequent reshaping of the breast. In multicentric disease, oncoplastic techniques may also be used to resect more than one discrete area in different breast quadrants whilst retaining breast shape; however, there is little high-level evidence supporting the oncological appropriateness of this approach at present although a number of case series show acceptable oncological outcomes [9, 10].

### 5. *Macromastia.*

For women with pre-existing macromastia, oncoplastic surgery offers an opportunity to simultaneously perform bilateral breast reduction which may have considerable appeal for these women. Macromastia may cause shoulder and back pain, embarrassment, difficulty finding suitable clothes and problems with skin infections in the inframammary fold. For many of these women, bilateral breast reduction may have many benefits by reducing these symptoms, but also, women with large breasts may be technically challenging for the radiation oncologist to administer whole breast radiotherapy to and may also suffer more significant post-radiotherapy complications such as breast oedema and skin reactions. The majority of studies of therapeutic mammoplasty for macromastia achieve low rates of incomplete excisions (approximately 10%) [11]. The wide local excision is usually performed prior to, and as a separate specimen to, the reduction procedure; although the tumour is in one of the primary areas where tissue is excised as part of the reduction, the tumour may be excised en bloc with the reduction sample, but care must be taken with margin marking and orientation. Rates of local recurrence with this technique are acceptable [11].

A large review including data on 276 patients [12] treated with bilateral reduction mammoplasty concluded that women with bilateral cancer and macromastia can obtain oncologically safe and cosmetically excellent outcomes.

A detailed review [13] of the evidence about therapeutic mammoplasty (TM) concluded that the oncological outcomes appear comparable to simple BCS. However, they note that no randomised controlled trials have been performed and the evidence in support of these techniques is all derived from case series and cohort studies.

## 19.2.1 Oncological Safety of Oncoplastic Techniques

Due to the sometimes complex nature of such surgery, which may make margin assessment more challenging, complicate surgery to take cavity shaves and make breast radiotherapy boost more difficult to localise, concerns have been raised about whether these procedures are oncologically safe. Whilst there have been no randomised trials to compare the outcomes of standard BCS/mastectomy with oncoplastic surgery, there have been numerous large cohort studies, often with long follow-up reported, which show that these techniques can result in acceptable local regional recurrence rates [14–18]. Even in cases with large-sized primary tumours, acceptable rates of recurrence are reported [15]. A recent systematic review has confirmed this general finding [16].

Based on the fact that oncoplastic techniques generally have the flexibility to remove larger volumes of breast tissue [14], this should give the surgeon flexibility to take wider margins and hence enhance oncological safety. However, the often complex pattern of tissue removal and repositioning means great care is needed in orienting specimens and documenting and marking cavities.

Early in the oncoplastic era, small, retrospective and relatively short follow-up series were published presenting recurrence rates and/or survival rates. One such early series in 2003 presented 101 patients with a 16% re-excision or subsequent mastectomy rate, a LRR of 9.4% and an overall survival rate of 95.7% after 44 months of follow-up [14]. Whilst a 9.4% LRR is high by modern standards and was relatively high for that time subsequent series have shown much better results. For example, Rietjans and colleagues [18] in 2007 presented 148 cases with only a 2.2% re-excision/mastectomy rate, a 3% LRR and an overall survival rate of 92.4% after 74 months of follow-up. Numerous studies have now reported on oncoplastic BCS, and the results are generally very good and similar to standard oncology outcomes [14–18].

## 19.3 Achieving Clear Resection Margins in Oncoplastic Surgery

Whilst rates of local recurrence are falling steadily following BCS, when it does occur, it is distressing and may result in the need for mastectomy [19] and a slightly higher late mortality disadvantage. Rates are falling due to better adjuvant radiotherapy and systemic therapy regimes, coupled with better surgery and margin assessment by pathologists. However, wider margins are not the answer. Indeed recent evidence

and consensus are that a no-tumour at the inked margin is acceptable [20] and wider margins than necessary adversely affect cosmesis. Reoperation for cavity re-excision also has an adverse cosmetic impact as well as the financial costs and personal burden to the patient. There are a range of techniques to ensure that adequate margins are achieved which have proven efficacy in reducing rates of positive margins, but detailed review is out of the scope of this chapter. Excellent reviews are available [21]. Use of these techniques is very relevant in the oncoplastic setting where it may be technically challenging to go back to re-excite a positive margin.

The tumour cavity surgical margins after an oncoplastic procedure may be altered or transferred from the primary tumour location to other quadrants in the breast due to the use of local or distant displacement/replacement flaps as it happens in lateral or J-mammoplasty or reduction mammoplasty techniques such as inverted T mammoplasty. It is therefore imperative that the surgeon keeps detailed notes and diagrams of the operation and marks the original tumour bed with clips and ideally, in complex cases, uses some form of intraoperative margin assessment to minimise the need to go back for cavity shaves. Good communication with the radiation oncologists is essential when boost is planned as the skin scar may be some distance from the tumour bed and use of marker clips to the tumour bed, before rotation/translocation of the tissue, is essential [22, 23]. Placement of six clips has been proposed as optimal (medial, lateral, superior and inferior and to mark the deep fascia and subcutaneous margins).

## 19.4 Specimen Marking

Specimen orientation in breast surgery is of paramount importance. This is more so in oncoplastic surgery where the specimens may be irregular and asymmetric due to tissue removal for reshaping of the breast in addition to the actual tumour specimen. In oncoplastic cases, the tumour is more likely to be complex: large, multifocal or multicentric tumours or a known area of impalpable DCIS adjacent to an invasive focus, all of which must be communicated to the pathologist. Some cases may have followed primary systemic therapy, and only a marker clip may indicate the original primary location. The pathologist must be made aware of these preoperative tumour characteristics to avoid missing known second lesions at specimen «cut up» which is vital for margin assessment. Specimen X-rays should be sent to the pathology lab, especially in cases with complex tumour patterns (e.g. DCIS extent). This may help the pathologist to locate an impalpable tumour in the specimen. Each margin must be specifically marked and a detailed diagram provided showing which marker indicates which margin in the event that re-excision is needed. This will ensure that only the involved margin needs to be re-excised rather than the entire cavity re-excision [24]. Any intraoperative cavity shaves must be similarly identified and the new cut surface marked. Despite the importance of specimen marking and orientation, there

is no universally accepted and implemented specimen marking system. A recent survey in the UK [25] of 117 breast units, nearly one quarter had no specimen orientation protocols. Among these, 11 were national breast screening units.

In general, the surgeon places sutures or clips during surgery, and inking of the specimen margins is done later by the pathologist in the pathology laboratory [26]. However, there may be better re-excision rates if the orientation is done intraoperatively with sutures and ink applied by the surgeon in the presence of the pathologist [27]. There are also commercially available orientation boards/holders to which specimens may be pinned and orientated in some detail to facilitate both cut up and specimen radiology [25, 28–30]. The most common protocol seems to be the method with different length/number of sutures or clips on three of the six margins [25, 31]. However, the suture-only method may not facilitate optimal specimen orientation by the pathologist, especially in small specimens (smaller than 20 cm<sup>3</sup>), whilst the presence of the skin or muscle on the specimen does not contribute to better orientation [30].

## 19.5 Cavity Marking

Knowing the exact position of the tumour bed has always been a great help for the radiation oncologists to deliver boost radiotherapy to breast patients. Although there are no data to support that more accurate tumour bed delineation will lead to improvement of local control, it may very well improve cosmetic outcomes [32].

Delineation of the resection cavity by seroma formation or location of the skin incision is relatively largely inaccurate [32]. The best marking method is the placement of metallic clips to the tumour cavity varying from one clip (not very accurate) to six clips for each margin of the cavity and up to 8–10 surgical clips [33] into the tumour bed after resection and before oncoplastic reconstruction. Detailed notes should be kept of clip placement.

## 19.6 Oncoplastic Techniques: Classification

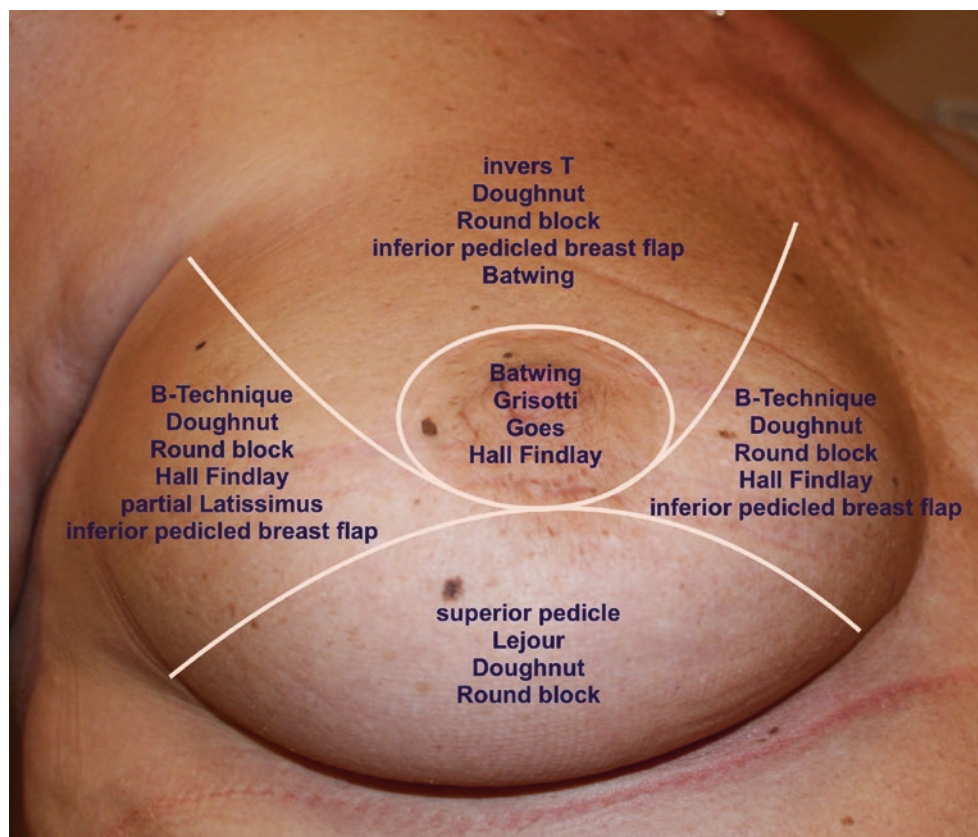
### 19.6.1 Volume Replacement, Volume Displacement, Level 1 and 2

There are two broad techniques in oncoplastic surgery to reconstruct the breast parenchymal defect:

1. Volume displacement: Local breast parenchyma is repositioned to fill the defect using either simple advancement or more complex pedicles (levels 1 and 2, respectively).
2. Volume replacement: Distant autologous or heterologous material such as muscle or dermofascial flaps (see ► Chap. 31, Autologous Flaps), silicone prostheses (► Chap. 29, Implants, de Boniface, and ► Chap. 30, Implant-Based Techniques, Douek) or fat grafting (► Chap. 20, Lipomodelling) may be used.



**Fig. 19.3** Atlas of techniques of oncoplastic reshaping according to the quadrant of the breast containing the cancer



## 19.6.2 Volume Displacement

Local breast parenchymal rotation flaps can only be used in breast conservation surgery. There are several options from small parenchymal rotations after lumpectomy and semi-circular incisions up to complex breast reduction techniques, nipple transposition and local skin rotation flaps. These techniques may be divided into level 1 and 2 depending on whether a formal pedicle is used. There are a variety «atlases» of techniques for tumours in different breast quadrants [2], and surgeons should be familiar with a range of methods for each site as well as having an understanding of how they may need to be modified in certain circumstances (■ Fig. 19.3).

## 19.6.3 Technical Atlas of Level 1 Techniques

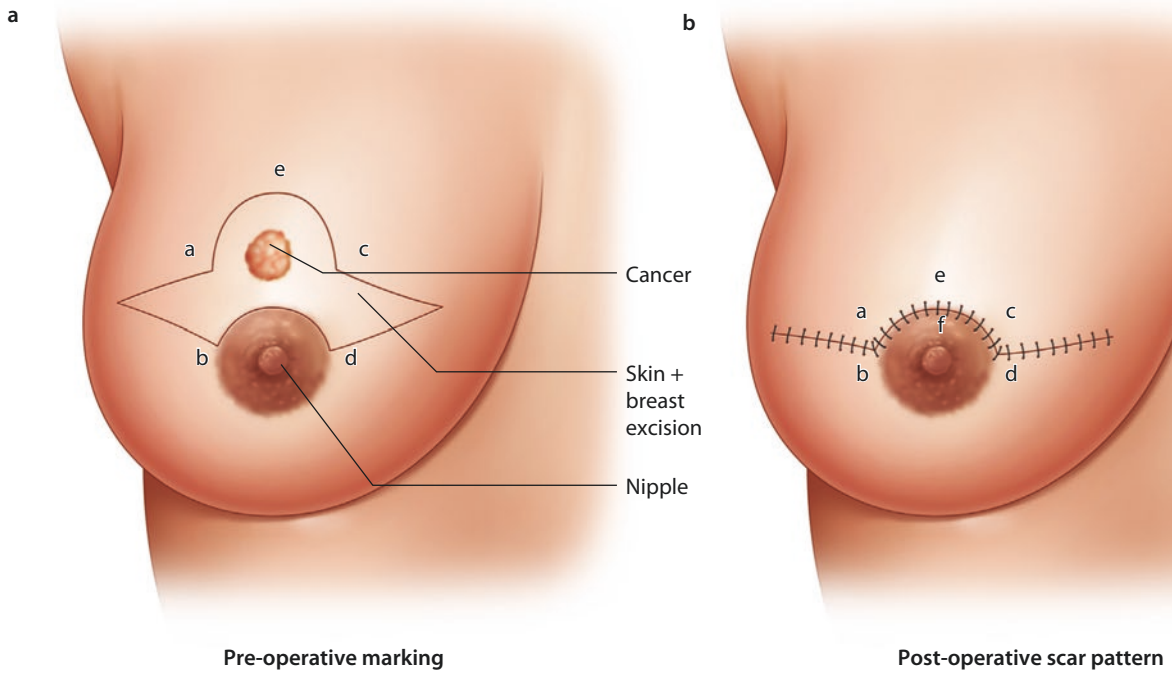
All types of breast defect reconstructions using local breast tissue without the use of breast reduction techniques or major nipple transposition belong to level 1 techniques (■ Fig. 19.4a–f). Typical level 1 techniques include batwing flaps (■ Figs. 19.5 and 19.6) and round block and doughnut techniques (■ Fig. 19.7a–f). Also intra-parenchymal flaps using dual-layer undermining (between the pectoralis and its

fascia as well as between the skin and breast gland to rotate the breast parenchyma into the defect and close it) are level 1 techniques. In general, these techniques are best performed on women with dense breasts, especially if significant parenchymal flap mobilisation is used. Women with fatty breast may be at increased risk of fat necrosis.

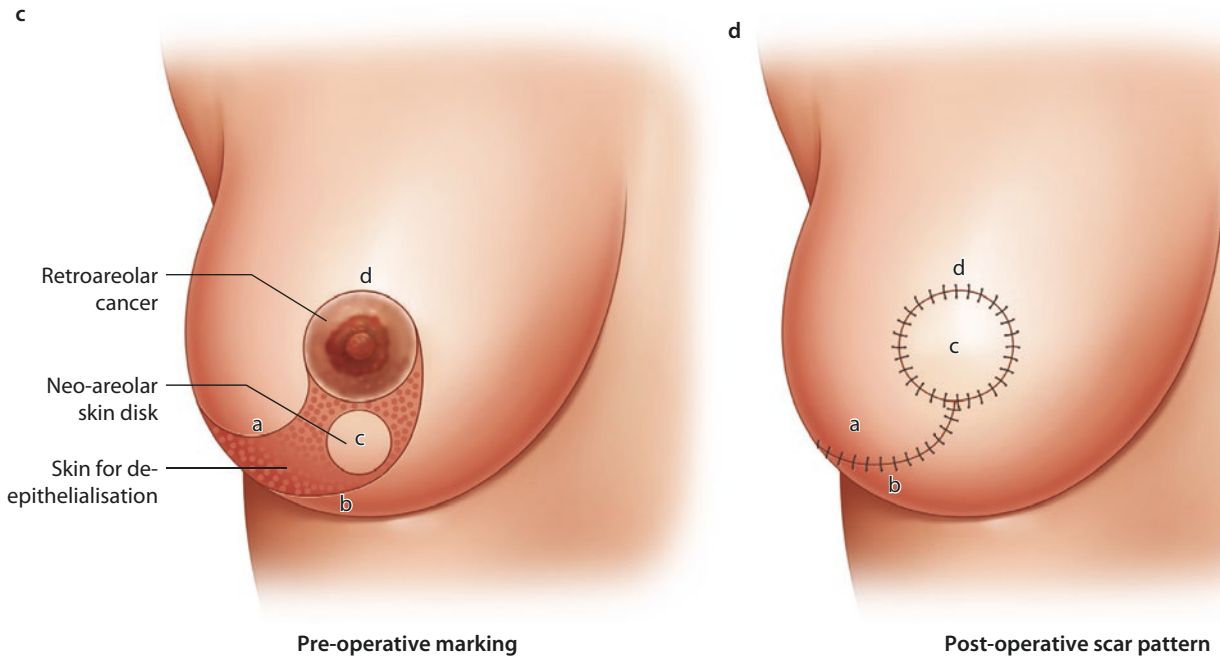
## 19.6.4 The Batwing Mastopexy

The batwing technique derives its name from the shape of the incision. In general, this technique is ideal in cases of breast tumours close to the skin behind or just above the nipple. In these cases, it is necessary to resect the skin together with the tumour. The resected skin with its underlying defect may easily be filled with the tissue located caudally from the breast tumour (Figs. ■ 19.4a, b, ■ 19.5, and ■ 19.6). Women with ptotic as well as non-ptotic and smaller breasts are ideal candidates for batwing procedures. The technique has a very low morbidity as the nipple retains most of its attachments and vascular supply with very little parenchymal undermining, so there is little risk of fat necrosis. If the resection volume is too large, the resultant breast shape may be somewhat flattened (■ Fig. 19.7). Larger defects above 20% of breast volume are not suitable for this technique. Cosmetic outcomes are generally very positive [34].

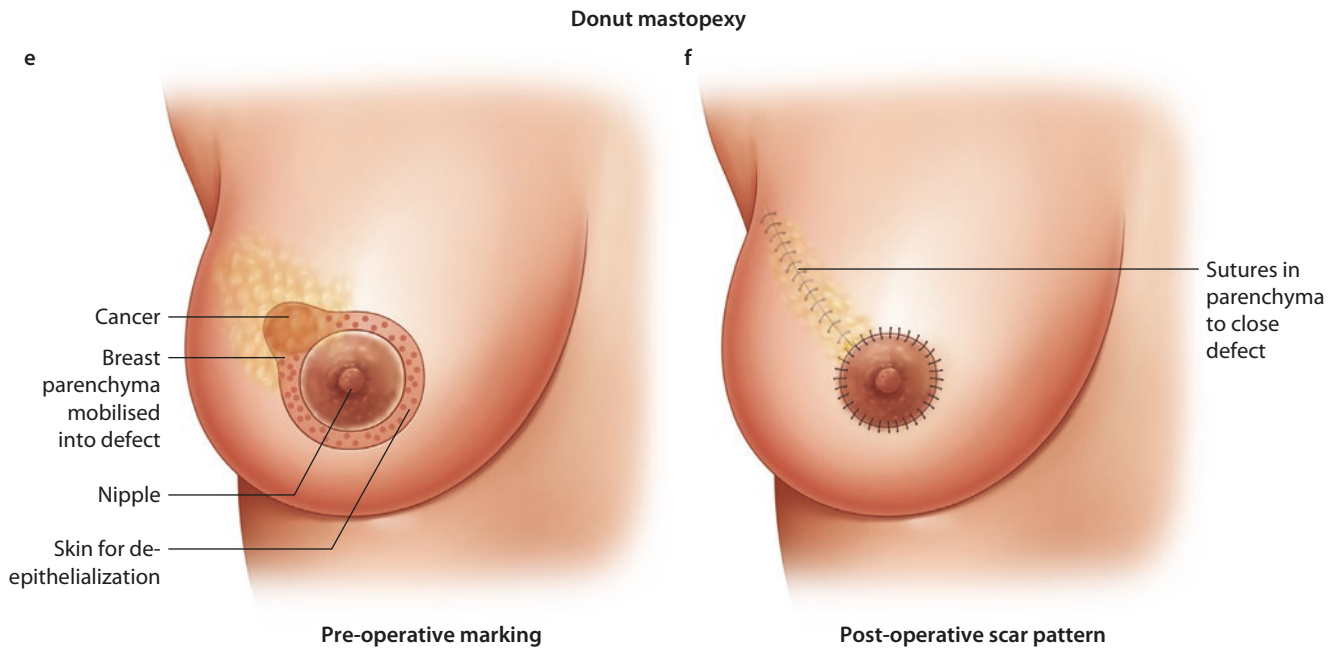
Batwing mastopexy



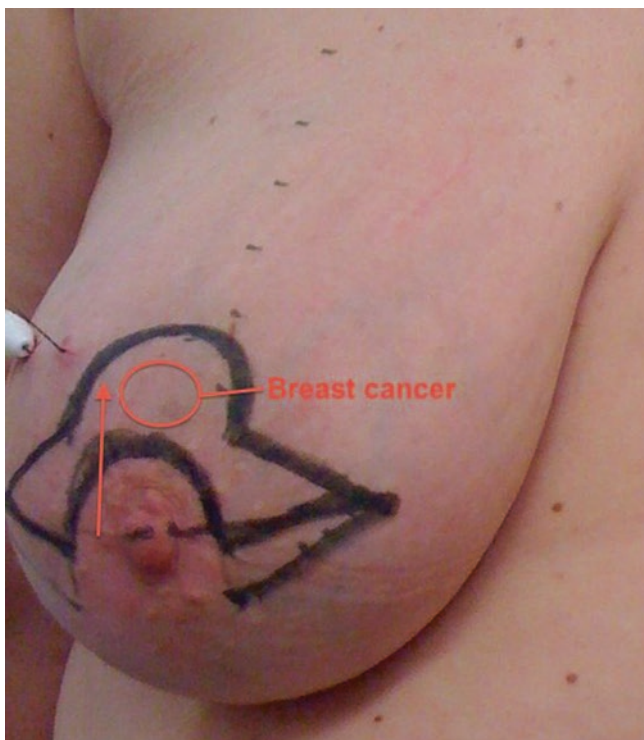Grissotti Mastopexy



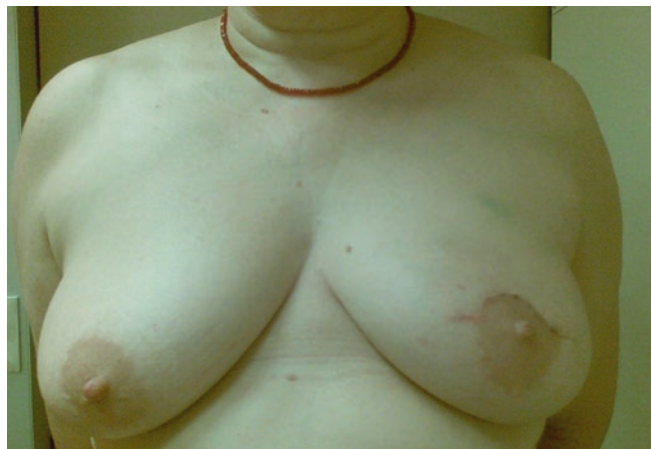**Fig. 19.4** Batwing mastopexy. **a** Preoperative marking. **b** Post-operative scar pattern. Grissotti mastopexy. **c** Preoperative marking. **d** Post-operative scar pattern. Doughnut mastopexy. **e** Preoperative marking. **f** Post-operative scar pattern, Sutures in parenchyma to close defect



■ Fig. 19.4 (continued)



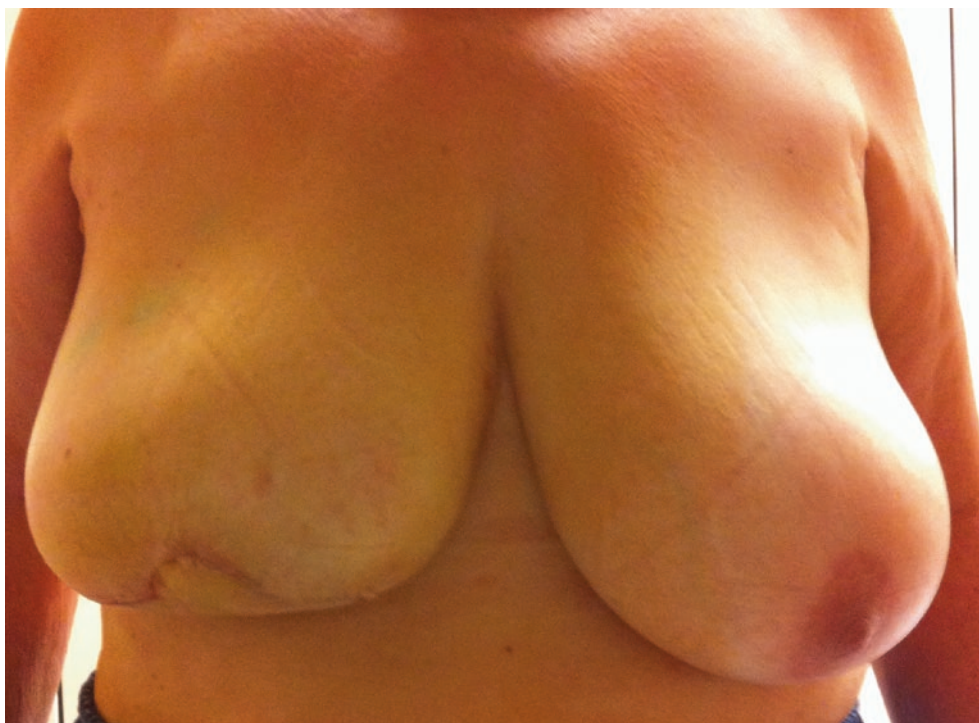■ Fig. 19.5 Preoperative marking of a batwing mastopexy for a tumour located in the 12.00 position



■ Fig. 19.6 Post-operative outcome of a batwing mastopexy for a tumour located in the 12.00 position



■ Fig. 19.7 Flattening of the breast mound due to higher-volume resection with a batwing mammoplasty



### 19.6.5 Doughnut Mastopexy

The doughnut technique is based on a circum-areolar incision and de-epithelialisation of the epidermis around the nipple-areola complex. The diameter of the de-epithelialised area may be chosen based on the planned resection volume and breast size. Breast tumours in any location, even behind the nipple, may be resected with this technique. It is an appropriate technique for smaller- to medium-sized breasts and more peripherally located breast tumours. Morbidity is low and cosmesis is usually excellent with a periareolar scar (■ Fig. 19.8a–f). The size of the areola may change after surgery and may necessitate contralateral adjustment. The doughnut technique is easy to learn and has a very low morbidity rate.

### 19.6.6 Round Block Mastopexy

A modification of the doughnut technique is the round block technique. Without de-epithelialisation, the nipple-areola complex is circumcised completely, and the breast tissue is separated from the skin above the tumour (■ Fig. 19.9a–d) [35]. The round block must not be used for centrally located tumours. It gives similarly excellent results to the doughnut technique.

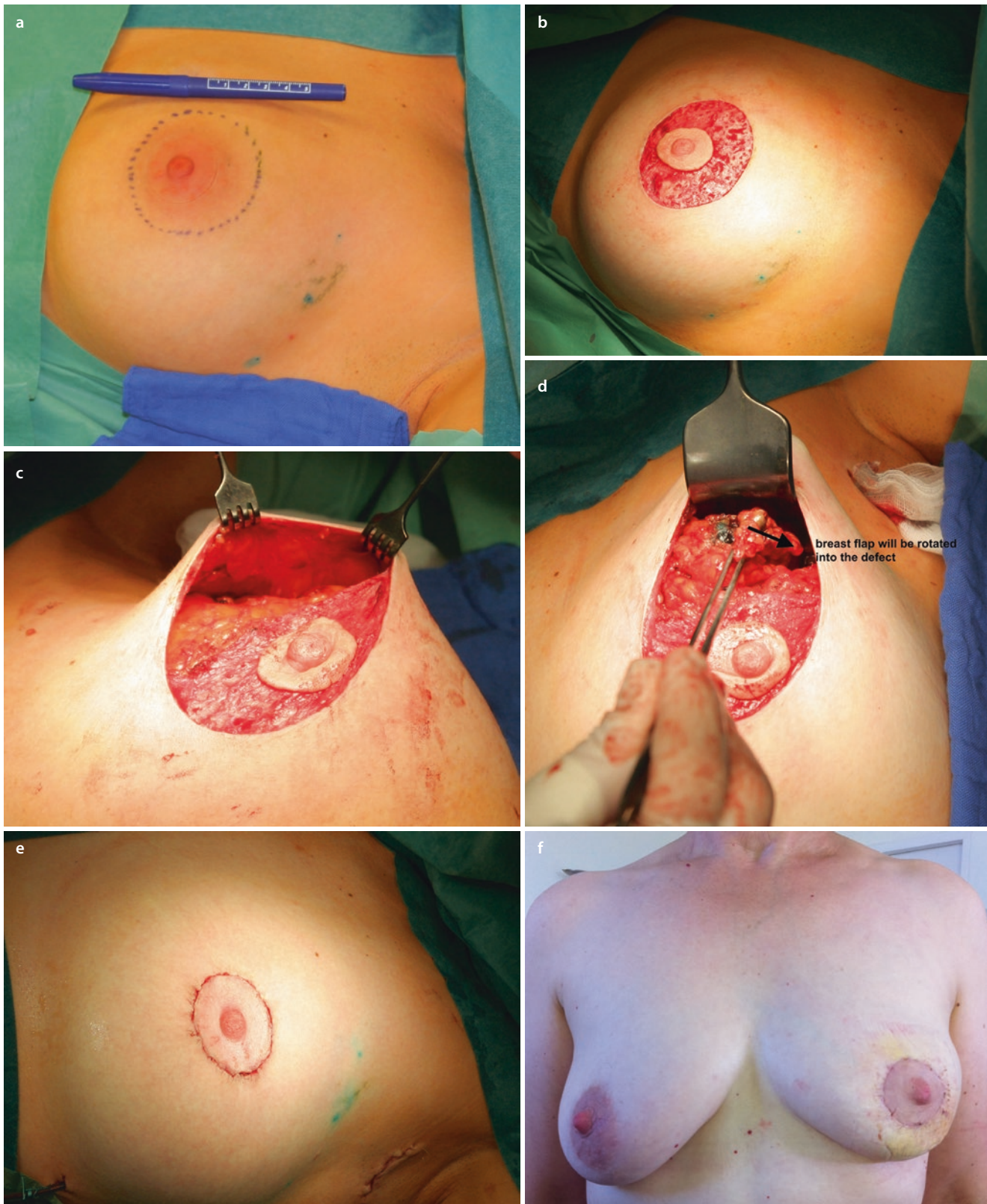### 19.7 Technical Atlas of Level 2 Techniques

In cases of large or ptotic breasts with an estimated resection volume of more than 25%, level 1 techniques will not achieve satisfactory results. Thus, therapeutic mammoplasty techniques (ThMP) with nipple-areola complex transfer and larger scars are necessary to close the defect after lumpectomy. There are a wide range of level 2 oncoplastic techniques. These may be adapted to deal with tumours in each quadrant, and there are now well-established protocols for how to deal with each site as shown in ■ Fig. 19.3. Examples of when to use these techniques are given below in a series of vignettes.

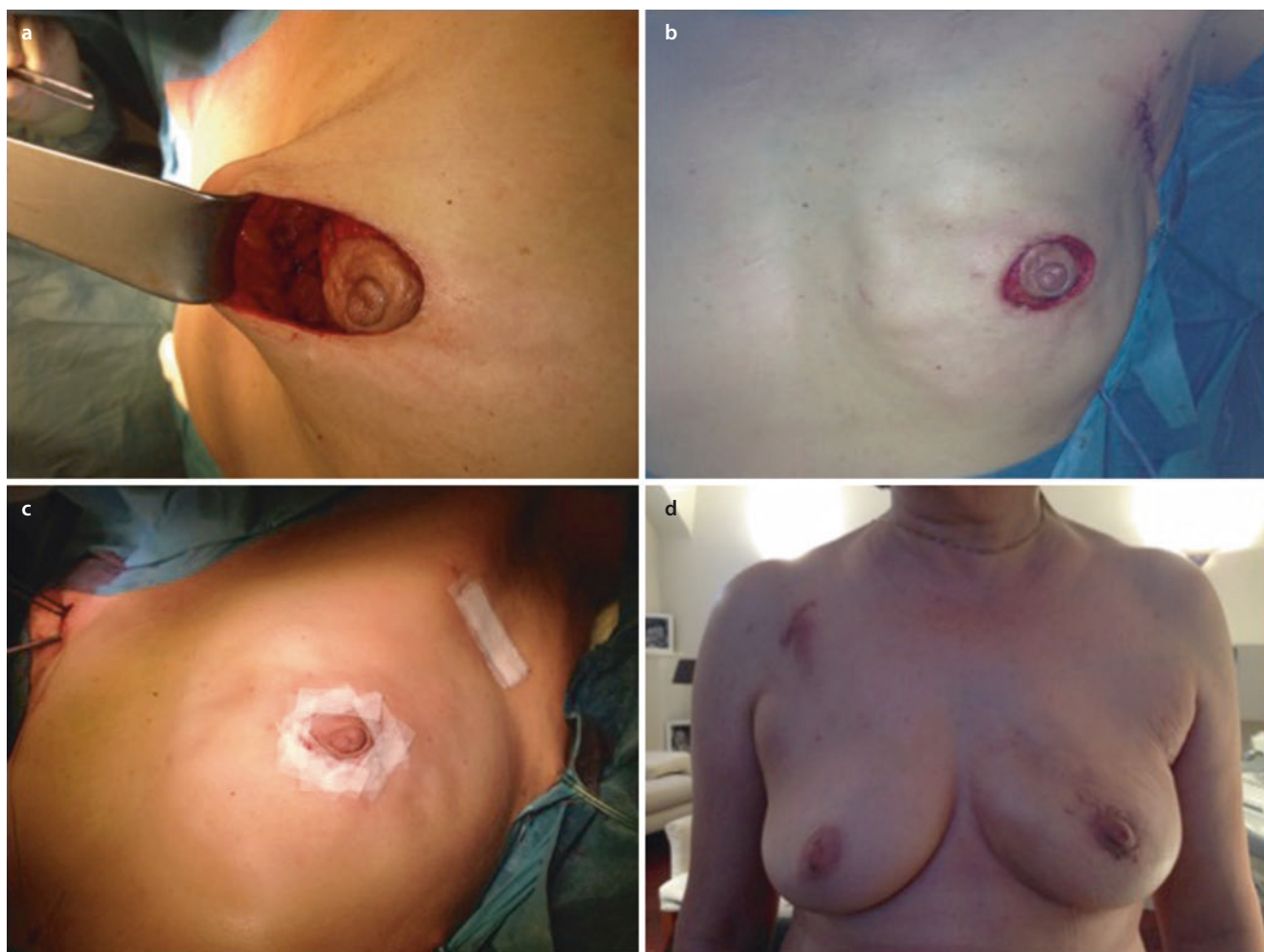For many of these techniques, the nipple is repositioned with a vascularised pedicle, which may arise either inferiorly, superomedially, superolaterally, superiorly or even a combination of several pedicles (e.g. which may be of value in higher-risk cases such as previous radiotherapy, diabetes, smoking, previous scarring). The vascular robustness of these various pedicle origins has been well described by O'Dey and colleagues [36]. A standard mammoplasty technique may have to be modified by adjusting the pedicle position to avoid a pre-existing scar or the tumour so it is important that surgeons are familiar with the principles of pedicle vascularity.

1. *Inverted T inferior/central pedicle oncoplastic technique (suitable for a superiorly sited cancer medial or lateral)*





**Fig. 19.8** Stages of a doughnut mastopexy procedure. **a** Marking up. **b** De-epithelialisation. **c** Resection of tumour. **d** Mobilisation of breast parenchyma to fill defect. **e** Suture of the skin to tighten skin envelope. **f** Early post-operative result



**Fig. 19.9** Stages of a round block technique. **a** Full circumcised of the areolar and access to the breast parenchyma for tumour resection. **b** Parenchymal mobilisation to close the defect. **c** Skin closure. **d** Early post-operative result

Figure 19.10a–f shows a patient with a 2 cm superomedially sited breast cancer and large ptotic breasts, undergoing a simultaneous wise pattern therapeutic mammoplasty and symmetrisation to the other breast. A typical wise pattern skin marking was performed preoperatively (Fig. 19.10a). The pedicle and periareolar skin are then de-epithelialised (Fig. 19.10c). The superior skin flap is then elevated, and a tumour in any superiorly sited location can be removed and the parenchyma reapposed (Fig. 19.10d, e). The whole is then closed as a standard wise pattern breast reduction (Fig. 19.10f). A description of standard wise pattern marking is given in Fig. 19.11.

## 2. The vertical Hall Findlay oncoplastic technique with a medial pedicle (suitable for a central breast cancer)

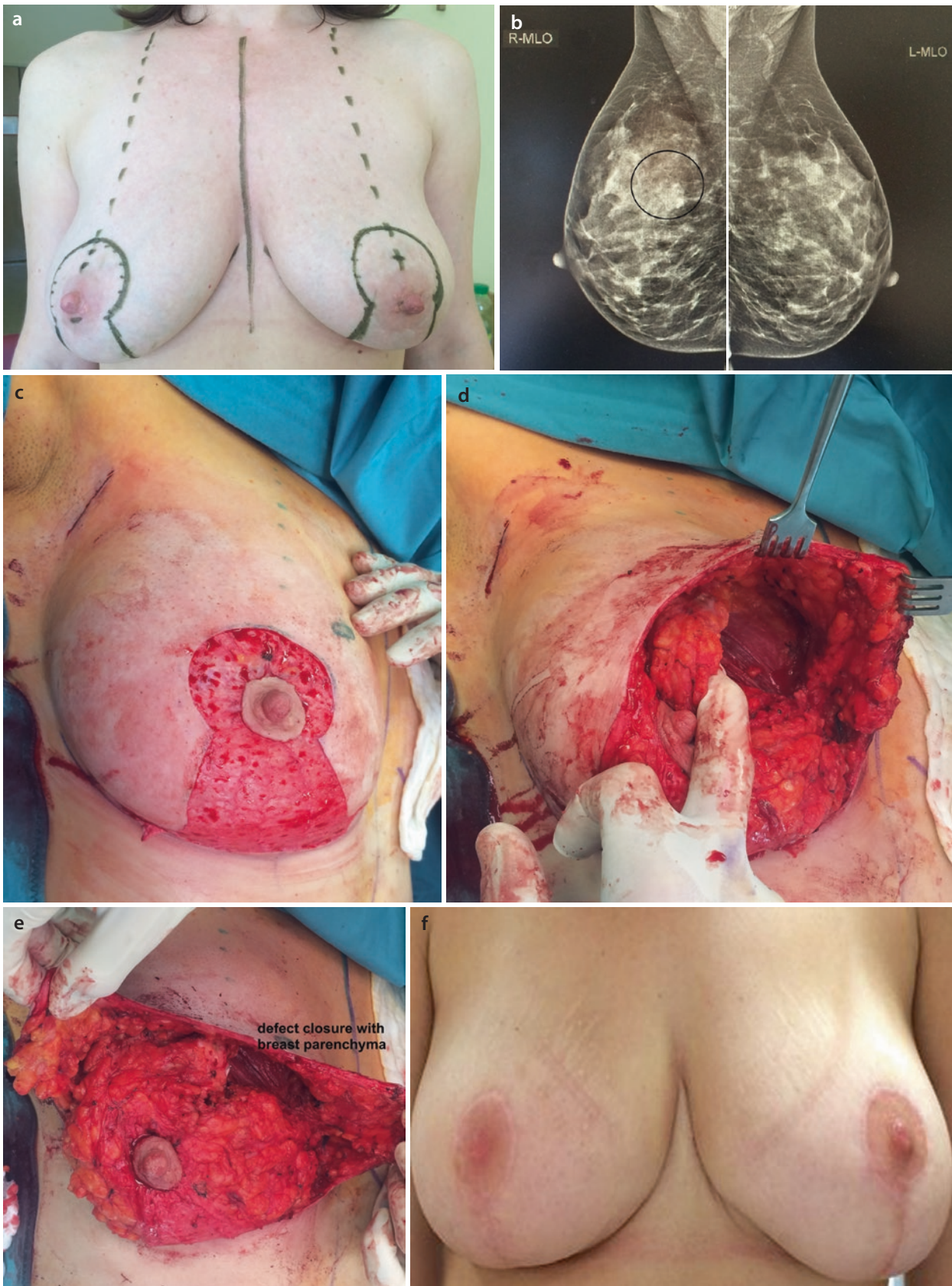For a centrally located breast cancer, there are several options such as the batwing, the Grisotti or the modified Hall Findlay technique [37]. The latter may be used for medium-sized breasts with or without ptosis. The nipple-areola complex has its pedicle from the central and medial part of the breast (Fig. 19.12a, b). After de-epithelialisation of the medial

pedicle, the dermis from the lateral as well as the caudal area is completely excised, and the skin is lifted from the breast parenchyma. The new nipple-areola complex is left as a skin island below the true nipple-areola complex, and after resection of the breast cancer with the nipple, the neo-areola is rotated into the defect. Parenchymal sutures are used to improve defect closure and the skin is closed (Fig. 19.12c, d), and Fig. 19.12e shows the final result. This technique belongs to the vertical scar group of techniques and may not be used in large breasts as rates of local skin morbidity such as necrosis and infection increase with larger breast volumes.

## 3. Vertical scar technique with a superior pedicle (Lejour) (suitable for an inferiorly located breast cancer medial or lateral)

This technique may be used in medium-sized breasts with or without ptosis. It should be used if the breast has to be lifted up and there is enough tissue to be rotated into the defect. Otherwise, the doughnut technique would be adequate. Fig. 19.13a shows the typical indication. The breast with the cancer is larger and slightly lower than the other side.





**Fig. 19.10** Sequence showing an inverted T mammoplasty for a woman with large ptotic breasts and a 2 cm tumour in the superomedial quadrant. **a** Preoperative marking. **b** Mammogram showing 2 cm

tumour. **c** De-epithelialisation of the inferior pedicle. **d** Demonstration of the tumour defect following excision. **e** Closure of the parenchymal defect. **f** Late post-operative result

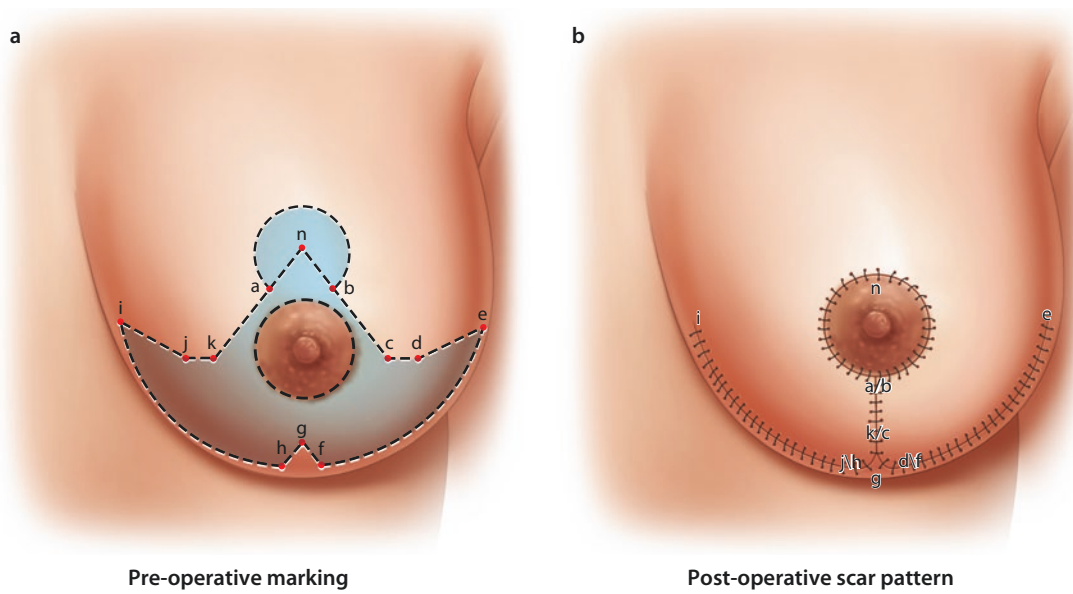


Fig. 19.11 Marking up of a standard inverted T mastopexy

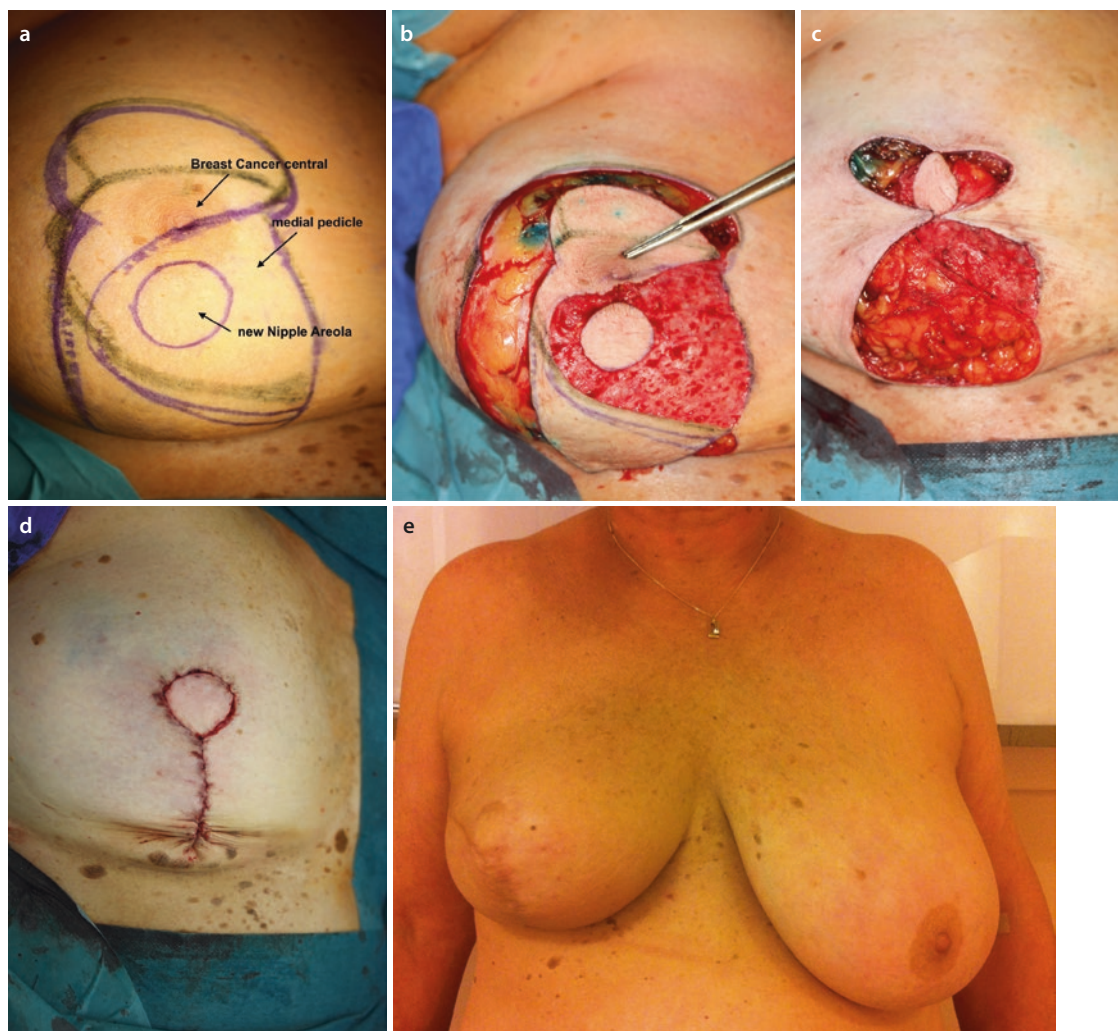
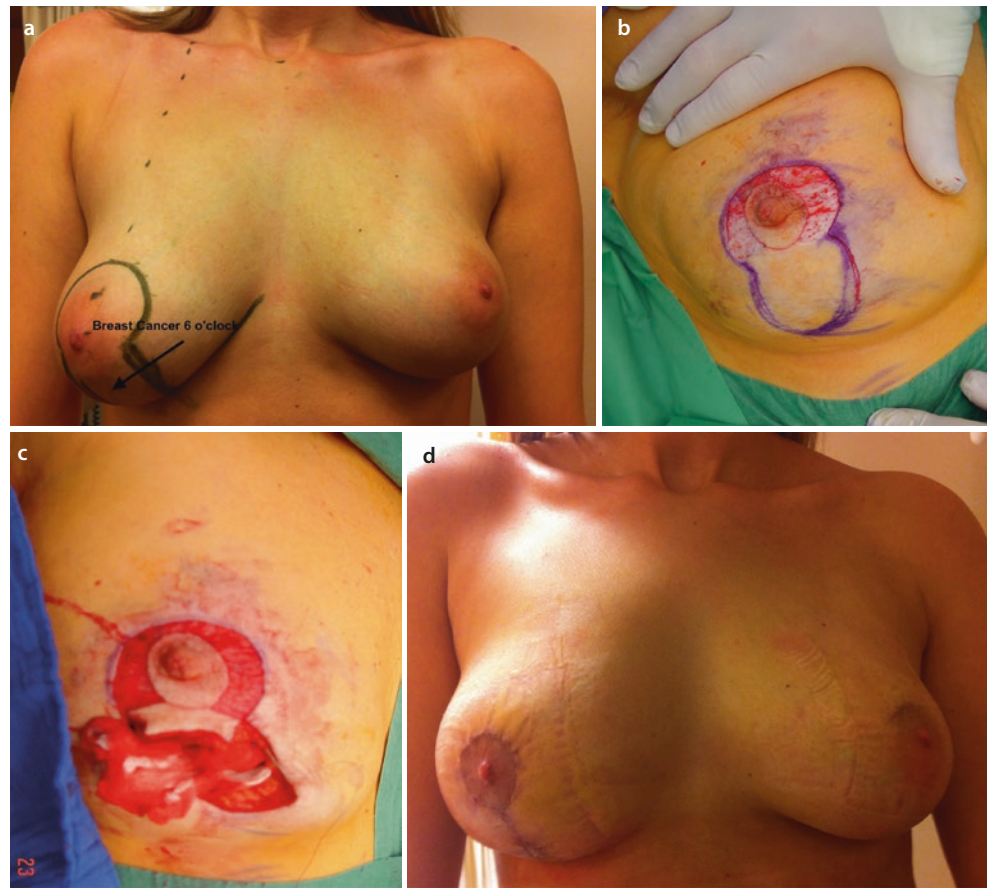
Fig. 19.12 Vertical Hall Findlay technique for a centrally located tumour. a Preoperative marking. b De-epithelialisation and tumour excision. c Breast reconstitution. d Skin closure. e Long-term post-operative result



**Fig. 19.13** Vertical scar mastopexy with superior pedicle (Lejour). **a** Preoperative markup. **b** De-epithelialisation. **c** Tumour resection. **d** Late post-operative result



However, the breast is medium sized, and the skin is firm so there is no need for a large skin resection for mastopexy. After the epidermis has been removed around the nipple, the dermis is incised (■ Fig. 19.13b, c), and the breast cancer at the 6 o'clock position may be resected together with the overlying skin. After closure, the breast has been lifted upwards, and the defect is completely closed (■ Fig. 19.13d). If there is a large amount of skin to be resected, this technique can be combined with an inverted T incision.

There are numerous other techniques for details of which the reader may consult any one of a number of excellent books and papers.

## 19.8 Relative Contraindications for Oncoplastic Surgery

### 19.8.1 Contraindications

There are oncologic and cosmetic contraindications for oncoplastic surgery. Oncologic contraindications are similar to those for breast conservation and should follow international guidelines such as the St. Gallen guidelines [38]. Whilst it is considered appropriate for multifocal and multicentric cancer to be treated with conservation surgery provided clear margins are possible (■ Table 19.1), the evidence for conservation surgery for multicentric cancers is still relatively weak.

**Table 19.1** Results of voting at the 2013 St. Gallen International Breast Consensus meeting regarding whether a range of controversial clinical scenarios would be viewed as a contraindication to breast conservation surgery

	Yes (%)	No (%)	? (%)
Extensive microcalcification	20	74	6
Multifocality	7	89	4
Multicentricity	30	65	5
Close to nipple-areolar complex	0	96	4

Goldhirsch et al. [38]

There is emerging evidence that BCT in multifocal disease is oncologically safe [39], but it may result in a slightly inferior outcome compared with BCT in unifocal breast cancer, and patients in the MF group may have higher 10-year LRR (0.6% vs. 6.1%,  $p < 0.001$ ) [8]. Other authors share the same view, stating that based on historical data, it is expected the local recurrence rates will be somewhat higher but that there will be little or no impact on survival [40]. However, attention is drawn to the hypothesis that MF/MC tumours may have a worse biological behaviour and that the presence of multiple foci should be considered in planning adjuvant treatments [41]. It seems that there is enough evidence to justify a randomised trial [42].

**Table 19.2** Table showing rates of morbidity following standard breast conservation surgery (BCT), types 1 and 2 oncoplastic surgery (iTOP 1/2) and breast reconstructive surgery (iTOP 3) (F Fitzal, unpublished data)

	Seroma	Bleeding	Necrosis	Infection
BCT (N = 71)	9(12%)	2(3%)	0	1(1.5%)
iTOP 1 or 2 (N = 37)	6(16%)	4(11%)	4(11%)	4(11%)
iTOP 3 (N = 27)	1(4%)	0	4(15%)	1(4%)

*BCT* breast conservation therapy, *iTOP 1 or 2* oncoplastic type 1 or 2, *iTOP 3* mastectomy and immediate reconstruction. Prospective non-randomised observational study (unpublished interim analysis)

If conservation is unlikely to result in a good cosmetic outcome, even with the use of an oncoplastic procedure, a recommendation for neoadjuvant therapy or immediate mastectomy, based on the tumour biology, may be more appropriate. Usually multicentric invasive lobular disease is not ideal for an oncoplastic procedure due to the higher risk of margin involvement due to the diffuse spreading nature of this subtype. Patients with recurrent cancer following BCS and adjuvant whole breast radiotherapy are at high risk for complications from oncoplastic surgery due to a high risk of fat necrosis and vascular insufficiency of the pedicle and wound edges due to the previous radiotherapy.

There are some relative contraindications such as comorbidities like diabetes, heavy smoking and obesity. Patients have to be aware that they have an increased risk of local morbidity after oncoplastic surgery. A recent prospective observational study of oncoplastic surgery techniques (iTOP NCT01396993) investigated 30-day morbidity rates after surgery (Table 19.2). This has demonstrated that bleeding, necrosis and infections are increased up to tenfold after oncoplastic breast-conserving surgery in some cases.

## 19.9 Cosmetic Outcomes

The cosmetic appearance of the breast after BCT depends on the relative proportion of breast volume excised and on the location of the tumour within the breast [43]. However, assessing cosmetic outcomes is complex. Initial attempts to quantify cosmesis were entirely subjective, simply using phrases such as «excellent» [44]. The subjective opinion of the surgeon was the norm in early series [14] with little consideration being given to the opinion of the patient [45]. However, it was soon realised that the opinion of the patient and the judgement of independent clinicians might be of more value and objectivity and be less biased. The role of psychological factors from a patient's perspective was also recognised to be important.

There is no better example on the above interference than the findings of Sackey and colleagues [46] who report that

women with mastectomy and immediate reconstruction for DCIS reported better physical functioning and less bodily pain not only compared to women who had just undergone wide local excision with or without radiotherapy but also from age-adjusted healthy women. The authors explained this by the so-called response shift, which is an adaptation process whereby patients with a severe disease accommodate their illness. During this process, internal values are changing, and conceptualisation of quality of life alters. To make cosmetic assessment even more complex, Nahabedian and colleagues [47], in an editorial, add the «age» parameter, assuming that breast reconstruction is an important consideration for most, if not all, patients less than or equal to 30 years of age and that it is an important aspect of their psychological well-being and body image. However, it is difficult for someone to understand why the authors' assumption does not equally apply to women older than 30 years.

All of the above give us insight into the difficulties of scientifically addressing questions on the aesthetic result of an operation and its advantages or disadvantage over other operations [48]. With the introduction of objective analysis tools, early data (e.g. using the Breast Analysing Tool (BAT<sup>®</sup>)) is that oncoplastic surgery seems to improve symmetry [49]. Other attempts which include a semiautomated breast cancer conservative treatment.cosmetic results (BCCT.core) software have been presented [50, 51] which agreed to the patients' evaluation by BCTOS (Breast Cancer Treatment Outcomes Scale) in a range between 35% and 44%. Interestingly the patients judged their aesthetic outcome more positively than the software. The authors concluded that objective measurements and patients' perspectives evaluate similar dimensions differently and that it seems necessary to apply both approaches in order to gain a more comprehensive knowledge of breast aesthetics. No matter how objectively doctors measure breast symmetry, it seems that it is not a major factor for a patient's quality of life and breast self-esteem. Patients consider the oncological outcome of the disease as of primary importance [52]. That is probably why Metcalfe and colleagues [53] found no differences in psychosocial functioning at 1 year between women who had undergone mastectomy alone and those undergoing mastectomy and immediate or delayed reconstruction. They conclude that women need further support after breast cancer diagnosis even if they have breast reconstruction.

In general, patient's opinion and satisfaction are of most importance and address not only the shape and feeling of the breast (both alone and in comparison to the contralateral breast) but also its influence on the quality of life of the patient.

Finally, it is important to be aware that the aesthetic result may change with time, and whilst the majority of women feel they have acceptable results at 6 months post-operatively [33], the impact of scarring contracture and radiotherapy may lead to suboptimal results at 5 or even 10 years of follow-up [47], and these long-term evaluations should be reported alongside oncological outcomes [33].

In summary, to date, no prospective controlled trial has demonstrated that oncoplastic surgery may improve objective breast cosmesis and thus long-term quality of life. The ongoing iTOP trial (■ Table 19.2) institute might be able to shed some light onto this issue. Early data will be available shortly.

## References

- Rainsbury RM. Surgery insight: Oncoplastic breast-conserving reconstruction--indications, benefits, choices and outcomes. *Nat Clin Pract Oncol*. 2007;4(11):657–64.
- Clough KB, Kaufman GJ, Nos C, Buccimazza I, Sarfati IM. Improving breast cancer surgery: a classification and quadrant per quadrant atlas for oncoplastic surgery. *Ann Surg Oncol*. 2010;17(5):1375–91.
- Cardoso MJ, Macmillan RD, Merck B, Munhoz AM, Rainsbury R. Training in oncoplastic surgery: an international consensus. The 7th Portuguese Senology congress, Vilamoura, 2009. *Breast*. 2010;19(6):538–40.
- Cutress RI, Summerhayes C, Rainsbury R. Guidelines for oncoplastic breast reconstruction. *Ann R Coll Surg Engl*. 2013;95(3):161–2.
- Yunaev M, Hingston G. Oncoplastic breast surgery in Australia and New Zealand-2014 and beyond. *Gland Surg*. 2014;3(1):77–80.
- Cochrane RA, Valasiadou P, Wilson AR, Al-Ghazal SK, Macmillan RD. Cosmesis and satisfaction after breast-conserving surgery correlates with the percentage of breast volume excised. *Br J Surg*. 2003;90(12):1505–9.
- Vila J, Garcia-Etienne CA, Vavassori A, Gentilini O. Conservative surgery for ipsilateral breast tumor recurrence. *J Surg Oncol*. 2014;110(1):62–7.
- Chung AP, Huynh K, Kidner T, Mirzadehgan P, Sim MS, Giuliano AE. Comparison of outcomes of breast conserving therapy in multifocal and unifocal invasive breast cancer. *J Am Coll Surg*. 2012;215(1):137–46. discussion 46–7
- Yerushalmi R, Tyldesley S, Woods R, Kennecke HF, Speers C, Gelmon KA. Is breast-conserving therapy a safe option for patients with tumor multicentricity and multifocality? *Ann Oncol*. 2012;23(4):876–81.
- Tan MP, Sitoh NY, Sitoh YY. Optimising breast conservation treatment for multifocal and Multicentric breast cancer: a worthwhile Endeavour? *World J Surg*. 2016;40(2):315–22.
- Macmillan RD, James R, Gale KL, McCulley SJ. Therapeutic mammoplasty. *J Surg Oncol*. 2014;110(1):90–5.
- Hernanz F, Regano S, Vega A, Gomez FM. Reduction mammoplasty: an advantageous option for breast conserving surgery in large-breasted patients. *Surg Oncol*. 2010;19(4):e95–e102.
- McIntosh J, O'Donoghue JM. Therapeutic mammoplasty--a systematic review of the evidence. *Eur J Surg Oncol*. 2012;38(3):196–202.
- Clough KB, Lewis JS, Couturaud B, Fitoussi A, Nos C, Falcou MC. Oncoplastic techniques allow extensive resections for breast-conserving therapy of breast carcinomas. *Ann Surg*. 2003;237(1):26–34.
- Piper ML, Esserman LJ, Sbitany H, Peled AW. Outcomes following Oncoplastic reduction mammoplasty: a systematic review. *Ann Plast Surg*. 2016;76(Suppl 3):S222–6.
- De La Cruz L, Blankenship SA, Chatterjee A, Geha R, Nocera N, Czerniecki BJ, et al. Outcomes after Oncoplastic breast-conserving surgery in breast cancer patients: a systematic literature review. *Ann Surg Oncol*. 2016;23(10):3247–58.
- Chakravorty A, Shrestha AK, Sanmugalingam N, Rapisarda F, Roche N, Querci Della Rovere G, et al. how safe is oncoplastic breast conservation? Comparative analysis with standard breast conserving surgery. *Eur J Surg Oncol*. 2012;38(5):395–8.
- Rietjens M, Urban CA, Rey PC, Mazzarol G, Maisonneuve P, Garusi C, et al. Long-term oncological results of breast conservative treatment with oncoplastic surgery. *Breast*. 2007;16(4):387–95.
- Morrogh M, Borgen PI, King TA. The importance of local control in early-stage breast cancer: a historical review and a discussion of ongoing issues. *Ann Surg Oncol*. 2007;14(12):3310–20.
- Moran MS, Schnitt SJ, Giuliano AE, Harris JR, Khan SA, Horton J, et al. Society of Surgical Oncology-American Society for Radiation Oncology consensus guideline on margins for breast-conserving surgery with whole-breast irradiation in stages I and II invasive breast cancer. *J Clin Oncol*. 2014;32(14):1507–15.
- Thill M, Baumann K, Barinoff J. Intraoperative assessment of margins in breast conservative surgery--still in use? *J Surg Oncol*. 2014;110(1):15–20.
- Strnad V, Hannoun-Levi JM, Guinot JL, Lossl K, Kauer-Dorner D, Resch A, et al. Recommendations from GEC ESTRO breast cancer working group (I): target definition and target delineation for accelerated or boost partial breast irradiation using multicatheter interstitial brachytherapy after breast conserving closed cavity surgery. *Radiother Oncol*. 2015;115(3):342–8.
- Major T, Gutierrez C, Guix B, van Limbergen E, Strnad V, Polgar C, et al. Recommendations from GEC ESTRO breast cancer working group (II): target definition and target delineation for accelerated or boost partial breast irradiation using multicatheter interstitial brachytherapy after breast conserving open cavity surgery. *Radiother Oncol*. 2016;118(1):199–204.
- NCPGI/BCV. Margin Status in Infiltrating Carcinoma (BINV-F). 2016.
- Volleamere AJ, Kirwan CC. National survey of breast cancer specimen orientation marking systems. *Eur J Surg Oncol*. 2013;39(3):255–9.
- Network. NBOCaC. The pathology reporting of breast cancer. A guide for pathologists, surgeons, radiologists and oncologists. 3rd ed. Surry Hills: National Breast Cancer Centre; 2008.
- Singh M, Singh G, Hogan KT, Atkins KA, Schroen AT. The effect of intraoperative specimen inking on lumpectomy re-excision rates. *World J Surg Oncol*. 2010;8:4.
- Patel J, Jenkins S. A technique for marking oncological breast tissue specimens. *Ann Med Surg (Lond)*. 2016;7:7–8.
- Vaidya JS, Wilson AJ, Choudhury R. Orientation of a breast specimen with radio-opaque thread--a novel solution. *Eur J Surg Oncol*. 2004;30(4):460–1.
- Molina MA, Snell S, Franceschi D, Jorda M, Gomez C, Moffat FL, et al. Breast specimen orientation. *Ann Surg Oncol*. 2009;16(2):285–8.
- Gradishar WJ, Anderson BO, Balassanian R, Blair SL, Burstein HJ, Cyr A, et al. Invasive breast cancer version 1.2016, NCCN clinical practice guidelines in oncology. *J Natl Compr Cancer Netw*. 2016;14(3):324–54.
- Azu M, Goyal S, Patel U, Haffty B, Kearney T. Has placement of surgical clips in the lumpectomy bed fallen out of favor? *Ann Surg Oncol*. 2011;18(6):1529–32.
- Losken A, Styblo TM, Carlson GW, Jones GE, Amerson BJ. Management algorithm and outcome evaluation of partial mastectomy defects treated using reduction or mastopexy techniques. *Ann Plast Surg*. 2007;59(3):235–42.
- Matkowski R, Szynglarewicz B, Kasprzak P, Forgacz J, Skalik R, Zietek M, et al. Batwing mastopexy as oncoplastic surgical approach to periareolar tumors in upper quadrants. *Tumori*. 2012;98(4):421–7.
- Zaha H, Onomura M, Unesoko M. A new scarless oncoplastic breast-conserving surgery: modified round block technique. *Breast*. 2013;22(6):1184–8.
- O'Dey D, Prescher A, Pallua N. Vascular reliability of nipple-areola complex-bearing pedicles: an anatomical microdissection study. *Plast Reconstr Surg*. 2007;119(4):1167–77.
- Fitzal F, Nehrer G, Hoch D, Riedl O, Gutharc S, Deutinger M, et al. An oncoplastic procedure for central and medio-cranial breast cancer. *Eur J Surg Oncol*. 2007;33(10):1158–63.
- Goldhirsch A, Winer EP, Coates AS, Gelber RD, Piccart-Gebhart M, Thurlimann B, et al. Personalizing the treatment of women with early breast cancer: highlights of the St Gallen international expert consensus on the primary therapy of early breast cancer 2013. *Ann Oncol*. 2013;24(9):2206–23.

39. Nijenhuis MV, Rutgers EJ. Conservative surgery for multifocal/multicentric breast cancer. *Breast*. 2015;24(Suppl 2):S96–9.
40. Silverstein MJ, Savalia N, Khan S, Ryan J. Extreme oncoplasty: breast conservation for patients who need mastectomy. *Breast J*. 2015;21(1):52–9.
41. Neri A, Marrelli D, Megha T, Bettarini F, Tacchini D, De Franco L, et al. Clinical significance of multifocal and multicentric breast cancers and choice of surgical treatment: a retrospective study on a series of 1158 cases. *BMC Surg*. 2015;15:1.
42. Winters ZE, Horsnell J, Schmid P, Jones JL, Shaaban A, Maxwell AJ, et al. Time for a randomised clinical trial evaluating breast conserving surgery compared to mastectomy in ipsilateral multifocal breast cancer (MFBC)? *Breast*. 2016;26:149–50.
43. White J, Achuthan R, Turton P, Lansdown M. Breast conservation surgery: state of the art. *Int J Breast Cancer*. 2011;2011:107981.
44. Clough KB, Kroll SS, Audretsch W. An approach to the repair of partial mastectomy defects. *Plast Reconstr Surg*. 1999;104(2):409–20.
45. Asgeirsson KS, Rasheed T, McCulley SJ, Macmillan RD. Oncological and cosmetic outcomes of oncoplastic breast conserving surgery. *Eur J Surg Oncol*. 2005;31(8):817–23.
46. Sackey H, Sandelin K, Frisell J, Wickman M, Brandberg Y. Ductal carcinoma in situ of the breast. Long-term follow-up of health-related quality of life, emotional reactions and body image. *Eur J Surg Oncol*. 2010;36(8):756–62.
47. Nahabedian MY, Ellsworth WA, Bass BL, Skoracki RJ, Heller L. Breast reconstruction in women under 30: a 10-year experience. *Breast J*. 2011;17(1):1–2.
48. Gonzalez EG, Rancati AO. Skin-sparing mastectomy. *Gland Surg*. 2015;4(6):541–53.
49. Fitzal F, Mittlboeck M, Trischler H, Krois W, Nehrer G, Deutinger M, et al. Breast-conserving therapy for centrally located breast cancer. *Ann Surg*. 2008;247(3):470–6.
50. Heil J, Carolus A, Dahlkamp J, Golatta M, Domschke C, Schuetz F, et al. Objective assessment of aesthetic outcome after breast conserving therapy: subjective third party panel rating and objective BCCT.Core software evaluation. *Breast*. 2012;21(1):61–5.
51. Heil J, Dahlkamp J, Golatta M, Rom J, Domschke C, Rauch G, et al. Aesthetics in breast conserving therapy: do objectively measured results match patients' evaluations? *Ann Surg Oncol*. 2011;18(1):134–8.
52. Exner R, Krois W, Mittlboeck M, Dubsy P, Jakesz R, Gnant M, et al. Objectively measured breast symmetry has no influence on quality of life in breast cancer patients. *Eur J Surg Oncol*. 2012;38(2):130–6.
53. Metcalfe KA, Semple J, Quan ML, Vadaparampil ST, Holloway C, Brown M, et al. Changes in psychosocial functioning 1 year after mastectomy alone, delayed breast reconstruction, or immediate breast reconstruction. *Ann Surg Oncol*. 2012;19(1):233–41.