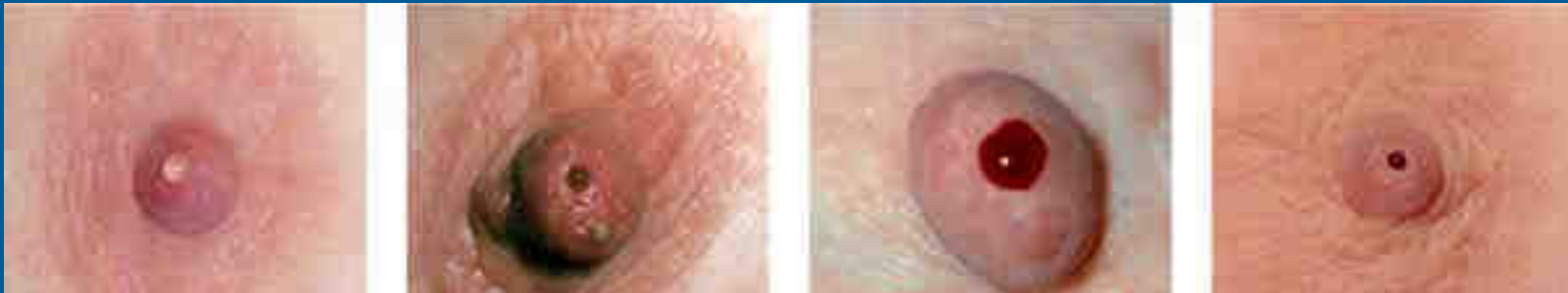



Epworth

Nipple Discharge



Epworth Healthcare
Benign Breast Disease Symposium
November 12th 2016

Jane O'Brien
Specialist Breast and Oncoplastic Surgeon

What is Nipple Discharge?

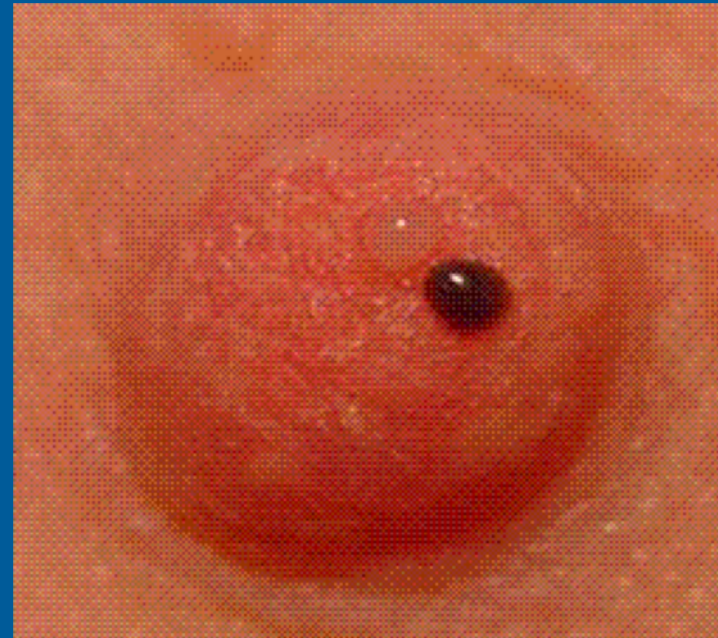
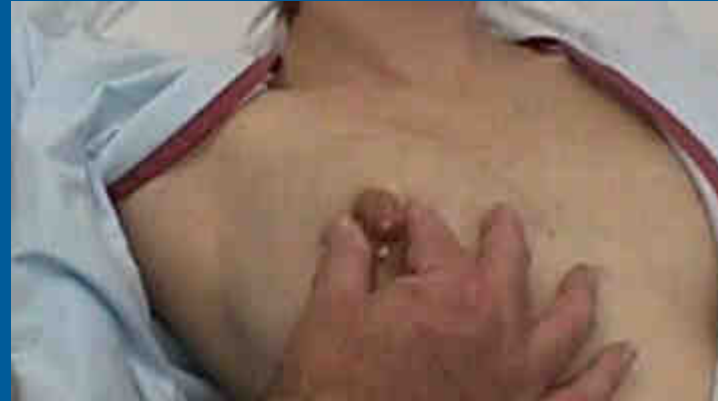
Epworth

Nipple discharge is the release of fluid from the nipple

Based on the characteristics of presentation Nipple Discharge is categorized as:

- Physiologic nipple discharge
- Normal milk production (lactation)
- Pathologic nipple discharge





- Nipple discharge is the one of the most commonly encountered breast complaints
- 5-10% percent of women referred because of symptoms of a breast disorder have nipple discharge
- Nipple discharge is the third most common presenting symptom to breast clinics (behind lump/lumpiness and breast pain)
- Most nipple discharge is of benign origin



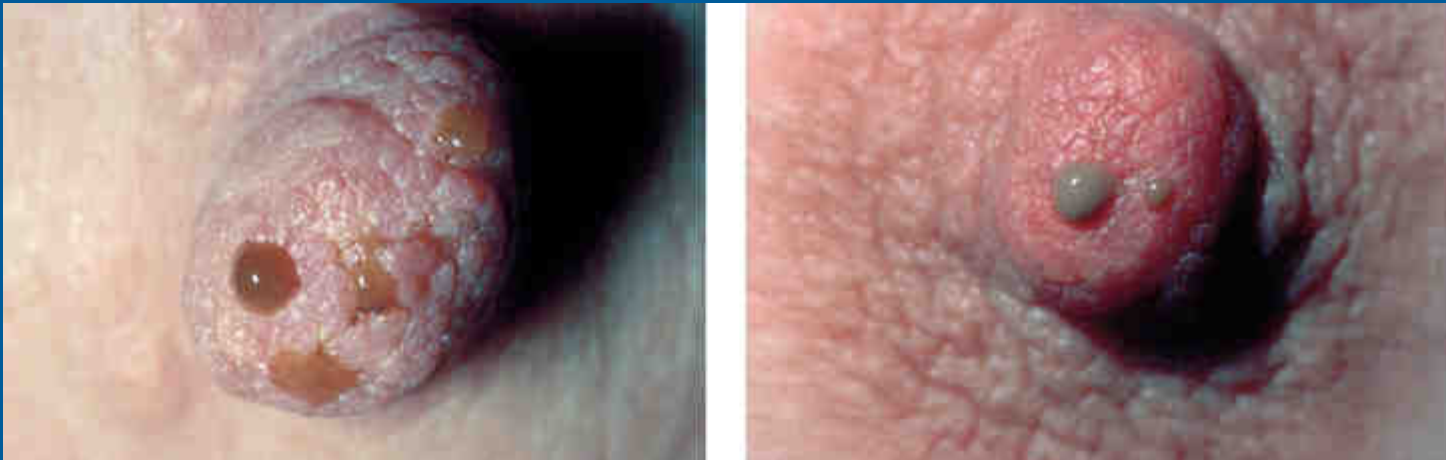- Less than 5% of women with breast cancer have nipple discharge, and most of these women have other symptoms, such as a lump or newly inverted nipple, as well as the nipple discharge
- Mammography and ultrasound have a low sensitivity and specificity for diagnosing the cause of nipple discharge
- Nipple smear cytology has a low sensitivity and positive predictive value
- The risk of an underlying malignancy is increased if the nipple discharge is spontaneous and single duct

Physiological Nipple Discharge



Epworth

- Fluid can be obtained from the nipples of 50-80% of asymptomatic women when massage/squeezing used.
- This discharge of fluid from a normal breast is referred to as 'physiological discharge'
- It is usually yellow, milky, or green in appearance; does not occur spontaneously; and can be seen originating from multiple ducts.
- Physiological nipple discharge is no cause for concern
- Such discharge can often be noted after breast compression for mammography



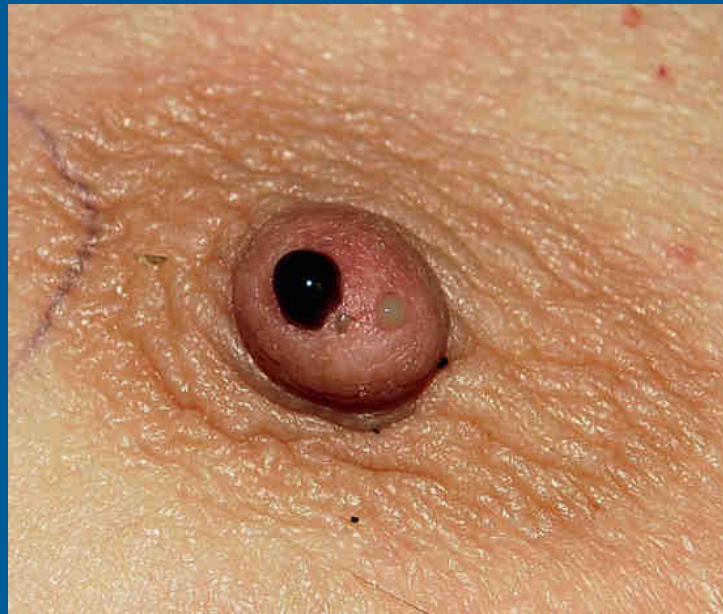27-Jun-20

Treatment of Physiological Nipple Discharge



Epworth

- Reassure
- Nipple discharge diagnosed as 'physiological discharge' requires no treatment
- The patient who is curious to check for discharge may cause continuous mechanical stimulation
- These women should be advised to avoid checking themselves for discharge, to stop expressing, or squeezing the nipple and breast
- In such cases, discontinuation of the stimulation will discontinue the discharge



Nipple Discharge

Westmead Breast Cancer Institute



Epworth

What is nipple discharge?

Nipple discharge is the release of fluid from the nipple. It is a very common breast symptom and in most cases is part of the normal function of the breast rather than being caused by a problem. Nipple discharge alone (without a lump or other nipple change) is a very uncommon symptom of breast cancer. There are normally 15-20 milk ducts opening onto each nipple. Discharge can come from one or a number of these ducts.

What are the features of nipple discharge?

Nipple discharge may be:

- > Spontaneous (fluid leaks from the breast without any squeezing of the nipple or pressure on the breast); or
- > On expression (fluid only comes out of the nipple when the nipple is squeezed or there is pressure on the breast).

Other questions which can be used to describe nipple discharge include:

- > Is it coming from one breast (unilateral) or coming from both breasts (bilateral)?
- > Is it coming from one duct (one opening on the nipple) or more than one?
- > What colour is it? Nipple fluid is most often yellow, green or milky. This is not usually a cause for concern. Discharge that is blood-stained (bright red), brown or crystal clear can be more significant. If it is difficult to tell what colour it is, then putting some fluid onto a white tissue can help.

Normal hormonal nipple discharge

Nipple discharge is very common. Fluid can be obtained from the nipples of approximately 50-70% of normal women when special techniques, massage, or devices such as breast pumps are used. This discharge of fluid from a normal breast is referred to as 'physiological discharge'.

This discharge is usually yellow, milky, or green in appearance, it does not happen spontaneously, and it can often be seen to be coming from more than one duct. Physiological nipple discharge is no cause for concern.

Milky nipple discharge (either spontaneous or on expression) is also normal (physiological) during pregnancy and breast feeding.



When is nipple discharge abnormal?

Spontaneous nipple discharge unrelated to pregnancy or breast feeding is considered abnormal. In most cases it has a non-cancerous (benign) cause. Spontaneous nipple discharge that is caused by disease (pathology) in the breast is more likely to be from one breast only (unilateral), confined to a single duct, and clear or blood-stained in appearance.

Nipple discharge that is associated with other symptoms such as a lump in the breast or ulceration or inversion of the nipple needs prompt investigation, even if it is not spontaneous or blood-stained.

What causes abnormal nipple discharge?

There are many causes of nipple discharge. These include:

Duct ectasia

This is a non-cancerous (benign) condition in which the milk ducts under the nipple enlarge and there is inflammation in the walls of the ducts. It usually occurs in women after menopause. The discharge caused by duct ectasia usually comes from both breasts (bilateral), is yellow, green or brown, and comes from more than one duct. In most cases, no treatment is needed. If the discharge is a nuisance, the ducts behind the nipple can be removed surgically.

Duct papilloma

A duct papilloma is a growth within a milk duct in the breast, usually near the nipple. It may cause no symptoms, or it may cause a nipple discharge that is clear or blood-stained. It usually comes from a single duct and is from one breast only (unilateral). Rarely, duct papillomas can be associated with breast cancer and they can be difficult to diagnose confidently on a needle biopsy so they are usually removed surgically.

Nipple eczema

Eczema or dermatitis which affects the skin of the nipple, particularly if it becomes infected, can cause a weeping, crusty nipple discharge. The treatment is the same as for eczema elsewhere on the body, with cortisone-based creams the main first-line treatment.

Breast cancer

Breast cancer is an uncommon cause of nipple discharge. Less than 5% of women with breast cancer have nipple discharge, and most of these women have other symptoms, such as a lump or newly inverted nipple, as well as the nipple discharge.

Paget's disease of the nipple

Paget's disease is a particular type of breast cancer which involves the nipple. Paget's disease typically causes ulceration and erosion of the nipple skin, and it may be associated with a blood-stained nipple discharge.

Hormonal causes

Galactorrhoea is milky nipple discharge not related to pregnancy or breast feeding. It is caused by the abnormal production of a hormone called prolactin. This can be caused by diseases of glands elsewhere in the body which control hormone secretion, such as the pituitary and thyroid glands.

Drugs and medication

Abnormally high prolactin levels can also be caused by some drugs. These include oral contraceptives, hormone replacement therapy, and medications used for the treatment of nausea, depression and psychiatric disorders. Drugs such as cocaine and stimulants can also cause high prolactin levels. It is also common after breast feeding to have a prolonged milky nipple discharge.

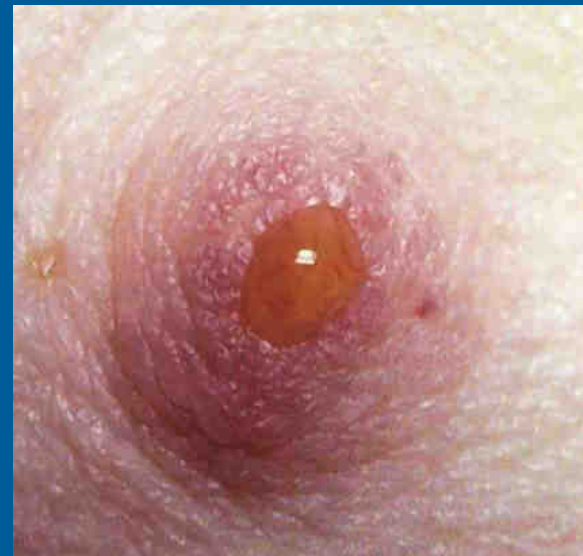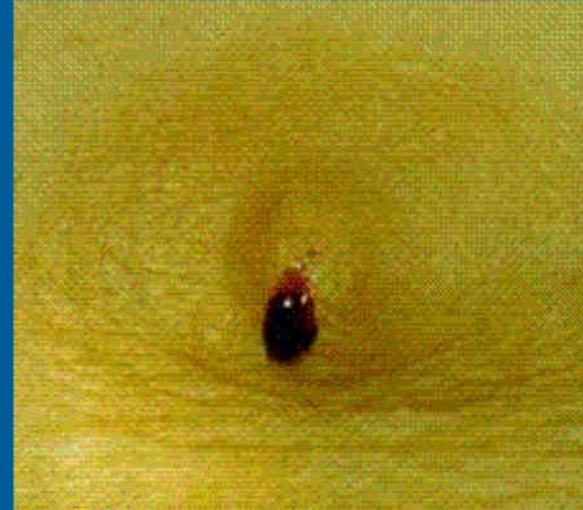


Pathological Nipple Discharge



Epworth

- Nipple discharge that is spontaneous and unrelated to pregnancy or lactation is considered abnormal.
- In the majority of cases it has a benign cause.
- Spontaneous discharge caused by significant pathology is more likely to be unilateral, localised to a single duct, and crystal clear or blood stained in appearance.

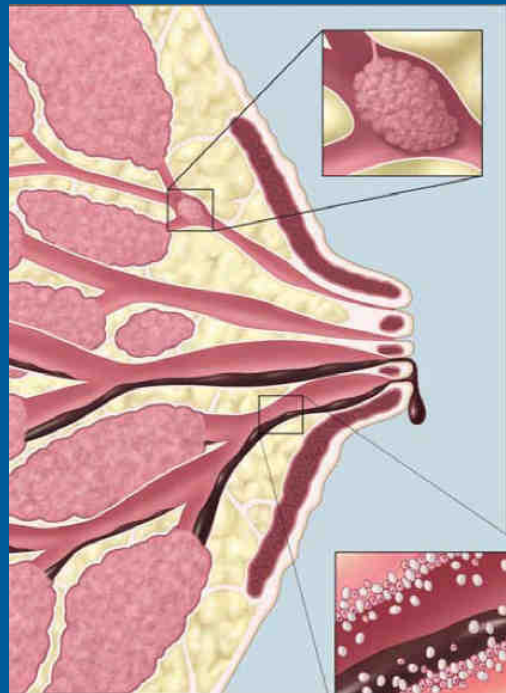


Causes of Pathological Nipple Discharge



Epworth

- **Duct ectasia** - a benign condition with dilatation and inflammation of the ducts under the nipple, usually causes a bilateral yellow, green, or brown discharge from multiple ducts
- **Duct papilloma** - typically causes a clear or bloodstained discharge
Papillomas are usually benign but may rarely be associated with breast cancer and therefore are almost always surgically removed



Intraductal Papilloma

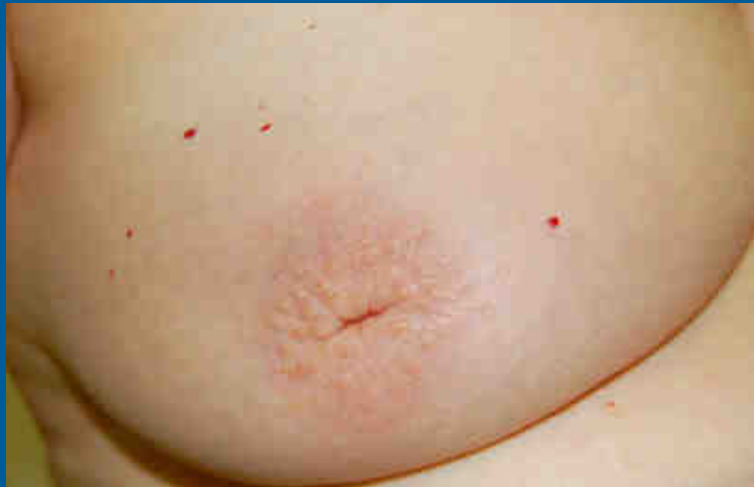

Epworth

- They are most frequently seen in the 30-50yr age group
- A papilloma is a papillary tumor growing from the lining of the breast duct
- The discharge associated with a papilloma can be clear or grossly bloody
- Papillomas can harbor areas of atypia or ductal carcinoma in situ (DCIS)
- The standard recommendation for management of papillomas is that they be excised whenever they are diagnosed by core needle biopsy, although there is some debate in the literature

Duct Ectasia

- Aberration of Normal Development and Involution (ANDI)
- The major subareolar ducts dilate and shorten during ageing or involution
- By the age of 70, 40 % of women have substantial duct dilatation
- Some of these women develop both duct dilatation and duct shortening that manifests as nipple inversion with or without nipple discharge
- The discharge in patients with duct ectasia is usually “cheesy” in consistency
- The nipple inversion is classically slit like.



Causes of Pathological Nipple Discharge



Epworth

- **Nipple eczema** - eczema or dermatitis affecting the skin of the nipple, particularly if infected, can cause a weeping, crusty, nipple discharge (pseudo-discharge)
- **Breast cancer** - breast cancer is an uncommon cause of nipple discharge. Only about 3% of women with breast cancer have nipple discharge, and most of these have other symptoms such as a lump in addition to the discharge.
- **Paget's disease** - a particular clinical presentation of breast cancer causing ulceration and erosion of the nipple
- **Hyperprolactinaemia** - high prolactin levels may cause galactorrhoea
Aetiology includes endocrine causes, eg. Pituitary disease and drug causes, eg. oral contraceptives, hormone therapy, antiemetics, antipsychotics, cocaine, and stimulants



- Malignancy is found in 5 to 15 percent of cases of pathologic nipple discharge
- The most common malignancy associated with nipple discharge in the absence of other findings is DCIS
- Age is predictive of the risk of cancer in women with nipple discharge
- In one series of women with isolated nipple discharge, malignancy was present in:
 - 3 percent of those <40 years of age
 - 10 percent of those 40 to 60 years of age
 - 32 percent of those over 60

Surg Gynecol Obstet. 1970;

The clinical history is most helpful in distinguishing benign from suspicious pathologic nipple discharge

- Is it “spontaneous” (fluid leaks from the breast without any squeezing of the nipple or pressure on the breast) or “on expression” (fluid only comes out of the nipple when the nipple is squeezed or there is pressure on the breast)?
- Is it unilateral or bilateral?
- Is it coming from one duct or more than one?
- What colour is it? (nipple fluid is most often yellow, green or milky. Discharge that is blood-stained or crystal clear can be more significant)



Lactation

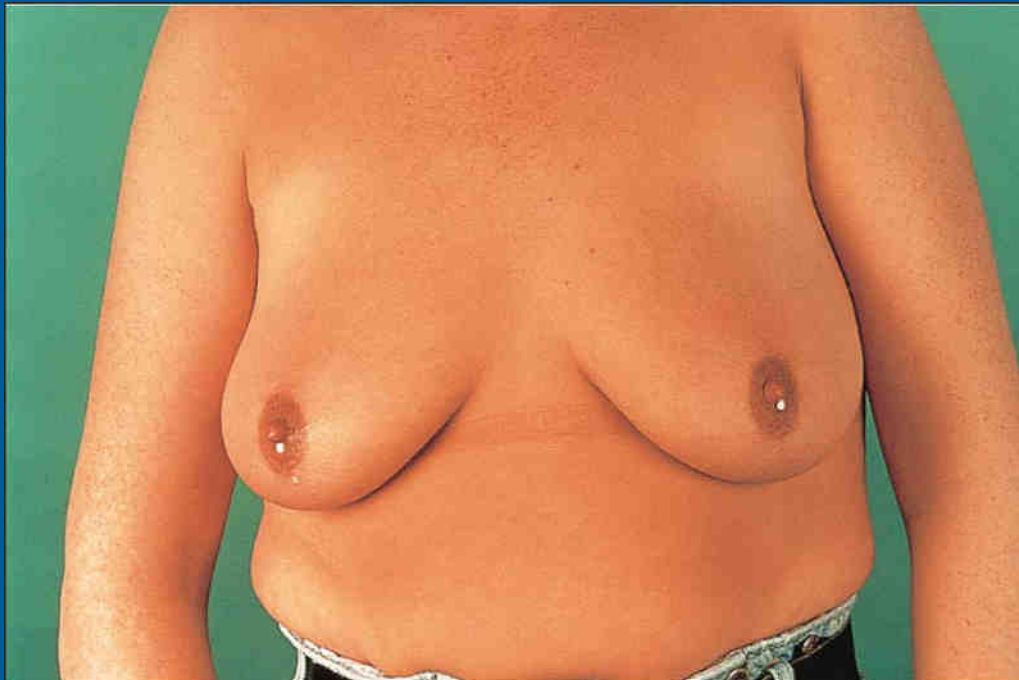

Epworth

- During pregnancy and the postpartum period, the mammary glands develop and produce milk in response to a number of physical and biochemical
- Milky nipple discharge (either spontaneous or on expression) is normal (physiological) during pregnancy and breast feeding.
- Milky nipple discharge may be prolonged following lactation (2 years)
- Bloody nipple discharge can be seen in 20 percent of women during the second or third trimester of pregnancy and lactation, and is usually benign.

Galactorrhea

- Galactorrhea is milky nipple discharge not related to pregnancy or breast feeding
- Galactorrhea is usually manifested as bilateral milky nipple discharge involving multiple ducts
- The nipple discharge, although usually bilateral and white or clear, may also be unilateral and a variety of colors, including yellow (straw-coloured), green, brown, or gray



Galactorrhea

- Galactorrhea is frequently caused by hyperprolactinemia, which may be secondary to medications, endocrine tumors (pituitary adenoma), endocrine abnormalities, or a variety of medical conditions
- Neurogenic stimulation — Neurogenic stimulation represses the secretion of hypothalamic prolactin inhibitory factor, resulting in hyperprolactinemia and galactorrhea. Examples of neurogenic stimulation include chronic breast stimulation from manipulation or clothing (for example, a poorly fitting brassiere)
- Stresses such as trauma, surgical procedures, and anaesthesia may also inhibit dopamine release, thereby causing hyperprolactinemia and inducing galactorrhea



Epworth

Galactorrhea



Epworth

Drugs- commonly oral contraceptives, hormone therapy, antiemetics, antipsychotics, cocaine, and stimulants

- Antidepressants and anxiolytics, including tricyclic antidepressants and selective serotonin-reuptake inhibitors.
- Antihypertensives, including methyldopa (Aldomet®) and atenolol (Tenormin®).
- Antipsychotics
- Histamine H₂-receptor blockers, including cimetidine (Tagamet®) and ranitidine (Zantac®).
- Hormonal medications, including conjugated estrogen plus medroxyprogesterone acetate, medroxyprogesterone acetate contraceptive injection (Depo-Provera) and oral contraceptives.
- Phenothiazines, including chlorpromazine.
- Others, including amphetamines, anaesthetics, cannabis, danazol, isoniazid, metoclopramide, opiates and valproic acid.

History

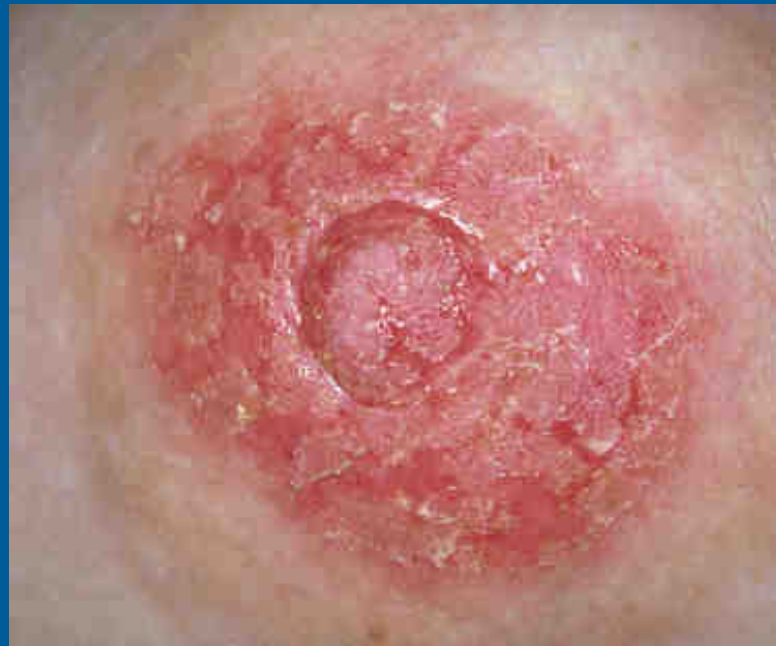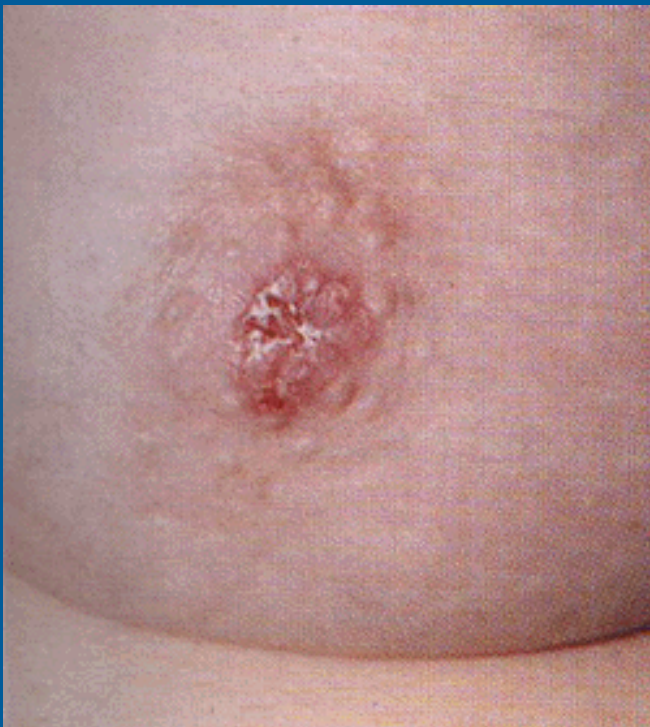- A complete medical history, including medication use, should be obtained
- Nipple discharge that is associated with other symptoms such as a lump in the breast needs prompt investigation, even if it is not spontaneous or blood-stained.
- Specific areas to address are the appearance of the discharge, whether the discharge is spontaneous or provoked by manipulation of the breast and whether it is unilateral or bilateral
- Cancers generally present with spontaneous unilateral, discharge, although bilateral synchronous cancers can occur
- Bilateral nipple discharge is usually due to an endocrinologic or physiologic process
- A history of recent trauma should also be elicited
- Trauma can include mammographic imaging with compression as well as vigorous manipulation of the nipple by the patient or her partner
- Recent onset of amenorrhea or other symptoms of hypogonadism should prompt consideration of hyperprolactinemia.



Epworth

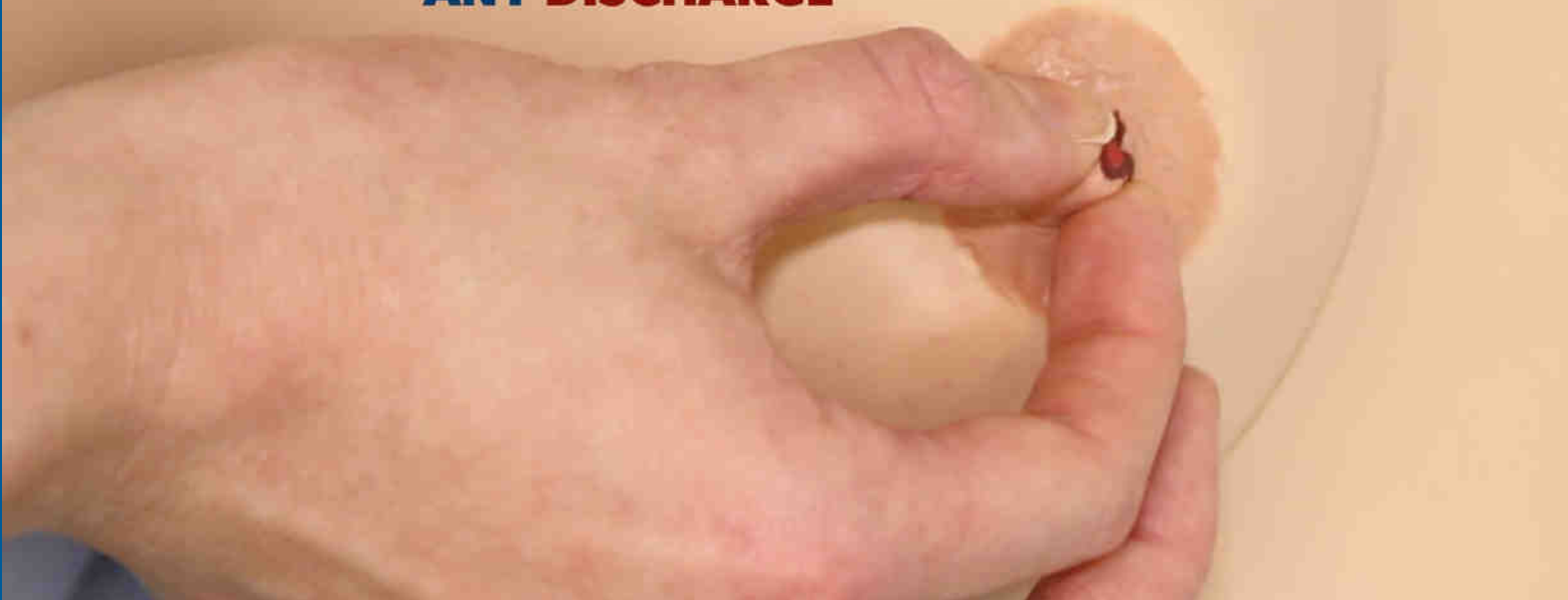Examination

- The skin covering the breast and nipple/areolar complex should be examined for lesions that may be staining the woman's clothes and mimicking nipple discharge eg Paget's disease, eczema



Epworth

**ASK THE PATIENT
TO PALPATE THE
NIPPLE TO CHECK FOR
ANY DISCHARGE**

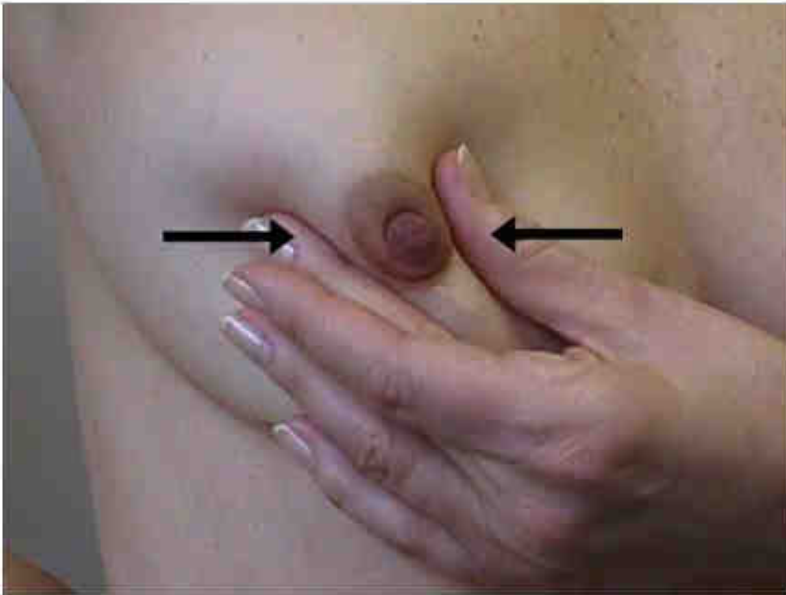


- Often the patient is able to produce the discharge herself, which may be less uncomfortable than attempted expression by the examining doctor
- It is important to observe whether the discharge comes from one or more ducts on the nipple

27 Jun 20



Epworth

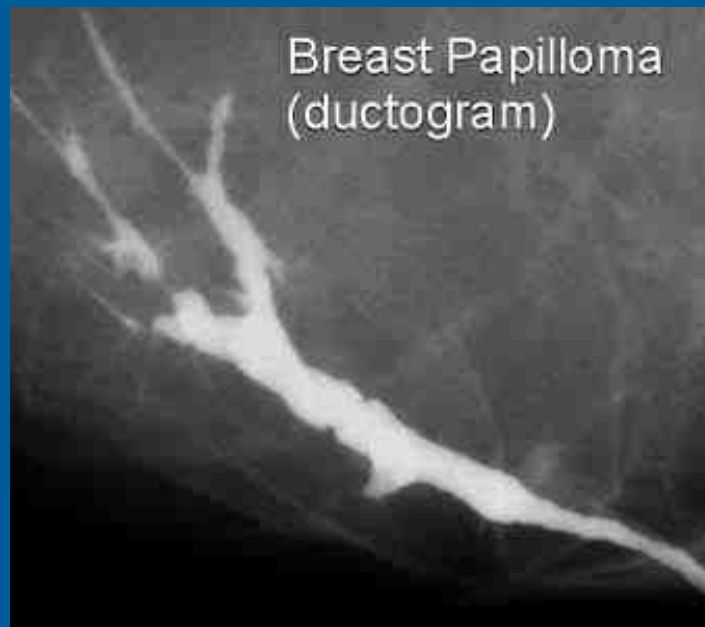

- Strip the ducts towards the nipple.
- Normally, one or two drops of clear, milky or green-tinged secretions.
- Should not be bloody or in large quantity, squirting out or staining the inside of a bra.

- A woman may report finding a stain or spot of blood on her bra or night clothing
- If the skin is intact and no discharge can be elicited and the rest of the physical examination and radiologic evaluation is negative, short-term clinical follow-up in 2-3 months is appropriate
- Ask patient to document episodes of discharge in a diary
- Advise patient to avoid squeezing prior to clinical review

Imaging

- Imaging studies do not reliably identify cancer or high-risk lesions in patients with nipple discharge
- Standard breast imaging as per patient age
- Ductography - NO




Investigations



Epworth

? Bloodstained -standard urinalysis sticks

- 75% ca presenting with single duct nipple discharge non bloody
- Papilloma most common diagnosis in bloody single duct nipple discharge
Surgery, 2004

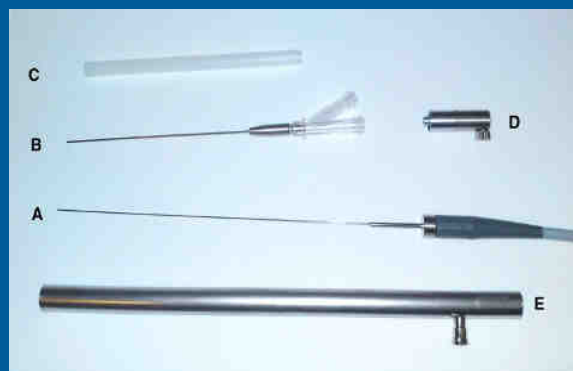

? Nipple Discharge Cytology- limited accuracy

- Consider in spontaneous, single duct discharge only
- Among patients with biopsy proven carcinoma, 29 % of cytology specimens of the discharge have been reported to show no evidence of carcinoma or atypia

Diagn Cytopathol. 2001

• ? Ductoscopy-NO





Management of Pathological Nipple Discharge

- The difficulty in managing pathological spontaneous, single duct nipple discharge is that the risk of carcinoma, despite being low, cannot be eliminated without surgical duct excision and histologic confirmation.
- Thus, duct excision in all patients with pathologic single duct nipple discharge is widely recommended

Predicting occult malignancy in nipple discharge

Chris Alcock* and Graham T. Layer*†

*Department of Breast Surgery, The Royal Surrey County Hospital, Guildford, GU2 7XX, UK
†Postgraduate Medical School, University of Surrey, UK

Key words

major duct excision, malignancy, nipple discharge, papilloma, retrospective analysis

Abbreviations

BI-RADS, Breast Imaging Reporting and Data System; DCIS, ductal carcinoma *in situ*; LCIS, lobular carcinoma *in situ*.

Correspondence

Dr Chris Alcock, 32/161 Main Street, Kangaroo Point, QLD 4168, Australia. Email: chrisalcock@doctors.org.uk

C. Alcock MBBS, MRCS; G. T. Layer DM FRCS

No benefits have been received or will be received from a commercial party related directly or indirectly to the subject of this article.

Accepted for publication 18 December 2008.

doi: 10.1111/j.1445-2107.2010.05270.x

Abstract

Background: This study was a retrospective analysis of patients who underwent minor or major duct surgery for pathological nipple discharge. The results of clinical examination, mammography, ultrasonography and cytodiagnosis of the nipple discharge were studied in order to predict those patients at risk of underlying or occult malignancy.

Methods: Between January 2004 and December 2006, 55 female patients aged between 24 and 82 years old underwent major or minor duct excision, 49 of which were for pathological nipple discharge. Results of several preoperative investigations were compared with the surgical pathology to determine how their sensitivity and specificity fared in predicting malignant ductal pathology.

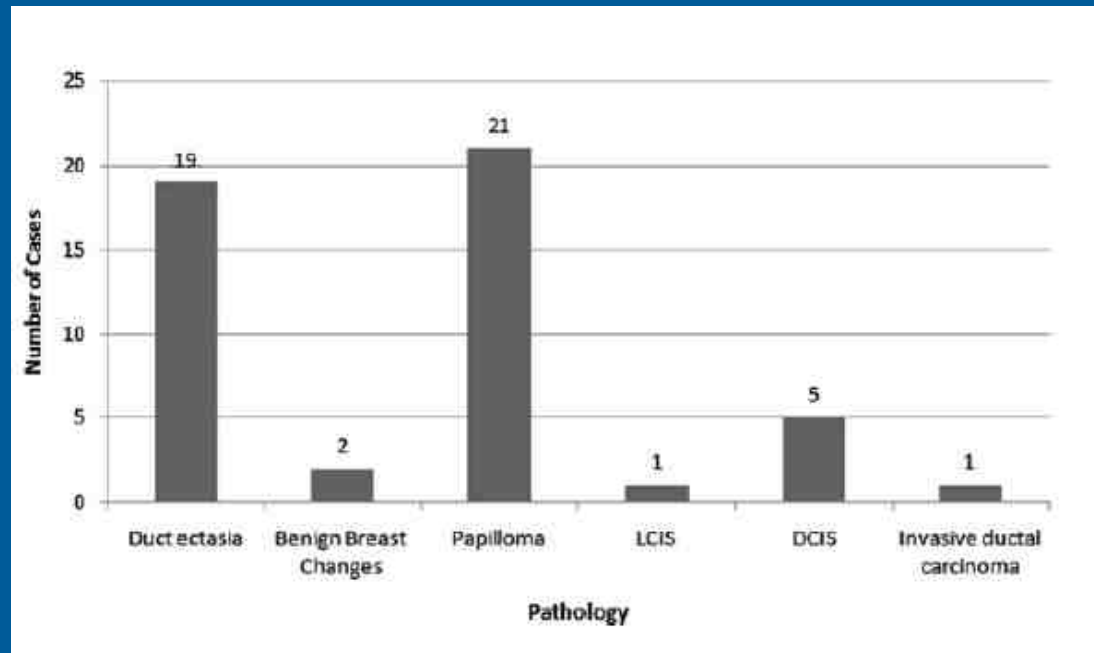
Results: Of the 49 patients undergoing surgery for nipple discharge, 21 were diagnosed with intraductal papilloma, 19 with duct ectasia, 6 with carcinoma, 2 with benign breast disease and 1 with lobular carcinoma *in situ*. In all of the patients determined to have malignancy, none demonstrated malignant changes on mammography or ultrasonography. Only 2 of the 6 patients with malignancy were found to have atypical cells on cytological analysis. The sensitivity of blood detected in nipple discharge at predicting malignancy was 0.83, specificity of 0.53, positive predictive value of 0.20 and negative predictive value 0.96.

Conclusions: Despite the various tests used in the assessment of pathological nipple discharge, this study highlights their limited help at predicting the cause. This, together with several other studies, demonstrates that ductal surgery remains the only reliable way of providing a diagnosis, in addition to being the major therapeutic measure.

ANZ Journal of Surgery, 2010

Conclusions: Despite the various tests used in the assessment of pathological nipple discharge, this study highlights their limited help at predicting the cause. This, together with several other studies, demonstrates that ductal surgery remains the only reliable way of providing a diagnosis, in addition to being the major therapeutic measure.

End histological diagnosis in patients presenting with pathological nipple discharge.



Epworth

Of the 49 patients undergoing surgery for nipple discharge:

- 21 intraductal papilloma
- 19 duct ectasia
- 6 carcinoma (12%) - 5 DCIS/1 invasive ca
- 2 benign breast disease
- 1 lobular carcinoma in situ (LCIS)

Patients with pathological nipple discharge in whom occult malignancy was discovered after histological analysis of surgical specimens



Epworth

Age	Examination	Mammogram	Ultrasound	Cytology	Histology
36	Normal	M1	U2	C2	DCIS
41	Normal	M2	U2	C1/C2	DCIS
49	Normal	M1	U1	C2	DCIS
47	Normal	M1	Not performed	C2	DCIS
61	Normal	M2	U2	C3	DCIS
61	Normal	M1	U2	C3	Invasive ductal carcinoma

M1/U1, normal; M2/U2, benign; C1, inadequate; C2, benign; C3, suspicious, probably benign/atypical; DCIS, ductal carcinoma *in situ*.

In the patients determined to have malignancy:

- None demonstrated malignant changes on mammography or ultrasonography
- Only 2 of the 6 patients with malignancy were found to have atypical cells on cytological analysis.

Clinical Science

Lessons learned from 416 cases of nipple discharge of the breast

Mary Morrogh, M.D.^a, Anna Park, B.S.^a, Elena B. Elkin, Ph.D.^b, Tari A. King, M.D.^{a,*}

^aBreast Service, Department of Surgery, Memorial Sloan-Kettering Cancer Center, 1275 York Avenue, New York, NY 10065, USA; ^bDepartment of Epidemiology, Biostatistics, Memorial Sloan-Kettering Cancer Center, New York, NY, USA

KEYWORDS:

Nipple discharge;
Clinical evaluation;
Breast imaging;
Breast cancer;
Duct excision

Abstract

BACKGROUND: For patients with nipple discharge (ND), surgical duct excision is often required to exclude underlying malignancy. Our objective was to define clinical predictors of malignancy and examine the utility of common preoperative studies.

STUDY DESIGN: We retrospectively identified 475 patients presenting with a chief complaint of ND from 1995 to 2005; 416 (88%) were eligible for review.

RESULTS: Following standard evaluation (clinical breast examination/mammogram/ultrasound), 129 of 416 (31%) were considered to have physiological ND and were managed expectantly, whereas 287 of 416 (69%) underwent further evaluation (cytology/ductography/magnetic resonance imaging) followed by biopsy ± surgery. Clinical features associated with pathological ND included bloody ND (adjusted odds ratio 3.7) and spontaneous ND (adjusted OR 3.2). Biopsy/surgery identified a causative lesion in 259 of 287 (90%), of which 37% were either malignant (n = 65) or high-risk (n = 30) lesions. The sole clinical predictor of malignant/high-risk lesion was a palpable mass (adjusted odds ratio 4.3). Preoperative evaluation identified 76 of 95 (80%) malignant/high-risk lesions, whereas 19 of 95 (20%) were identified by duct excision alone.

CONCLUSIONS: Although clinical stratification alone reliably identified patients with pathological ND, neither the clinical characteristics nor preoperative studies can reliably distinguish between benign and malignant pathology. Surgical duct excision remains the gold standard to exclude underlying malignancy.

© 2010 Elsevier Inc. All rights reserved.

The American Journal of Surgery ,2010

33% of patients considered to have pathological nipple discharge were found to have an underlying malignant or high risk lesion (LCIS or ADH), of whom almost half had a negative CBE and/or Mgm.

CONCLUSIONS: Although clinical stratification alone reliably identified patients with pathological ND, neither the clinical characteristics nor preoperative studies can reliably distinguish between benign and malignant pathology. Surgical duct excision remains the gold standard to exclude underlying malignancy.



Epworth

Treatment

Non significant Nipple Discharge

- Advise not to squeeze the nipple
- If persists and is nuisance ? therapeutic total duct excision (the purpose is to stop the discharge with the operation instead of doing it for diagnostic assessment alone)

Pathological Nipple Discharge

Surgical evaluation of pathologic nipple discharge with duct excision is required for diagnosis and treatment even if the imaging results are negative

Diagnostic Surgery

- Microdochectomy
- Total Duct Excision (TDE or Hadfield's Procedure)
 - Total excision of the major breast ducts,
 - S/E: nipple sensation, nipple necrosis,



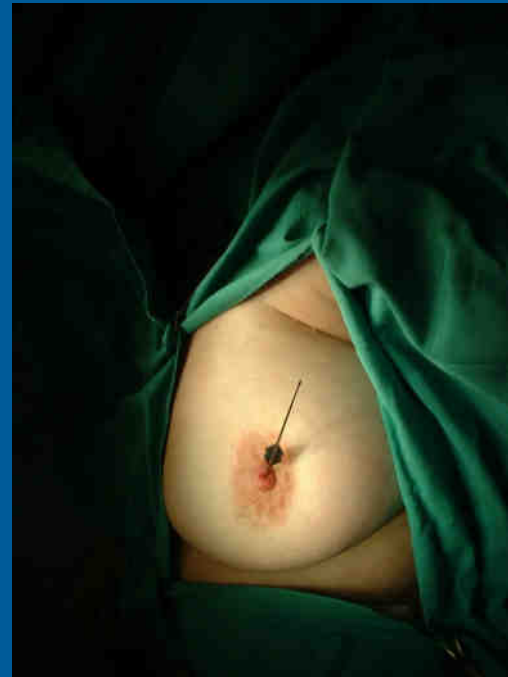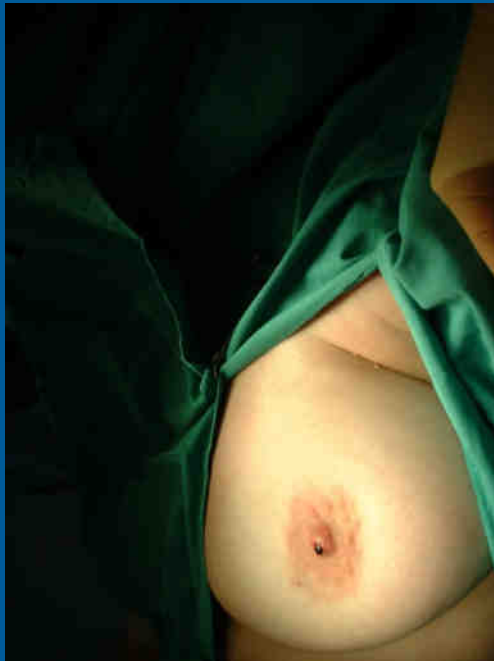Epworth



- When a single duct can be implicated, the surgeon should direct the resection to the site of concern, performing microdochectomy, attempting to preserve the non-affected ducts in young patients where the option of breastfeeding must be preserved
- In older patients, irrespective of whether the discharge is localized to one or multiple ducts, major duct excision may be preferred in order to avoid further discharge from another duct

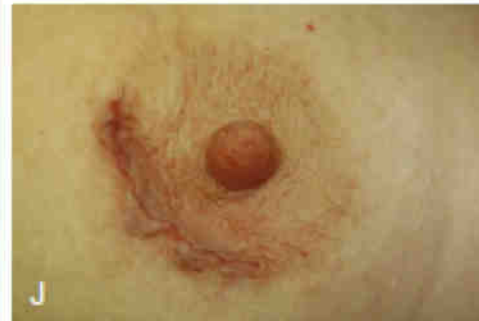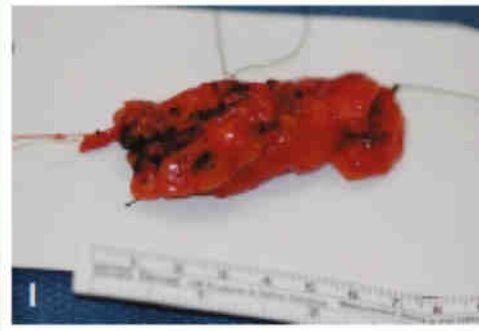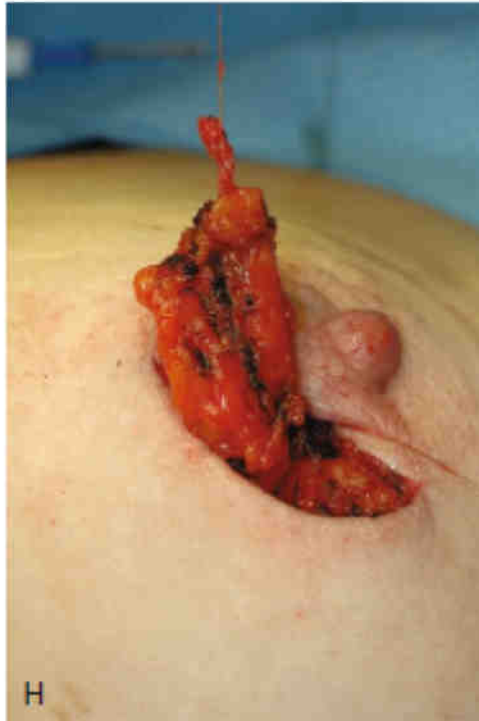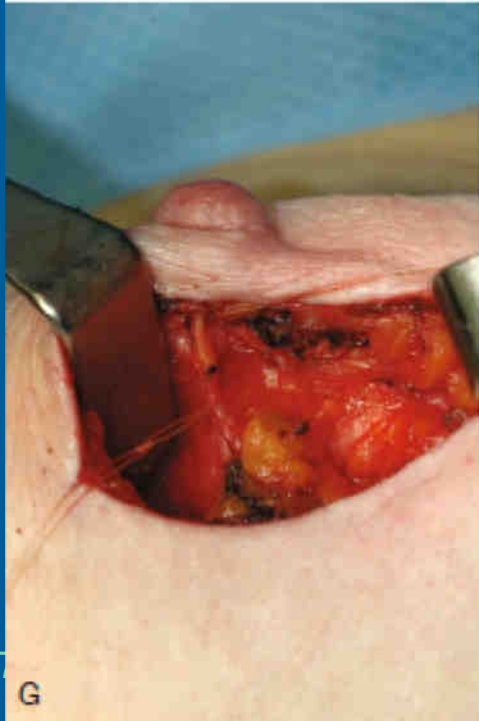
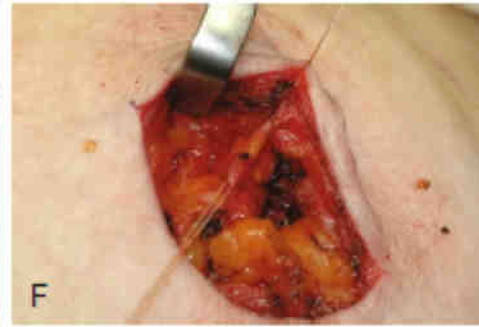
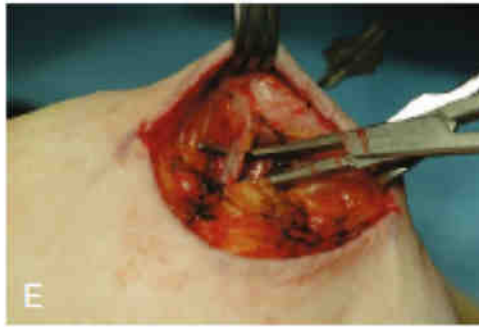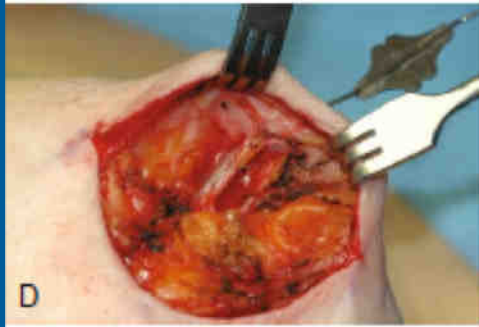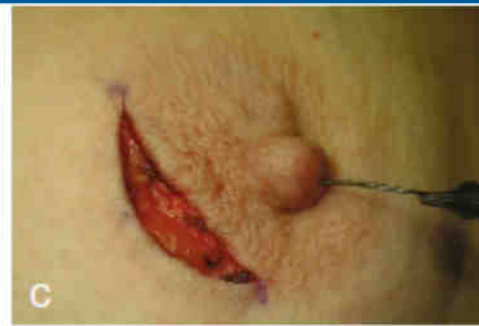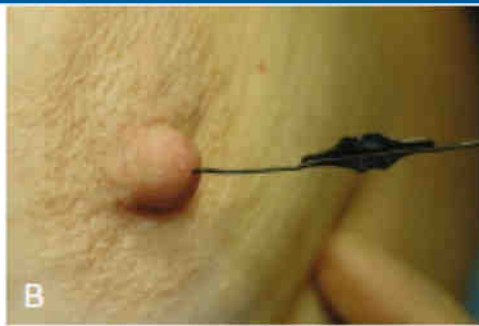
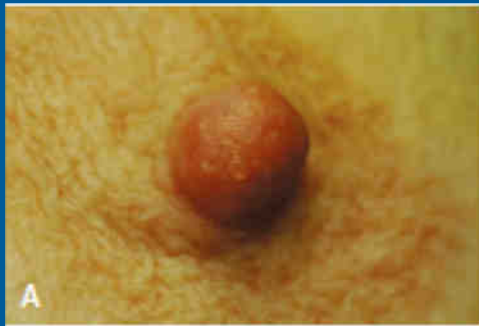Microdochectomy.

- After identifying the orifice of the discharging duct by gentle pressure on the nipple, the duct is probed with a fine lacrimal probe that is passed gently peripherally as far as possible without disrupting the duct.
- A limited circumareolar incision is made to raise the areolar skin flap.





- A limited circumareolar incision is made to raise the areolar skin flap.
- The probed duct is then identified close to its attachment on the underside of the nipple and carefully dissected free of the surrounding tissues and the unaffected ducts over a length of 5-6 cm towards its proximal end.
- The discharging duct, once it has been identified, is dissected distally into the breast over a distance of about 5 cm
- Almost all significant disease that causes nipple discharge involves the proximal 5 cm
- Following excision of the involved duct, the remaining distal duct in the breast should be inspected, and if there is a visible dilated duct passing into the breast, then further tissue can be excised, or the duct opened and any visible lesion in the duct removed
- This is because some DCIS lesions develop at some distance from the nipple, and these produce nipple discharge, but can be missed on microdochectomy.
- They are diagnosed only if the distal ducts are inspected and excised if abnormal
- Finally, the duct is removed by transaction and is marked with a single suture to orientate the specimen



Total duct excision

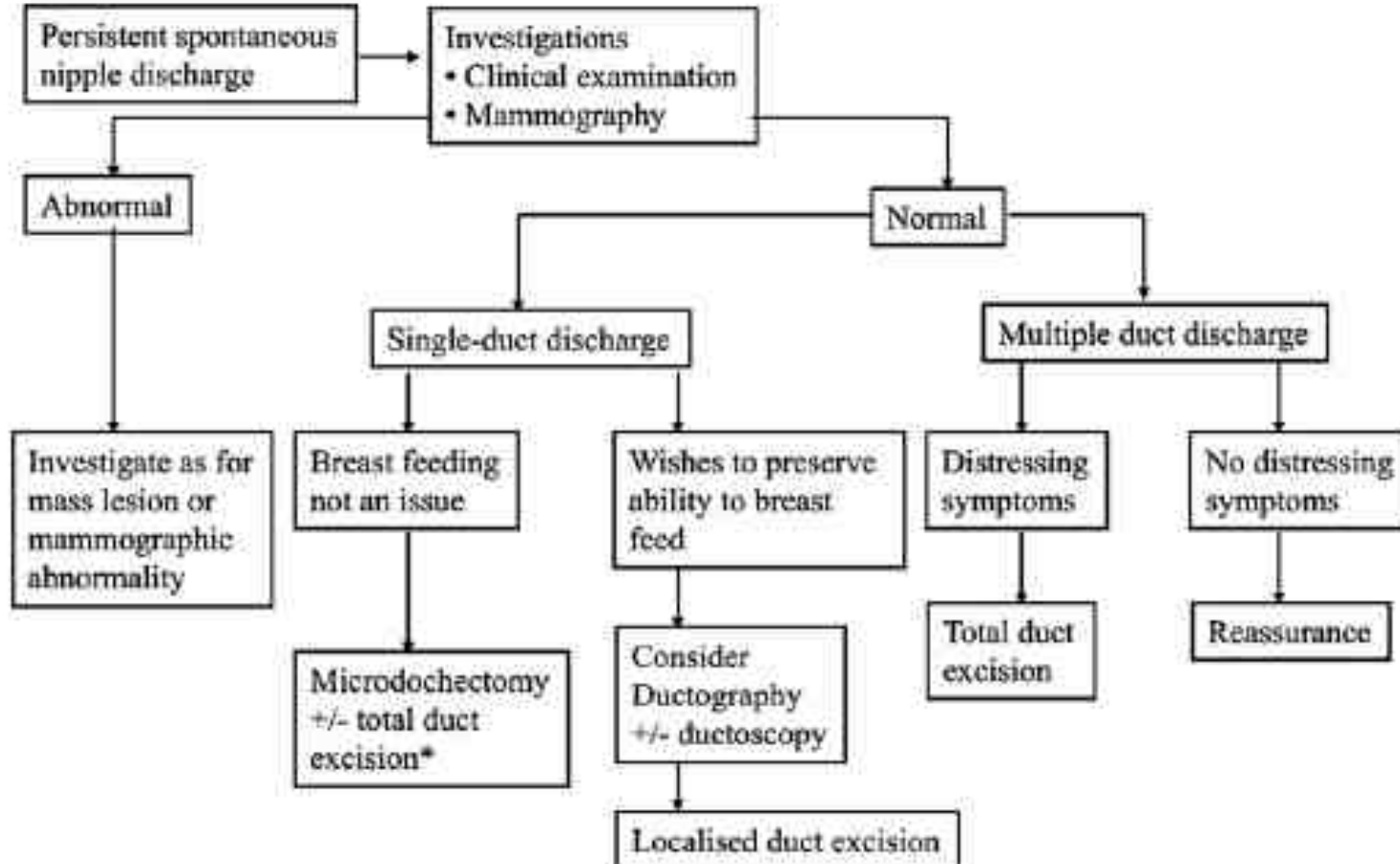
- Best performed through circumareolar incision based at 6 o'clock
- Having deepened the incision, dissection continues towards the nipple.
- It is usually better to use scissors or a knife near the nipple rather than cautery.
- Dissection with Metzenbaum scissors is continued under the areola down either side of the major ducts
- Curved tissue forceps are then passed around the ducts, and all the ducts that have been encircled are delivered into the wound
- Having secured the distal ducts with tissue forceps, they are then divided from the underside of the nipple.
- Approximately 5 cm of ducts are excised

Total duct excision



Epworth

- It is often useful to close any defect in the breast with absorbable sutures
- If the nipple was inverted prior to surgery, then it is important to evert the nipple before wound closure, and this may involve dividing any scar tissue that is distorting the nipple
- The nipple may need to be squeezed between the thumb and index finger to break down any adhesions to maintain eversion
- Sutures are rarely if ever required to maintain eversion because if the nipple does not remain everted without sutures, then it will invert even if sutures are placed
- Small risk of nipple tip necrosis (<1%)
- Patients should be warned before surgery that this operation will reduce nipple sensitivity in up to 40 % of women

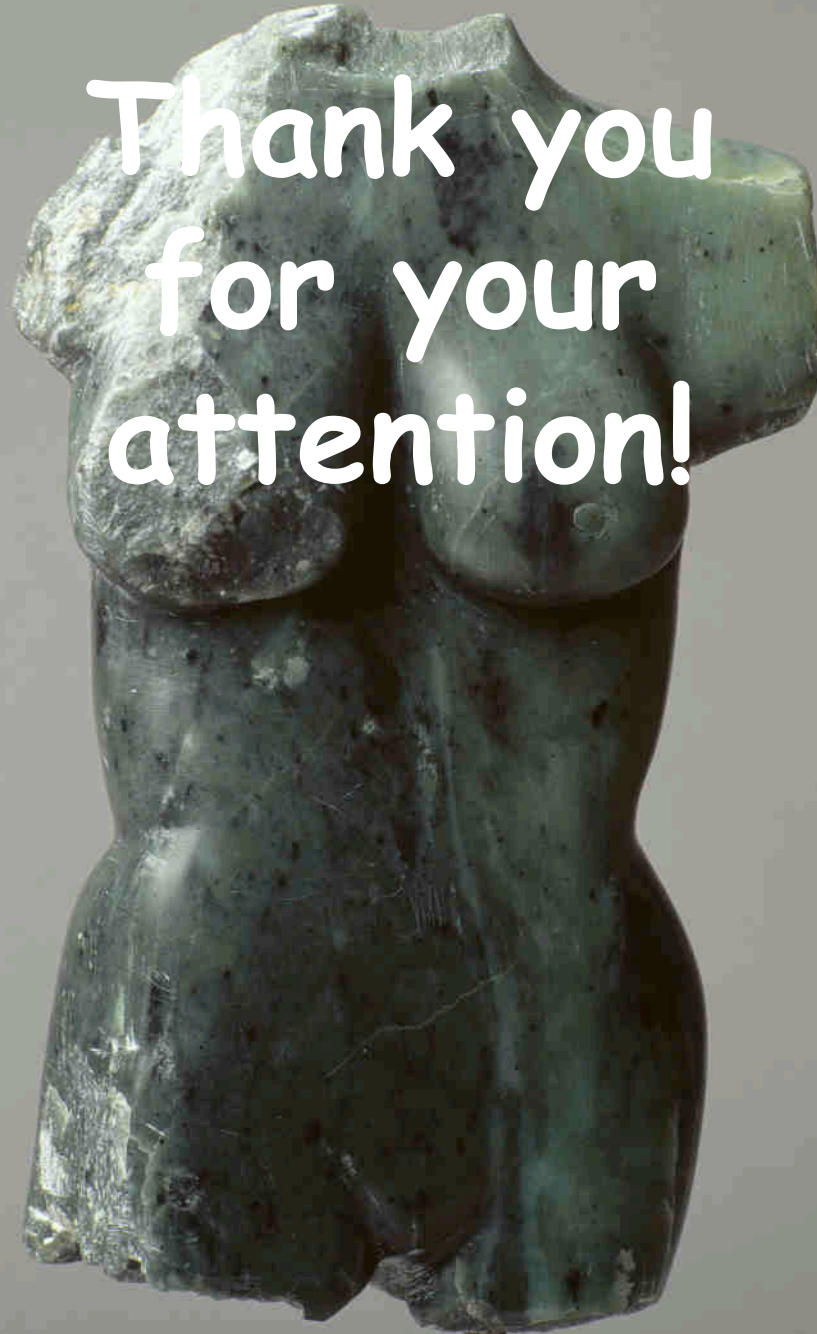


*Some surgeons prefer total duct excision in women >45 to reduce incidence of discharge from other ducts

Summary

- Nipple discharge is common, and in most cases benign.
- Discharge on expression is benign and physiological and requires no intervention
- Spontaneous, single duct nipple discharge is pathological, and diagnostic surgery will usually be recommended in order to exclude malignancy
- The difficulty in managing pathological spontaneous, single duct nipple discharge is that the risk of carcinoma, despite being low, cannot be eliminated without surgical duct excision and histologic confirmation.
- Duct excision in all patients with pathologic single duct nipple discharge is widely recommended.

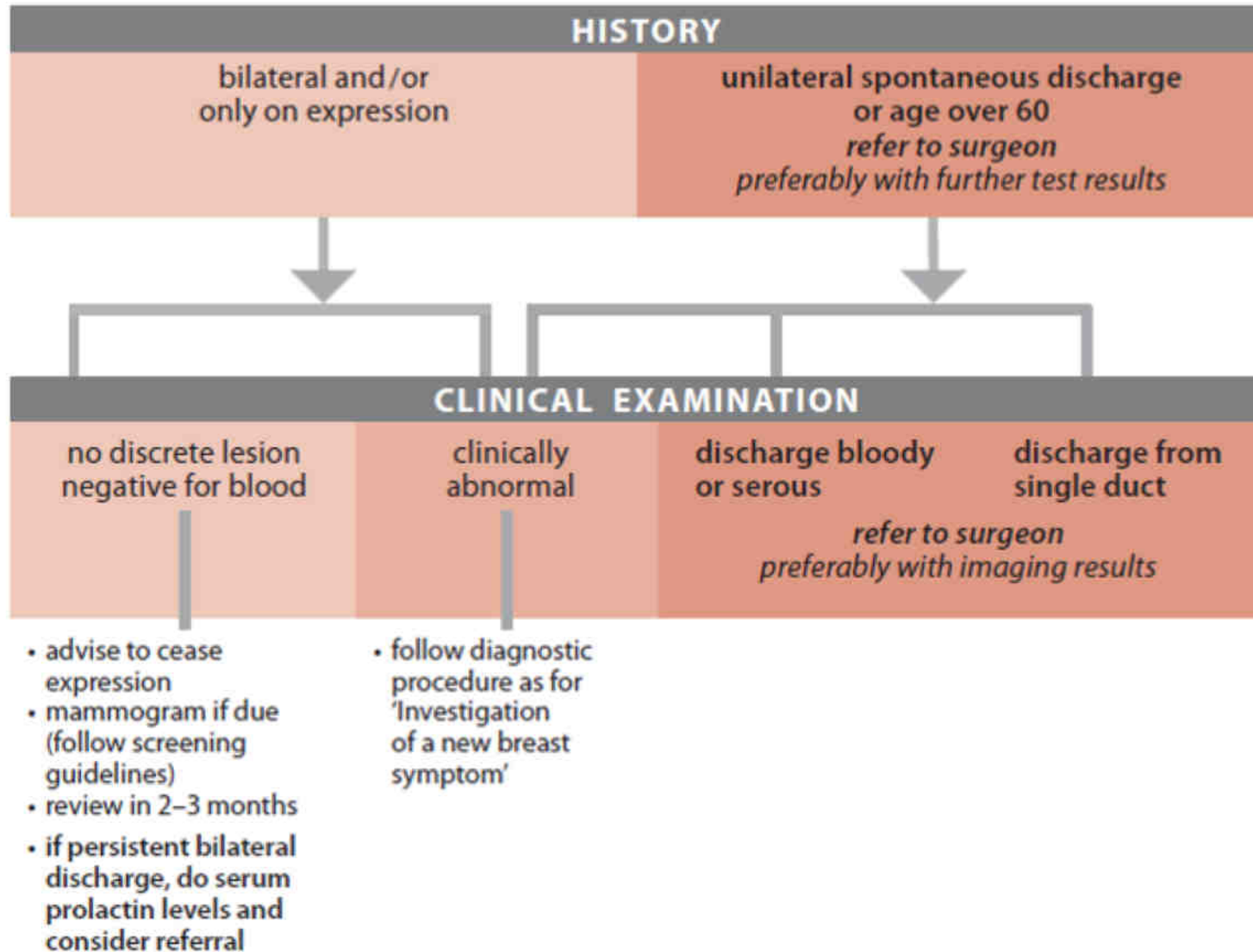
Thank you
for your
attention!



Epworth



The investigation of a new nipple discharge





NIPPLE DISCHARGE

Probability (%) of cancer by age and nature of discharge

	Age <60	Age >60
Serous	<1	3
Bloody	3	9

In women with nipple discharge, most cancers occur in women who have a bloody or serous discharge or are 60 years or older, necessitating further investigation. Discharge cytology has low sensitivity (45%) but is highly specific for cancer.

Implications for practice

- Spontaneous, unilateral, bloody or serous discharge from a single duct raises the possibility of cancer, especially if it occurs in older women.
- Positive discharge cytology result is indicative of cancer, but a negative result cannot be used to rule out the disease.
- The use of galactography should be based on the availability of expertise, preferably after consultation with a surgeon.