

Ching-Wei D. Tzeng, J. Harrison Howard, and Kirby I. Bland

## Key Concepts

- › Indications for mastectomy rather than breast conserving therapy (lumpectomy and radiation)
  - Patient preference
  - Increased risk (e.g., BRCA positive)
  - Multicentric disease
  - Large tumor to breast size ratio
  - Patient unable to tolerate radiation therapy
- › Sentinel node biopsy is performed at the time of mastectomy for clinically node-negative women
  - Mastectomy precludes subsequent periareolar or peritumoral injection and may obliterate lymphatics
  - SLNB may require a second, small, axillary incision
- › Skin-sparing mastectomy (SSM) facilitates reconstruction
- › Timing of SLNB is controversial in the setting of neoadjuvant chemotherapy

## Background

When possible, most women choose breast conservation therapy (lumpectomy with radiation therapy) over mastectomy. Under some circumstances, mastectomy is a better option. The technique of mastectomy has evolved since the original classical radical mastectomy. The recent trend is toward greater use of skin-sparing mastectomy (SSM) with immediate reconstruction.

---

K.I. Bland (✉)

Fay Fletcher Kerner Professor and Chairman, Department of Surgery, University of Alabama School of Medicine, Birmingham, AL, USA  
e-mail: kirby.bland@ccc.uab.edu

---

## Indications for Mastectomy

Mastectomy is often chosen based upon preference. Although studies have not shown any difference in overall survival with breast conserving therapy (BCT, i.e., breast conserving surgery + breast radiotherapy) compared with mastectomy, some women are not comfortable with the risk of local recurrence or the need for radiation therapy. Women with risk factors such as contralateral breast cancer, strong family history, or mutation in the BRCA-1 or BRCA-2 genes may be better served by mastectomy. Surgical indications for mastectomy include all contraindications to BCT. Multicentric disease or a large component of associated DCIS may preclude BCT. When the tumor is large compared to the breast, insufficient breast tissue may remain after lumpectomy, yielding a poor cosmetic result. Although resectable T2 (2–5 cm) cancers do not have a greater risk of local recurrence than similarly treated T1 (<2 cm) lesions, it may be more difficult to perform an adequate excision with negative margins, especially if the breast is small. Some of these patients may be candidates for neoadjuvant chemotherapy to shrink the tumor and allow BCT. Finally, patients who are unable to tolerate radiation therapy due to collagen vascular disease or previous radiation require mastectomy.

---

## Major Technical Considerations in Planning Mastectomy

Total glandular mastectomy includes the index tumor, the nipple-areolar complex, and the previous biopsy cavity en bloc, along with varying degrees of skin excision depending on whether total mastectomy (TM) or skin-sparing mastectomy (SSM) is intended. Access to the axilla may be through the mastectomy incision or through a separate incision in the axilla.

Local recurrence is more dependent upon tumor biology and stage than upon radical skin excision, assuming all other factors are equal. Thus, SSM with immediate reconstruction has become the preferred choice of many patients and their surgeons.

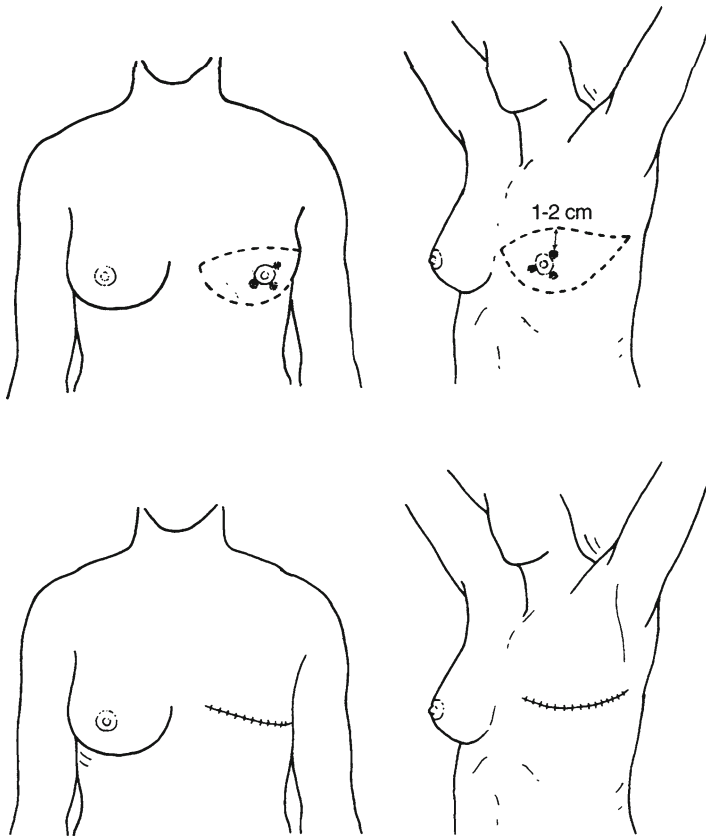
In clinically node-negative patients who have not already undergone nodal evaluation, one must perform axillary node staging by sentinel node biopsy (SLNB) prior to or at the time of mastectomy, because removal of the breast precludes peritumoral and periareolar injections for SLNB in the future. If the SLN is positive on frozen section or touch prep, completion axillary node dissection (AND) is required at the same setting. A separate axillary incision may be made if needed.

SSM removes all breast tissue and the nipple-areola complex, preserving the entire skin envelope except for a 1 cm margin around excised scars from previous biopsies. Generally, only 5–10% of the skin overlying the breast is removed in SSM, compared to up to 50% for TM. SSM is paired with immediate reconstruction. It is cosmetically preferred over TM with reconstruction because it helps improve the shape of the reconstructed breast, and the normal skin color and texture is preserved (as opposed to skin imported with a flap). The contraindications to this procedure are described later in this chapter.

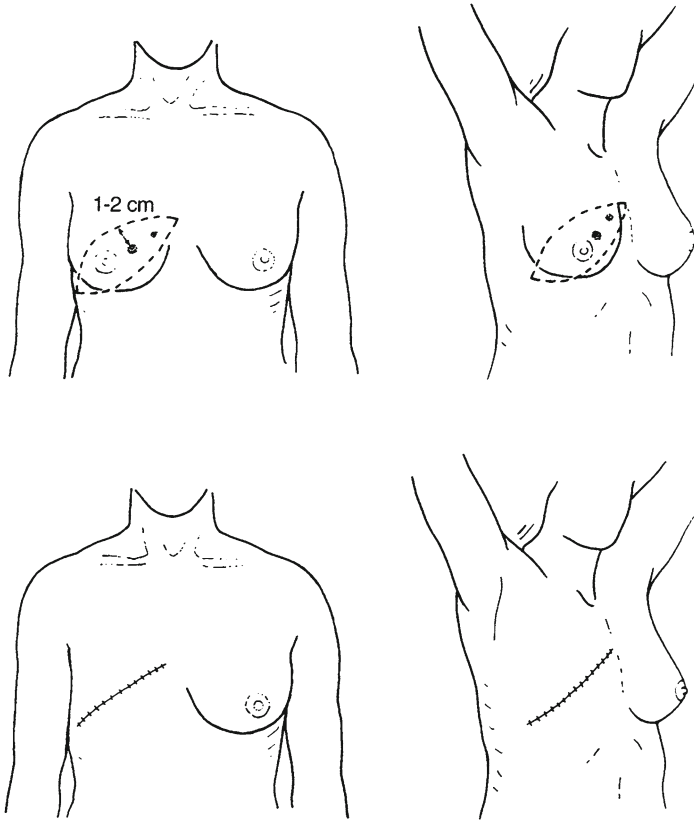
### Steps in Total Mastectomy: Choice of Skin Incision

A curvilinear incision is made along Langer's lines. Incision orientation and choice of flaps depend upon the location of the primary tumor. *Central (subareolar) tumors and those at 3 o'clock and 9 o'clock* can be excised with the classic Stewart transversely oriented elliptical incision (Fig. 35.1). The medial border of the incision is the margin of the sternum, while the lateral border should overlie the anterior edge of the latissimus. The Stewart incision is often preferred by plastic surgeons planning delayed reconstruction with myocutaneous flaps, especially in conjunction with contralateral TM for high-risk disease or prophylaxis.

*Upper inner quadrant tumors* require an oblique incision with the medial/cephalad extent toward the sternal notch. The medial extent may include sternal skin beyond the midline if the tumor is very medial. The caudal end should extend far enough to offer axillary access (Fig. 35.2). Sometimes an obliquely oriented "lazy S" incision can be used to



**Fig. 35.1** Classic Stewart incision for central and subareolar lesions



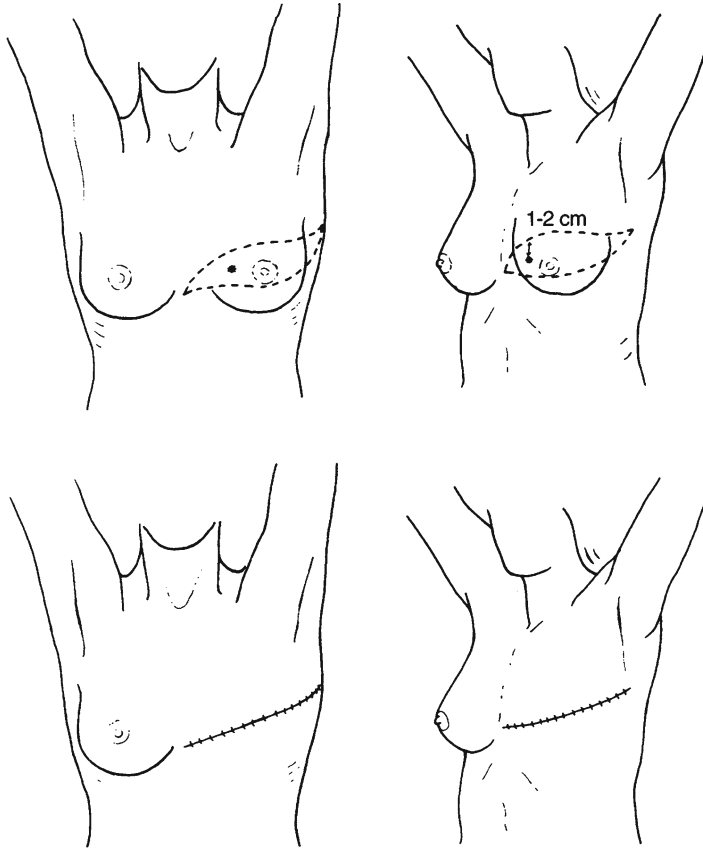
**Fig. 35.2** Oblique incision for upper inner quadrant tumors. The medial extent may cross the sternal border

allow excision of the skin over a medial tumor while minimizing the visible scar high in the midline.

*Lower inner quadrant tumors* can be excised through an oblique (modified) Stewart incision. As with upper inner quadrant tumors, the medial extent may include sternal skin. The lateral edge again overlies the anterior margin of the latissimus, offering axillary access (Fig. 35.3). These tumors can also be excised with an oblique (Orr) incision, as described below.

*Upper outer quadrant* and central tumors can be excised with the classic Orr (oblique) incision. The Orr incision is a slightly oblique from transverse incision that is low medially and extends high at the lateral aspect, offering access to axillary nodes without an additional incision (Fig. 35.4).

*Lower outer quadrant tumors* can be excised through an oblique incision extending similar in direction to what is used for upper inner quadrant tumors. The difference is that, for lower outer quadrant lesions, the medial extent does not cross the sternal border. Inferolaterally, the margin must offer axillary access (Fig. 35.5).



**Fig. 35.3** Oblique (modified) Stewart incision for lower inner quadrant cancers

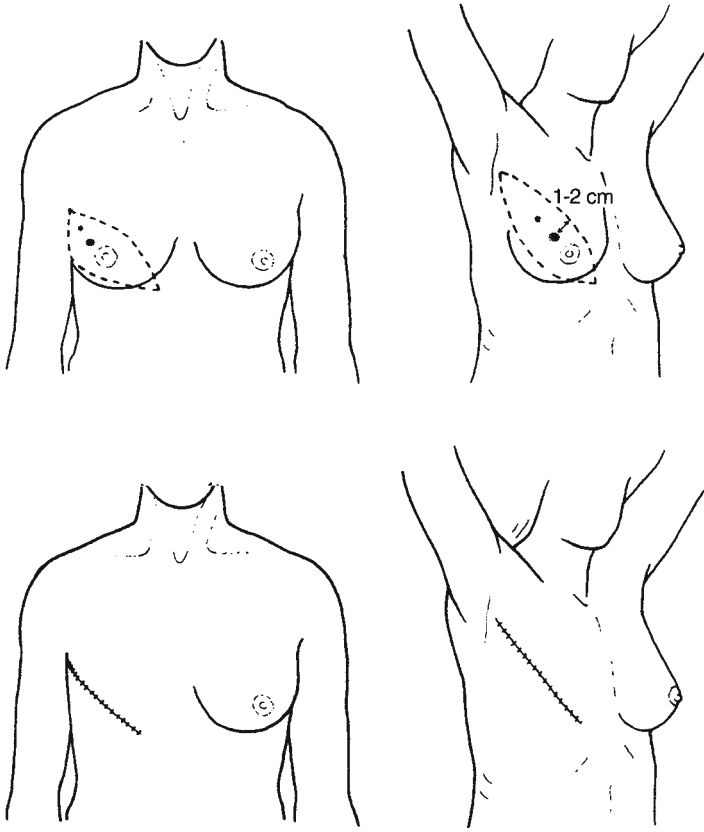
*Upper midline (near 12 o'clock)* lesions require near-vertical incisions that extend toward the clavicle. The high vertical placement may warrant a separate axillary incision for nodal sampling. Closure is difficult and not ideal cosmetically because the incisions are perpendicular to Langer's lines. Large skin defects may require split thickness skin grafts or myocutaneous flap coverage (Fig. 35.6).

*Lower midline (close to 6 o'clock)* and lower inner quadrant lesions can be excised with a more vertically placed (modified) Orr incision, with the cephalad extent still extending toward the ipsilateral axilla for nodal access (Fig. 35.7).

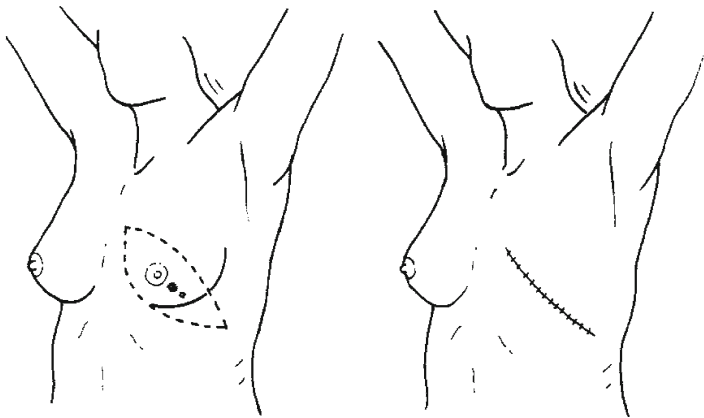
---

### Creating the Flaps

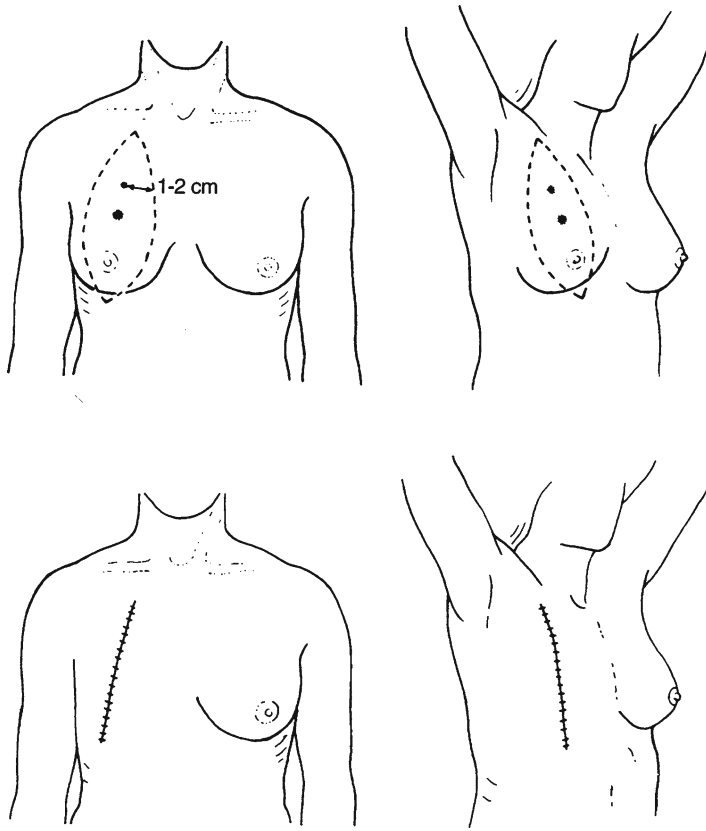
Cut through the dermis with a scalpel and elevate the skin edges with skin hooks. Using electrocautery, develop a dissection plane at the deep layer of the superficial investing fascia between breast tissue and subcutaneous fat, leaving a 6- to 8-mm flap. Ideally, there



**Fig. 35.4** Classic Orr incision for upper outer quadrant lesions



**Fig. 35.5** Oblique incision for lower outer quadrant tumors. The medial extent will not cross the sternal border

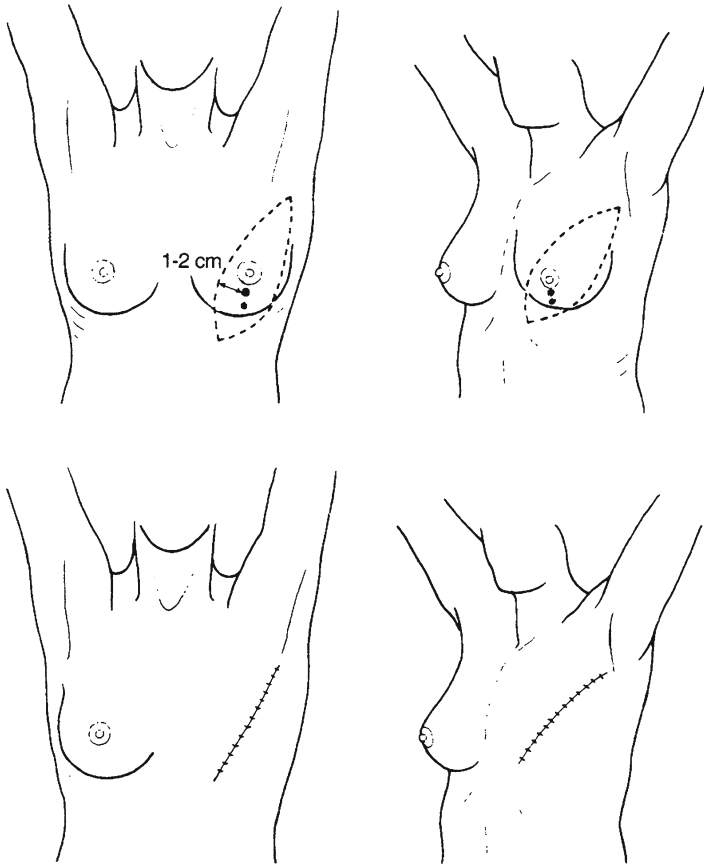


**Fig. 35.6** Difficult upper midline cancers require a less-than-ideal near-vertical incision across Langer's lines. These can be difficult to close primarily

is as little breast tissue left under the skin as possible, without making the skin flap so thin that its blood supply is threatened. There is frequently an avascular fusion plane at the proper depth which, if followed, achieves these dual objectives. Firm traction is a critical part of identifying the correct plane intermittent palpation of flap thickness during the procedure ensures the dissection is proceeding in the proper plane.

The thickness of subcutaneous tissue left behind is influenced by the patient's body habitus and lean body mass. If immediate reconstruction is not planned, excess skin must be included in the elliptical skin incision, so that there is a balance between lack of excess skin and minimal tension upon closure.

The skin excision should include the previous biopsy site/scar as well as the nipple-areola complex as previously noted. If the tumor is superficial enough that it is within 1 cm of the skin surface, the overlying skin should be removed. If the index tumor is close to the boundaries of the planned excision, frozen sections can be used to confirm negative margins of at least 1 cm in all three dimensions.



**Fig. 35.7** A more vertical (modified) Orr incision allows access to lower midline tumors while preserving excellent axillary access

The anatomic margins of glandular mastectomy include the second rib superiorly, the sternum medially, the latissimus laterally, and the inframammary crease inferiorly.

### Dissection from the Pectoral Muscles

After the flaps are completed, the breast tissue is dissected off the pectoralis major with electrocautery. The investing fascia and some underlying pectoralis muscle itself may need to be excised if the surgeon feels that the tumor is deep and abuts the posterior margin. Frozen sections can help in this situation.

Retract the breast tissue en bloc as it is dissected off the chest wall, helping with exposure as the mastectomy progresses. Dissect the axillary tail of Spence to the lateral border



of the pectoralis major. As a final step of breast tissue resection, the junction between the axillary contents and the breast tissue (containing lateral branches of the medial pectoral vessels) is divided with clamps and ligated. If modified radical mastectomy is to be performed (that is, TM with AND), many surgeons will leave the breast attached to the axilla and remove the entire specimen in continuity.

#### How I do it

For total mastectomy (TM), use a generally oblique incision (high laterally, lower medially, if feasible), excising nipple-areolar complex and skin over tumor and biopsy incision

For SSM, perform a circumareolar “keyhole” incision with excision of scar

Raise flaps in natural cleavage plan (6–8-mm thick)

Preserve perforators (internal thoracic vessels), if possible, to enhance flap viability

Glandular mastectomy boundaries

Second rib superiorly

Anterior border of latissimus dorsi muscle laterally

Inframammary crease inferiorly

Sternum medially

Remove breast from pectoralis major muscle, excising fascia and even muscle if necessary to attain margin on tumor

Terminate dissection at the lateral border of the pectoralis major muscle

Two closed suction drains

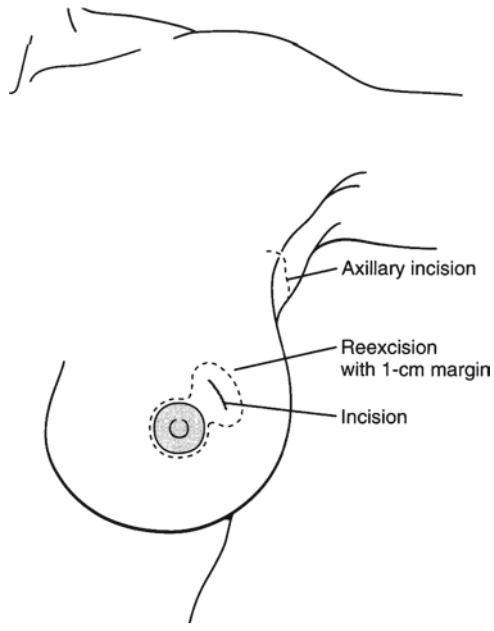
Correct dog ears if necessary

### Major Differences Between the Initial Steps of TM and SSM

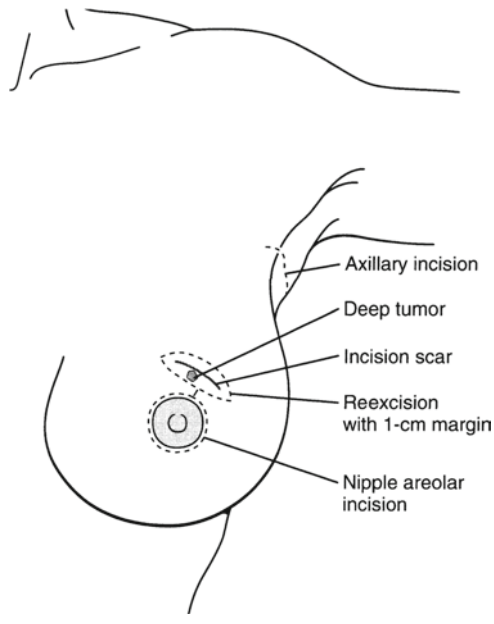
Ideally, the entire SSM should be performed through a “keyhole” which includes the entire nipple-areola complex (Fig. 35.8). The nipple-areola complex remains en bloc with the excised breast parenchyma. The previous biopsy site/scar (from open or needle biopsy) should be excised with 1-cm margins. Whether the primary tumor biopsy site skin margin is included depends on its distance from the nipple-areola complex. If it is within a few cm, a single incision should include both to avoid a short skin bridge, with its risk of devascularization. If it is more than 4 cm away, two separate incisions can be made (Fig. 35.9).

A separate (second or third total) incision in the axilla may also be necessary for the SLN (Fig. 35.10). If a lateral extension of the keyhole has to be made for better mastectomy exposure, this can be extended into the axilla for access.

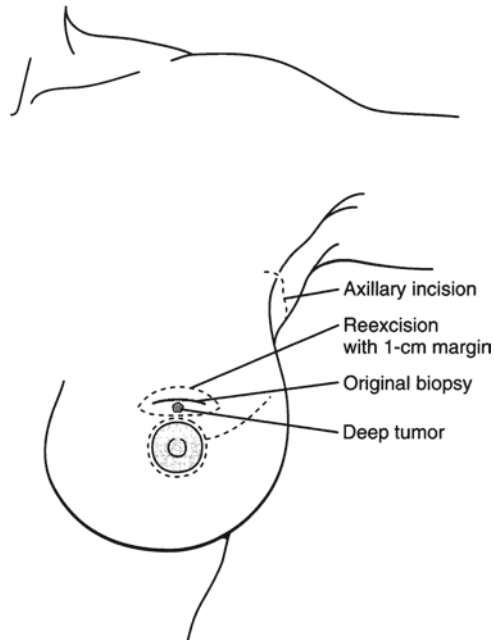
The nipple-areola complex is sometimes preserved if the tumor is sufficiently away from the nipple-areola complex to guarantee adequate margins. If this is the case, a separate (frozen, then permanent) margin should be included to ensure that leaving behind the nipple-areola complex preserves negative margins (see Chap. 36).



**Fig. 35.8** Skin-sparing mastectomy keyhole incision including the previous biopsy site. A separate axillary incision is required



**Fig. 35.9** SSM keyhole with skin bridge because the previous biopsy site is >4 cm away. A separate axillary incision is required



**Fig. 35.10** Sometimes the SSM keyhole requires a lateral extension for further exposure. This can be continued toward the axilla for nodal access, so that a separate axillary incision is not required

### Contraindications to SSM (Hence Indications for TM)

When SSM is contraindicated or not desired, TM is performed. Absolute contraindications to SSM include previously irradiated skin, locally advanced tumors with skin involvement (e.g., large tumors <1 cm from inner surface of skin flap, peau d'orange, or ulceration), and inflammatory breast cancer. The main relative contraindication is a preoperative plan not to reconstruct the breast at the time of mastectomy. If there is no immediate plan to reconstruct the breast, more skin tissue should be excised so that the postmastectomy chest wall wound will be flat and void of free space susceptible to seromas and hematomas, which can lead to subsequent infections. This will also create a flat surface that the patient will find easier to keep clean and to fit with a prosthesis.

### Complications of Mastectomy

*Seromas* from breast tissue dissection and (less commonly) hematomas can form in the immediate postoperative period. To minimize this problem, up to two closed suction drains are placed along the pectoralis major fascia to drain serosanguinous fluid postoperatively. These drains are left until total output is down to a minimal amount (often after the patient is already discharged from the hospital), such as 30 cc/day. With standard drain care

instruction while in the hospital, the vast majority of patients can take care of their drains at home without any need for home health nursing.

*Flap necrosis* is more common when thinner flaps are created. The typical skin flap will be 6- to 8-mm (or a single lobule of fat) thick, depending on a patient's body type and degree of obesity. Thinner flaps, with disruption of the subcutaneous microvascular plexus, are at greater risk for necrosis, especially at the distal margins of the skin flap where the incision is closed. Frequent checks of the skin flap thickness with palpation while cauterizing prevents a dissection plane that is too thin and accidental perforation of the skin flap. Preservation of the parasternal and infraclavicular perforators (which come through the pectoralis major when dissecting the breast tissue off the posterior margin) also improves blood supply to the flaps, lessening necrosis risk. Smoking cessation is highly encouraged to preserve microvascular flow. Nicotine patches are not advised during this period. This is especially important with myocutaneous flap reconstruction.

*Dog ears* (excess skin at the corners of wide skin excisions) can be minimized by using elliptical incisions in TM. If they persist at the end of the case, they can be excised in the standard fashion by extending the incision at an angle, folding over the dog ear, and excising the excess skin. Dog ears are not a problem with the limited skin excision of SSM and the use of immediate reconstruction.

---

## Special Considerations

*Locally advanced disease* may require excision beyond typical skin margins. If preoperative staging shows that enough skin will be excised that a skin graft will be needed or that there is tumor invading to or into the chest wall, then this patient is a candidate for preoperative neoadjuvant chemotherapy (CTX) in an attempt to shrink the tumor preoperatively. Even after neoadjuvant CTX, the patient may still need a skin graft if skin invasion exists beyond the typical borders of a TM. One precaution is to use frozen section assessment of skin margins before placement of the skin graft.

Pectoralis muscles may need to be excised down to the chest wall with locally advanced disease. Preoperative radiographic assessment and intraoperative frozen sections will define the depth of invasion and whether the bony chest wall is involved. Chest wall resection is discussed briefly below.

*After neoadjuvant chemotherapy*, the primary questions relate to the use of SLNB. Because of the theoretical concern for destruction of the lymphatic channels from the CTX, some have argued for pre-CTX SLNB. But this subjects patients to completion AND before CTX, when the SLN could have been the only positive node and the CTX could have treated any axillary metastases. Several studies have shown an acceptably high success rate in doing SLNB after CTX, because, even after CTX, the SLN is often the site of isolated axillary metastasis. The decision depends on the surgeon's comfort level and experience in doing SLNB in post-CTX patients. Finally, neoadjuvant CTX requires reassessment of a patient's operative and reconstruction options. If a large tumor shrinks appropriately, the patient may instead receive BCT rather than mastectomy.

*Timing of reconstruction and choice of technique* may influence how the mastectomy is performed, as previously noted. Most patients will elect to undergo immediate reconstruction,

whether SSM or TM is chosen. With TM, often a tissue expander will be placed at the time of mastectomy as the first step. Implants and tissue expanders are placed deep to the pectoralis major muscle, and preservation of the pectoral fascia (if oncologically feasible) helps keep the material deep to the muscle. Similarly, preservation of the inframammary fold and midline septum between the two breasts helps the ultimate reconstructive cosmetic result. Preoperative planning involves both the surgical oncologist and plastic surgeon. This reinforces the multispecialty nature of breast surgery.

*Prophylactic contralateral mastectomy* is performed in patients at high risk for bilateral disease, including those with strong family history and BRCA gene mutations. Even in this population, the decision is up to the patient. Although it reduces risk of contralateral breast cancer by up to 97%, still only 50% of U.S. women with BRCA mutations choose prophylactic contralateral mastectomy. Factors associated with choosing prophylactic contralateral mastectomy include younger age at cancer diagnosis, mastectomy on the index (other) side rather than BCT, and prophylactic bilateral oophorectomy.

SLNB is not required in all prophylactic mastectomies, because of the low rate of invasive ductal cancer (as low as 2%). However, in selective high-risk populations (e.g., older patients, invasive lobular cancer, and lobular carcinoma in situ), surgeons should consider SLNB at the time of mastectomy. Preoperatively, planning should include genetic counseling in those with strong family histories as well as surgical planning with a reconstructive plastic surgeon.

In *synchronous bilateral breast cancer*, the skin flaps in bilateral mastectomy depend on the location of the primary tumors as well as the plastic surgeon's choice of myocutaneous flap and its blood supply. As with unilateral mastectomy, bilateral SSM with reconstruction is preferred if possible. Bilateral axillary sampling is required.

#### Pitfalls and Complications

- Flap necrosis – more common in smokers
- Seroma/hematoma formation
- Failure to attain clean margins
  - Consider frozen section in locally advanced lesions
  - Split thickness skin graft or flap closure may be required

While *chest wall resection* is beyond the scope of the chapter, there are times when it is necessary to resect components of the chest wall, including the pectoralis and ribs. This often occurs in the setting of local recurrence. Chest wall resection is usually reserved for locally advanced disease only. The main exception would be for palliation for a painfully advanced lesion with systemic disease. In operations for curative intent, systemic disease must be ruled out with appropriate CT, MRI, and/or PET scans. Preoperative planning entails consultation with a plastic surgeon for breast reconstruction and a thoracic surgeon if a partial lung resection is anticipated.

The resection includes one intercostal space above and below the index tumor site and requires chest wall reconstruction of flail segments greater than four rib spaces. Margins are preoperatively drawn for 2 cm beyond the index area, and circumferential preincision skin biopsies are taken to delineate tumor-free flap margins. Frozen sections of deep margins are confirmed negative before reconstruction begins.

## Suggested Reading

- Bland KI, McCraw JB, Copeland EM, Vasconez LO. Chapter 39: General principles of mastectomy: evaluation and therapeutic options. In: Bland KI, Copeland EM, editors. *The breast: comprehensive management of benign and malignant disorders*, vol 1. 3rd ed. St. Louis: Elsevier; 2004. p. 803–42.
- Boughey JC, Khakpour N, Meric-Bernstam F, et al. Selective use of sentinel lymph node surgery during prophylactic mastectomy. *Cancer*. 2006;107(7):1440–7.
- Faneyte IF, Rutgers EJ, Zoetmulder FA. Chest wall resection in the treatment of locally recurrent breast carcinoma: indications and outcome for 44 patients. *Cancer*. 1997;80(5):886–91.
- Hatmaker AR, Meszoely IM, Kelley MC. Surgical management of carcinoma in situ and proliferative lesions of the breast. In: Fischer JE, Bland KI, editors. *Mastery of surgery*, vol. 1. Philadelphia: Lippincott Williams & Wilkins; 2007. p. 521–9.
- Medina-Franco H, Vasconez LO, Fix RJ, et al. Factors associated with local recurrence after skin-sparing mastectomy and immediate breast reconstruction for invasive breast cancer. *Ann Surg*. 2002;235(6):814–9.
- Metcalfe KA, Lubinski J, Ghadirian P, et al. Predictors of contralateral prophylactic mastectomy in women with a BRCA1 or BRCA2 mutation: the Hereditary Breast Cancer Clinical Study Group. *J Clin Oncol*. 2008;26(7):1093–7.
- National Comprehensive Cancer Network Guidelines in oncology: breast cancer. <http://www.nccn.org>. Accessed April 2008.
- Silverstein MJ. The University of Southern California/Van Nuys prognostic index for ductal carcinoma in situ of the breast. *Am J Surg*. 2003;186(4):337–43.
- Urist MM. Breast cancer: surgical therapy. In: Cameron JL, editor. *Current surgical therapy*. 9th ed. Philadelphia: Mosby; 2008. p. 653–5.