



## Breast Imaging

## Unilateral axillary Adenopathy in the setting of COVID-19 vaccine

Nishi Mehta<sup>\*</sup>, Rachel Marcus Sales, Kemi Babagbemi, Allison D. Levy, Anika L. McGrath, Michele Drotman, Katerina Dodelzon

Weill Cornell at NewYork-Presbyterian, Department of Radiology, New York, NY, USA

## ARTICLE INFO

**Keywords:**  
 COVID-19  
 Vaccine  
 Unilateral axillary adenopathy  
 Breast imaging  
 Screening

## ABSTRACT

With the recent U.S. Food and Drug Administration (FDA)-approval and rollout of the Pfizer-BioNTech and Moderna COVID-19 vaccines, it is important for radiologists to consider recent COVID-19 vaccination history as a possible differential diagnosis for patients with unilateral axillary adenopathy. Hyperplastic axillary nodes can be seen on sonography after any vaccination but are more common after a vaccine that evokes a strong immune response, such as the COVID-19 vaccine. As the differential of unilateral axillary adenopathy includes breast malignancy, it is crucial to both thoroughly evaluate the breast for primary malignancy and to elicit history of recent vaccination. As COVID-19 vaccines will soon be available to a larger patient population, radiologists should be familiar with the imaging features of COVID-19 vaccine induced hyperplastic adenopathy and its inclusion in a differential for unilateral axillary adenopathy. Short-term follow-up for unilateral axillary adenopathy in the setting of recent COVID-19 vaccination is an appropriate recommendation, in lieu of immediately performing potentially unnecessary and costly axillary lymph node biopsies.

## 1. Introduction

With widespread rollout of the COVID-19 vaccine, it is prudent for radiologists to consider vaccine induced hyperplastic adenopathy as an etiology of unilateral axillary adenopathy seen on breast imaging. The recognition, description, and detection of new COVID-19 vaccination induced unilateral axillary adenopathy on breast imaging is presented in this case series. The differential diagnosis for unilateral axillary adenopathy is broad.<sup>1–3</sup> While it is imperative to exclude malignancy by thoroughly examining the ipsilateral breast, it is also important to consider various benign etiologies. One such benign differential diagnosis is recent vaccination history in the ipsilateral upper extremity, which has been documented in the literature as occurring shortly after receiving the smallpox, Bacille Calmette-Guerin (BCG), human papillomavirus (HPV), and H1N1 influenza A virus vaccines.<sup>3–6</sup> In this case series, we present four patients who either presented with palpable unilateral adenopathy or were found to incidentally have unilateral axillary adenopathy during routine breast imaging. The four patients all had history of recent ipsilateral upper extremity vaccination with either the Pfizer-BioNTech or Moderna COVID-19 vaccine. All patients were in group 1a due to front line status and had no predisposing conditions.<sup>7</sup> Radiologists should consider recent COVID-19 vaccination as a possible etiology, in particular given that the finding of unilateral axillary

adenopathy is likely to become more prevalent with the rollout of the COVID-19 vaccines to the general population. The imaging presentation of COVID-19 induced hyperplastic unilateral axillary adenopathy is presented to familiarize radiologists with the imaging features and to raise consideration of this novel diagnosis. Recommendation of short-term follow-up for unilateral axillary adenopathy in the setting of recent COVID-19 vaccination should be considered, in lieu of immediately performing potentially unnecessary and costly axillary lymph node biopsies.

## 2. Case descriptions

## 2.1. Case 1

59-year-old female, with no history of breast cancer, presented for evaluation of a palpable lump in her left axilla. Her family history is notable for a sister with breast cancer diagnosed at age 53.

Diagnostic left breast mammogram was unremarkable. Targeted sonography demonstrated a left axillary lymph node measuring  $2.6 \times 1.5 \times 1.6$  cm with uniform cortical thickening of 0.7 cm corresponding to the patient's palpable area of concern (Fig. 1a,b). The remainder of the left breast was unremarkable. A non-enlarged, normal lymph node was present in the right axilla (Fig. 1c).

<sup>\*</sup> Corresponding author at: Weill Cornell at NewYork-Presbyterian, Department of Radiology, 525 East 68th Street, New York, NY 10065, USA.  
[@NishiMehtaMD](https://twitter.com/NishiMehtaMD), [@RachelMSales43](https://twitter.com/RachelMSales43), [@KemiMDRad](https://twitter.com/KemiMDRad), [@adlevy31](https://twitter.com/adlevy31), [@mcgrath\\_md](https://twitter.com/mcgrath_md), [@KatiaDodelzon](https://twitter.com/KatiaDodelzon)

Further history revealed that the patient first noticed the left axillary lump approximately 9 days after receiving the first dose of the Pfizer-BioNTech COVID-19 vaccine in her left upper extremity. The patient was advised to return for short-term follow-up targeted ultrasound of the left axilla to ensure resolution.

## 2.2. Case 2

42-year-old female, with no history of breast cancer, presented for routine screening mammography and screening breast ultrasound. Her family history is notable for a paternal grandmother diagnosed with breast cancer at age 80. Per electronic medical record, patient received the second dose of the Pfizer-BioNTech COVID-19 vaccine in her left upper extremity 5 days prior.

Bilateral screening mammogram was unremarkable. On screening ultrasound, multiple left axillary lymph nodes with uniformly thickened cortices were noted, with the largest measuring  $2.7 \times 1.2 \times 1.0$  cm (Fig. 2a–c). The remainder of the left breast was unremarkable. No abnormal lymph nodes were present in the right axilla (Fig. 2d). The patient was advised to return for short-term follow-up targeted ultrasound of the left axilla to ensure resolution.

## 2.3. Case 3

42-year-old female, with no personal or family history of breast cancer, presented for sonographic follow-up of probably benign bilateral breast masses. In addition to stable oval well circumscribed parallel hypoechoic bilateral breast masses, the patient was noted to have diffuse cortical thickening of a left axillary lymph node (Fig. 3a, b). The remainder of the left breast was unremarkable. No abnormal lymph nodes were present in the right axilla (Fig. 3c). Upon further questioning, the patient reported receiving the first dose of the Moderna COVID-19 vaccine in her left upper extremity 13 days prior. The patient was advised to return for short-term follow-up targeted ultrasound of the left axilla to ensure resolution.

## 2.4. Case 4

57-year-old female, with no personal or family history of breast cancer, presented for routine screening mammography and screening breast ultrasound. Per electronic medical record, she received the first dose of the Pfizer-BioNTech COVID-19 vaccine in her left upper extremity 8 days prior.

Bilateral screening mammogram was unremarkable. On screening ultrasound, a single prominent left axillary lymph node was noted measuring 1.0 cm in short axis with diffuse cortical thickening (Fig. 4a,

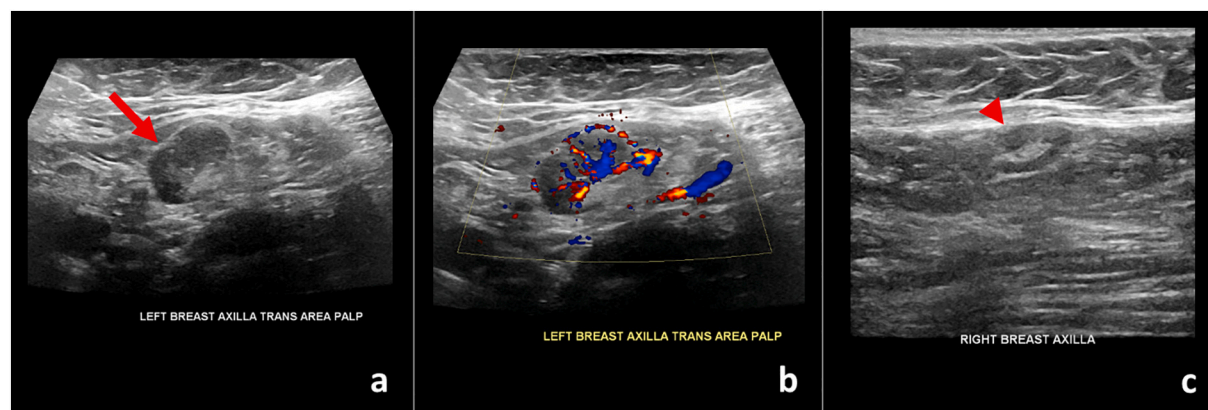
b). The remainder of the left breast was unremarkable. No abnormal lymph nodes were present in the right axilla (Fig. 4c). The patient was advised to return for short-term follow-up targeted ultrasound of the left axilla to ensure resolution.

## 3. Discussion

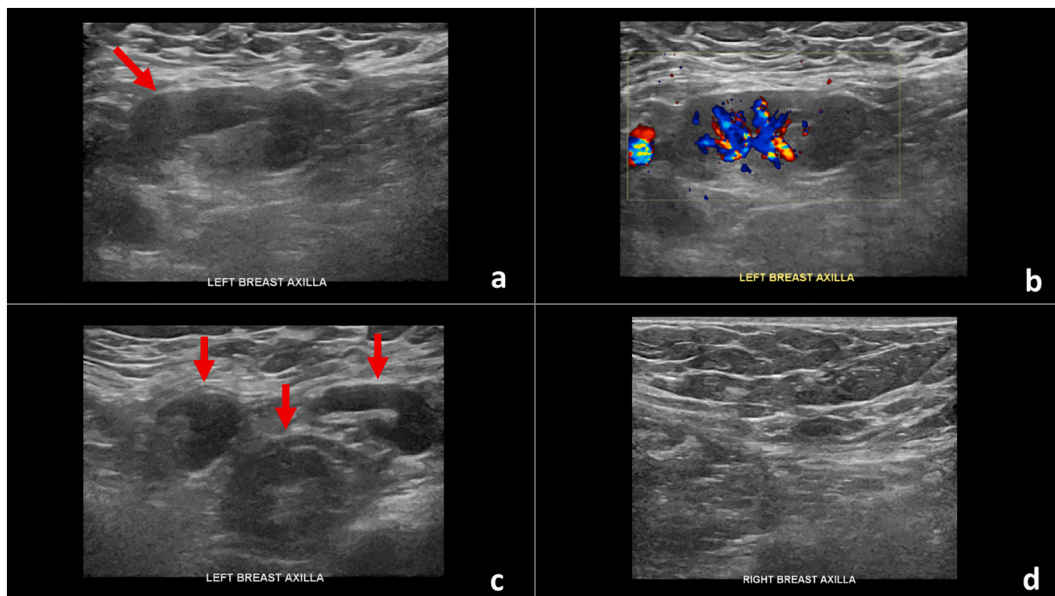
The differential diagnosis for unilateral axillary adenopathy is broad with breast cancer at the top of the differential.<sup>1–3</sup> In evaluating patients presenting with a unilateral palpable axillary mass or incidental unilateral axillary adenopathy identified on routine breast imaging, it is imperative that the ipsilateral breast be thoroughly examined for possible primary malignancy. While malignancy remains the most serious differential for unilateral axillary adenopathy, other benign etiologies should be considered. In addition to the breast, the thoracic wall and ipsilateral arm have direct lymphatic drainage to the axilla, and therefore local infection, inflammation, or trauma to these areas may result in unilateral axillary adenopathy.<sup>2</sup>

Adenopathy related to recent vaccination status is not an uncommon benign etiology resulting in unilateral axillary adenopathy and has been well-documented following smallpox, Bacille Calmette-Guerin (BCG), and anthrax vaccination.<sup>3</sup> In some cases, recent vaccination history was overlooked leading to the misdiagnosis of malignancy. For example, in 1968 Hartssock concluded that 9 of 20 cases of post-vaccine lymphadenitis, related to recent inoculation with the smallpox vaccine, were misdiagnosed as malignant lymphoma.<sup>8</sup> In 1990, Newfield et al. reported a case of initially misdiagnosed unilateral axillary lymph node enlargement in a 50-year-old woman who received the BCG vaccine two months earlier.<sup>4</sup> More recently, unilateral adenopathy has been reported in adults receiving the human papilloma virus (HPV) vaccine in the ipsilateral deltoid muscle.<sup>5</sup> Reactive unilateral axillary lymph nodes have also been demonstrated following vaccination in the ipsilateral upper extremity with the influenza vaccine, including the H1N1 influenza A virus vaccine, as evidenced by unilateral increased fluorodeoxyglucose (FDG) uptake on Positron Emission Tomography – Computed Tomography (PET/CT), which resolved on short-term follow-up PET/CT.<sup>6,9,10</sup>

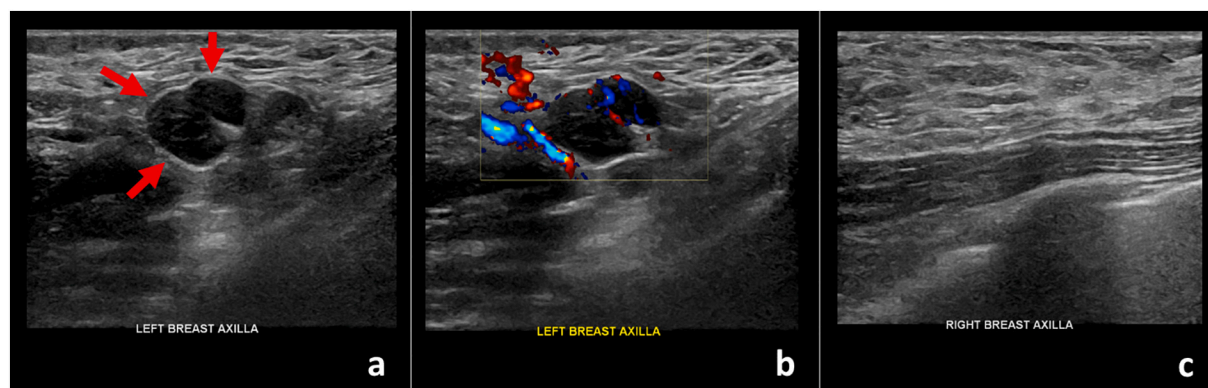
While hyperplastic axillary adenopathy can occur shortly after receiving any vaccination, it is more common after a vaccine that evokes a very strong immune response, including the most recently FDA-approved Pfizer-BioNTech and Moderna COVID-19 vaccines. Per the Centers for Disease Control and Prevention (CDC), amongst recipients of the Moderna COVID-19 vaccine, axillary adenopathy ipsilateral to the vaccination arm was the second most frequently reported local reaction, with 11.6% of recipients experiencing this after Dose 1 and 16.0% of recipients experiencing this after Dose 2 in the 18–64 year age group.<sup>11</sup>



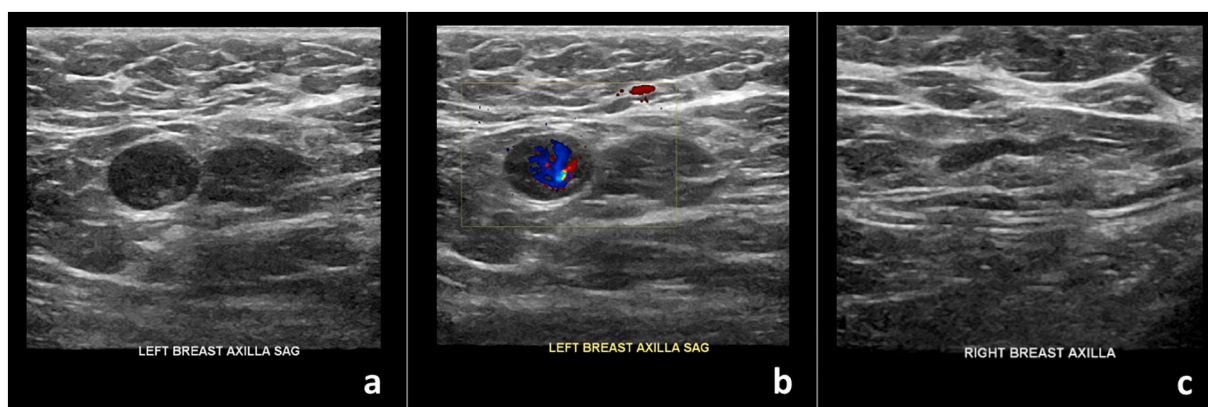
**Fig. 1.** 59-year-old female with palpable unilateral left axillary adenopathy noted approximately 9 days after receiving the first dose of the Pfizer-BioNTech Covid-19 vaccine in her left upper extremity. (a) Gray-scale and (b) color Doppler images of an enlarged left axillary lymph node measuring  $2.6 \times 1.5 \times 1.6$  cm with uniform cortical thickening up to 0.7 cm (arrow). Normal right axillary lymph node (arrowhead) was noted.



**Fig. 2.** 42-year-old female with unilateral left axillary adenopathy noted 5 days after receiving the second dose of the Pfizer-BioNTech COVID-19 vaccine in her left upper extremity. (a) Gray-scale and (b) color Doppler images of an enlarged left axillary lymph node with cortical thickening (arrow). (c) Multiple additional morphologically abnormal left axillary lymph nodes were also present (arrows). Unremarkable right axilla was documented (d).



**Fig. 3.** 42-year-old female with unilateral left axillary adenopathy noted 13 days after receiving the first dose of the Moderna COVID-19 vaccine in her left upper extremity. (a) Gray-scale and (b) color Doppler images of an enlarged left axillary lymph node with diffuse cortical thickening (arrows). Unremarkable right axilla was documented (c).



**Fig. 4.** 57-year-old female with unilateral left axillary adenopathy noted 8 days after receiving the first dose of the Pfizer-BioNTech Covid-19 vaccine in her left upper extremity. (a) Gray-scale and (b) color Doppler images of a single enlarged left axillary lymph node with diffuse cortical thickening. Unremarkable right axilla was documented (c).

In contrast, the CDC did not report data for axillary adenopathy occurring in recipients after receiving the Pfizer-BioNTech COVID-19 vaccine, but rather noted that reports of adenopathy were imbalanced between the vaccine group (64) and the placebo group (6), concluding that adenopathy was plausibly related to the vaccine.<sup>12</sup> Additionally, of those recipients who received the Pfizer-BioNTech COVID-19 vaccine, adenopathy was reported within 2–4 days after vaccination, similar to those recipients of the Moderna COVID-19 vaccine; however, the average duration of adenopathy was approximately 10 days, compared to an average duration of 1–2 days with the Moderna COVID-19 vaccine.<sup>11,12</sup>

In case 1, the patient reported first self-detecting unilateral axillary adenopathy 9 days after receiving the first dose of the Pfizer-BioNTech COVID-19 vaccine in the ipsilateral upper extremity, suggesting a later onset than what was reported by the CDC. Unilateral axillary adenopathy was incidentally noted in case 2 and case 4, therefore the exact onset of this reaction after receiving the COVID-19 vaccine remains unclear in these cases. In the cases presented, the time between receiving the Pfizer-BioNTech COVID-19 vaccination and detection of unilateral axillary adenopathy, either through self-detection or incidentally on breast imaging, was in keeping with the average duration of adenopathy reported by the CDC. However, the time between receiving the Moderna COVID-19 vaccination and detection of unilateral axillary adenopathy in case 3 was 13 days, much longer than the average duration of 1–2 days reported by the CDC in recipients of the Moderna Covid-19 vaccine. Therefore, in addition to obtaining vaccination history, it is important for radiologists to recognize that the finding of unilateral axillary adenopathy may occur up to a few weeks after receiving the COVID-19 vaccine.

With the recent FDA-approval and rollout of the Pfizer-BioNTech and Moderna COVID-19 vaccines, it is imperative for radiologists to recognize recent ipsilateral COVID-19 vaccination history as a potential differential diagnosis for unilateral axillary adenopathy. Patients may either present for diagnostic imaging for palpable unilateral axillary adenopathy or it may be discovered incidentally during routine breast imaging. Recognizing this as a potential differential diagnosis is crucial to being able to provide appropriate follow-up recommendations. This

would in turn decrease the number of false-positive axillary lymph node biopsy recommendations, thus minimizing patient harm and cost. At our institution, upon confirming recent ipsilateral COVID-19 vaccination status in patients with isolated unilateral axillary adenopathy, we recommend repeat targeted ultrasound of the affected axilla 4–12 weeks after the patient's scheduled second vaccination dose to ensure resolution. If the abnormal adenopathy persists on follow-up imaging, ultrasound-guided core needle biopsy may be recommended at that time to exclude underlying malignancy.

## References

- [1] Dialani V, James DF, Slanetz PJ. A practical approach to imaging the axilla. *Insights Imaging* 2015;6(2):217–29.
- [2] Peters G, Jones CM. Unilateral axillary adenopathy with unremarkable breast imaging-differential diagnoses. *SAJR* 2012;16:104–6.
- [3] Cohen J, Powderly WG, Opal SM. Infectious diseases. Elsevier Health Sciences 2017;2(4):145.
- [4] Newfield L, Naschitz JE, Yeshurun D. BCG-induced axillary lymphadenitis in the adult. *Harefuah*. 1990;119(7–8):199–200.
- [5] Studdiford J, Lamb K, Horvath K, Altshuler M, Stonehouse A. Development of unilateral cervical and supraclavicular lymphadenopathy after human papilloma virus vaccination. *Pharmacotherapy* 2008;28(9):1194–7. Sep.
- [6] Shirone N, Shinkai T, Yamane T, et al. Axillary lymph node accumulation on FDG-PET/CT after influenza vaccination. *Ann Nucl Med* 2012;26(3):248–52.
- [7] Centers for Disease Control and Prevention. Vaccine recommendations and guidelines of the ACIP. <https://www.cdc.gov/vaccines/hcp/acip-recs/vacc-spec/ific/covid-19/evidence-table-phase-1b-1c.html>. [Accessed 17 January 2021].
- [8] Hartsock RJ. Postvaccinial lymphadenitis. Hyperplasia of lymphoid tissue that simulates malignant lymphomas. *Cancer* 1968;21(4):632–49.
- [9] Burger IA, Husmann L, Hany TF, et al. Incidence and intensity of F-18 FDG uptake after vaccination with H1N1 vaccine. *Clin Nucl Med* 2011;36(10):848–53.
- [10] Thomassen A, Lerberg Nielsen A, Gerke O, et al. Duration of 18F-FDG avidity in lymph nodes after pandemic H1N1v and seasonal influenza vaccination. *Eur J Nucl Med Mol Imaging* 2011;38(5):894–8.
- [11] Local reactions, systemic reactions, adverse events, and serious adverse events: Moderna COVID-19 vaccine. Centers for Disease Control and Prevention, Centers for Disease Control and Prevention; 20 Dec. 2020. [www.cdc.gov/vaccines/covid-19/info-by-product/moderna/reactogenicity.html](http://www.cdc.gov/vaccines/covid-19/info-by-product/moderna/reactogenicity.html).
- [12] Local reactions, systemic reactions, adverse events, and serious adverse events: Pfizer-BioNTech COVID-19 vaccine. Centers for Disease Control and Prevention, Centers for Disease Control and Prevention; 13 Dec. 2020. [www.cdc.gov/vaccines/covid-19/info-by-product/pfizer/reactogenicity.html](http://www.cdc.gov/vaccines/covid-19/info-by-product/pfizer/reactogenicity.html).